

Endodontic Microsurgical Treatment of a Three-rooted Mandibular First Molar with Separate Distolingual Root: Report of One Case

Han Guo WANG¹, Ning XU¹, Qing YU¹

The separate distolingual (DL) roots of three-rooted mandibular first molars are thought to be too difficult for performing apical surgery. This article represents microsurgical treatment of a three-rooted mandibular first molar with a separate DL root. The procedure includes incision and flap retraction, osteotomy, apicoectomy, retropreparation and retrofilling of the root canal, using micro instruments, ultrasonic retrotips and mineral trioxide aggregate (MTA) under a dental operating microscope. Two mm in length of apical root resection, 2 mm in depth of root canal retropreparation with a personalised ultrasonic retrotip, and 2 mm in length of retrofilling with MTA are the key points for accomplishment of apical surgery on separate DL roots. The case was followed up for 15 months after surgery. Clinical and radiographic examinations revealed complete healing of periapical tissue. Separate DL roots of three-rooted mandibular first molars can be treated by endodontic microsurgery with modifications from standard protocol.

Key words: distolingual root, endodontic microsurgery, mandibular first molar

Chin J Dent Res 2016;19(3):171–174; doi: 10.3290/j.cjdr.a36683

A thorough knowledge of the root and root canal morphology is a prerequisite for endodontic nonsurgical and surgical treatment. Extra distolingual (DL) roots in mandibular first molars (termed radix entomolaris, RE) are considered a normal morphologic variant in Mongoloid traits with a high incidence of 5% to 40%, including Chinese, Korean, Eskimo and Native American Indians¹⁻⁴. Several *in vivo* and *in vitro* studies have revealed that separate DL roots of mandibular first molars are

always severely curved; small; shorter than distobuccal (DB) roots; and the surgical access is blocked by thick buccal bone and DB roots^{1,5-9}. These morphological characteristics of DL roots determine that hemisection, intentional replantation or extraction is usually chosen instead of apical surgery when surgical treatment on DL roots is necessary. However, hemisection destroys the integrity of tooth structure and intentional replantation is easy to break the DL roots during the extraction procedure. Apical surgery *in situ* is thought to be the best choice if feasible. Until now, there is no report of apical surgery on DL roots of mandibular first molars in the literature.

In this case report, a mandibular first molar with three roots including a separate DL root with four root canals was treated successfully by endodontic microsurgery.

Case report

A 30-year-old male Chinese patient complained of continuous dull pain of the right mandibular first molar. His dental history indicated that the tooth had been treated

¹ State Key Laboratory of Military Stomatology, Department of Operative Dentistry & Endodontics, School of Stomatology, The Fourth Military Medical University, Xi'an 710032, Shaanxi Province, P.R. China.

Corresponding author: Dr Han Guo WANG, State Key Laboratory of Military Stomatology, Department of Operative Dentistry & Endodontics, School of Stomatology, The Fourth Military Medical University, No. 145 Chang-le West Road, Xi'an 710032, Shaanxi Province, P.R. China. Tel: 86-29-84776476; Fax: 86-29-84776476. Email: wanghg@fmmu.edu.cn; wanghanguo2000@hotmail.com

The work was supported by a grant from the National Nature Science Foundation of China (Grant No. 81271126 to Hanguo WANG).

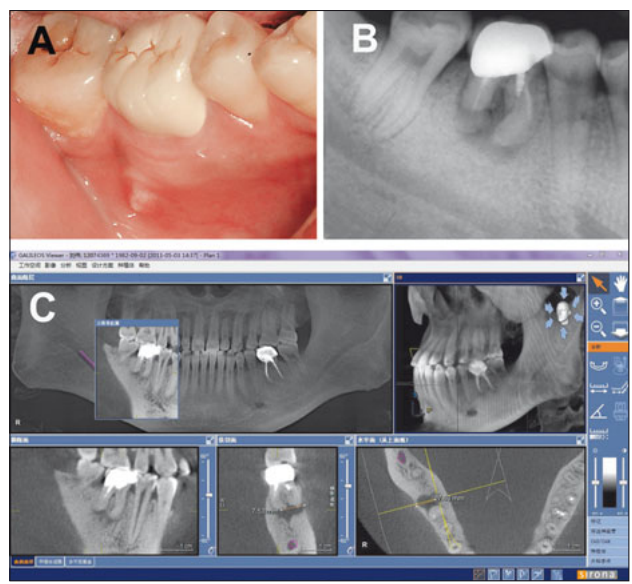
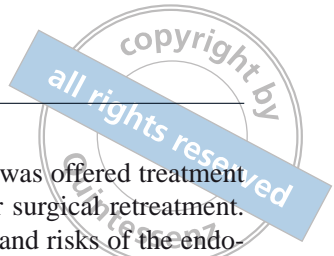

Fig 1 (A) Clinical image of tooth 46. (B) Preoperative periapical radiograph. (C) CBCT images revealed the morphological characteristics of the DL root.

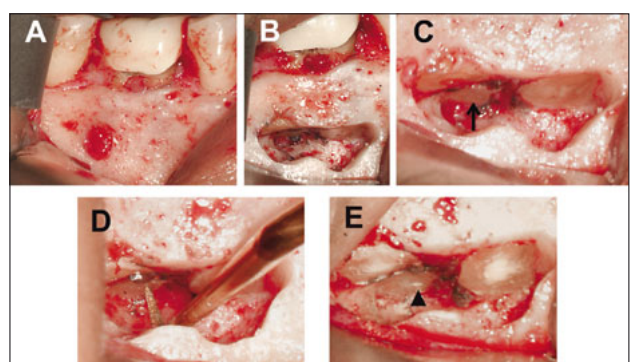


Fig 2 (A) Flap retraction. (B) Osteotomy and apicoectomy of mesial and distobuccal roots. (C) Apicoectomy of the DL root. (D) Retropreparation of the DL root. (E) Retrofilling with MTA. (Arrow: DL root; arrowhead: retrofilling of DL root canal)

with nonsurgical root canal treatment and was restored with a metal-ceramic full crown 3 years before. Clinical examinations revealed moderate percussion pain, and tenderness on palpation, with a fistula on the buccal side of tooth 46 (Fig 1A). There was either no periodontal pocket or mobility. Periapical radiograph and cone beam computed tomography (CBCT) showed the tooth was three-rooted with a separate DL root, and there was underfilling of root canal obturation with periapical radiolucency (Figs 1B and 1C). A diagnosis of previous root canal treatment with symptomatic apical periodon-

titis was established. The patient was offered treatment options including non-surgical or surgical retreatment. The procedure, possible benefits and risks of the endodontic microsurgery were explained in detail to the patients, and written consent was obtained.

In order to perform the apical surgery on separate DL roots, the CBCT data was analysed and the morphological characteristics of the DL root were obtained as follows: the length of the DL root (from the lowest level of furcation at the distal surface to the root apex) was 5.61 mm while the DB (distobuccal) root was 6.65 mm, the distance from the DL root apex to the buccal cortical bone was 8.03 mm, the curvature which was located at the middle third had a 33.4° angle in the buccal-lingual direction whilst it was almost straight in the mesial-distal direction by Schneider's technique, and the angle between the DL root and the line perpendicular to the buccal cortical bone was about 105° (Fig 1C).

The surgical treatment protocol was applied according to the literature with some modifications^{10,11}. With the exception of incisions, flap elevation and suturing, all surgical procedures were performed by using a dental operating microscope (Carl Zeiss OPMI ProErgo; Carl Zeiss, Oberkochen, Germany).

Briefly, after inferior alveolar nerve block anaesthesia combined with local infiltration anaesthesia, the teeth underwent the procedure of raising and retracting the full thickness flap (Fig 2A). Osteotomy and apicoectomy (3 mm in length with about a 10° bevel angle) of mesial and distobuccal roots were performed with an H161 Lindemann bone cutter (Brasseler, Georgia, USA) in an Impact Air 45 handpiece (Palisades Dental, New Jersey, USA) (Fig 2B). After the periradicular curettage and hemostasis, the DL root apex was seen. Then a 2 mm root tip with 10° bevel angle was resected on DL root (Fig 2C). The resected root surfaces were stained with methylene blue and inspected with micromirrors under high magnification. Underfilling and the isthmus in the mesial root canals and the emptying of the DL root canal were found to be the causes of previously failed treatment. Root-end preparations extending 3 mm into the canal space along the long axis of the roots, including mesiobuccal, mesiolingual, isthmus and distobuccal canals, were made with Jetip ultrasonic tips (B&L, Pennsylvania, USA) driven by a piezoelectric ultrasonic unit (P5, Satalec, Merignac, France). According to the curvature of the DL root, the bendable Jetip retreatip was bent to 105° angle with 2 mm working length by a bending zig, and applied for retropreparation of 2 mm in depth of the DL root canal (Fig 2D). The prepared root end cavities of all the canals were dried with a Stropko irrigator/drier and ret-

rofilled with ProRoot MTA (Dentsply, Oklahoma, USA) (Fig 2E). The wound site was closed and sutured with 5-0 monofilament sutures, and a postoperative radiograph was taken (Fig 3A). The patient was instructed regarding the postoperative care.

The patient returned 5 days later for suture removal, with no sinus tract and clinical symptoms. Healing of the surgery was uneventful (Figs 3B and 3C). At the 9- and 15-month follow-ups, clinical examination and the radiograph showed complete healing (Figs 3D to 3F).

Discussion

De Moor et al³ first classified the DL roots into three types according to their curvature as follows: type I: no curvature; type II: curvature in the coronal third and straight continuation to the apex; type III: curvature in the coronal third and additional buccal curvature from the middle third to the apical third of the root. Recently, Chen et al⁶ found that 28.6% of the DL roots were curved at the apical one third, which could be categorised as type III. In another study, not only buccolingual (BL) curvatures but also moderate to severe mesiodistal (MD) curvatures may occur in the apical two-thirds of the DL roots, which also belong to type III¹². In this case, the curvature of the DL root located at the middle third, and the angle of curvature was quantified as 33.4° in the BL direction, which was categorised as severe curvature, while it was almost straight in the MD direction. This case belongs to type III without doubt. Generally speaking, the root apex of type III DL root is closer to buccal cortical bone than that of type I and II in the BL direction. An *in vivo* study showed that the mean distance from the DL canal of separate DL roots to buccal cortical bone was 8.63 mm in a Korean population⁹. Based on the analysis of the CBCT, the distances from the DL root apex to the cortical bone was about 8 mm in this case, shorter than average, which means the surgical access may be more feasible.

Endodontic surgery has now evolved into endodontic microsurgery. By using state-of-the-art equipment, instruments and biocompatible materials, the microsurgical approaches produce predictable outcomes in the healing of lesions of endodontic origin¹⁰. Compared with the standard protocol of apical microsurgery, we developed some modifications, especially for separate DL roots i.e. 2 mm in length of root resection, 2 mm in depth of retropreparation and retrofilling. Firstly, *in vitro* and *in vivo* studies revealed that 100% of the DL root canals were categorised as type I according to Vertucci's criteria, and accessory and lateral canals rarely occurred^{2,13}. Cleaning, preparation and filling the

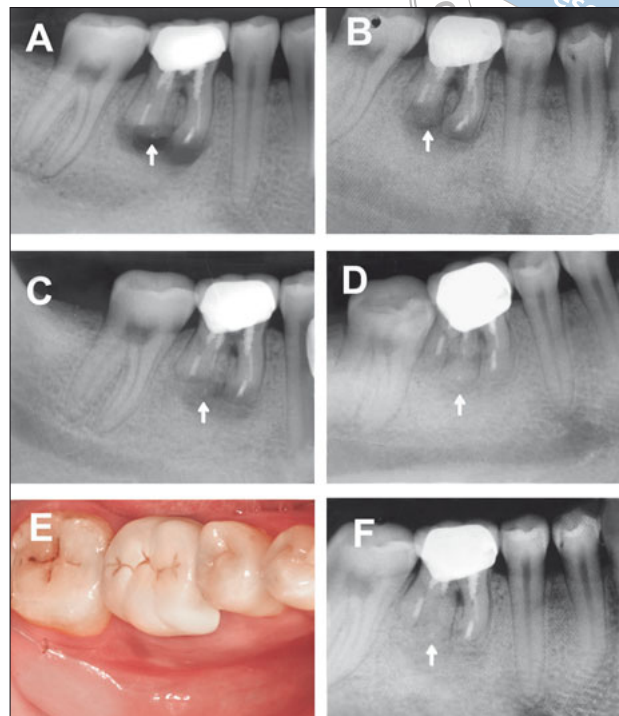


Fig 3 (A) Postoperative radiograph. (B) Periapical radiograph 3 months postoperatively. (C) Periapical radiograph 6 months postoperatively. (D) Periapical radiograph 9 months postoperatively. (E) Clinical image 15 months postoperatively. (F) Periapical radiograph 15 months postoperatively. (Arrow: DL root)

main canal are sufficient for the apical seal. Secondly, DL roots are always shorter than DB roots^{6,7}. In this case, the length of the DL root from the lowest level of furcation at the distal surface to the root apex was 5.61 mm while the DB root was 6.65 mm. If 3.0 mm of the DL root was resected, only 2.6 mm in length of the DL and DB root would be left, which means 4.0 mm of DB root will be resected. Therefore the DL root had to be resected by less than 3 mm in order to keep more DB root. Thirdly, most of the DL roots have moderate to severe curvatures in the BL direction, some are even curved in the MD direction. Three millimetres in depth of retropreparation may cause root canal deviation, ledge formation and even perforation. Two millimetres in depth of retropreparation decreases these risks significantly.

The selection of ultrasonic retrotips is another important issue, such as diameter, working length and the angulations. The DL roots have round-shaped canals and 0.03 taper for the apical and middle portions. The dentin wall thickness and diameter of canals at 2 mm from the apical foramen were almost the same as that at 3 mm from the apical foramen, which was about



1.0 mm and 0.3 mm, respectively^{1,14}. Therefore, the retropreparation with fine tips designed for the isthmus preparation is feasible without the risk of root perforation and fracture. In addition, each DL root canal has its own curvature in the BL and MD planes. In this case, the angle between the DL root and the line perpendicular to the buccal cortical bone was about 105°, which means the commonly used ultrasonic tips with 90° angulations are no longer suitable. Bendable JETips are the optimal choice because they can be bent for personalised angulation in each case.

Conflicts of interest

The authors reported no conflicts of interest related to this study.

Author contribution

Dr Hanguo Wang for the overall design of the case, for completing the surgical procedures and preparing the paper; Dr Ning Xu for collecting the data and recording the follow-ups; and Prof Qing Yu for the instructions of the surgical procedures.

(Received March 03, 2016; accepted May 05, 2016)

References

1. Abella F, Patel S, Durán-Sindreu F, Mercadé M, Roig M. Mandibular first molars with disto-lingual roots: review and clinical management. *Int Endod J* 2012;45:963–978.
2. Wang Y, Zheng QH, Zhou XD, et al. Evaluation of the root and canal morphology of mandibular first permanent molars in a western Chinese population by cone-beam computed tomography. *J Endod* 2010;36:1786–1789.
3. De Moor RJ, Deroose CA, Calberson FL. The radix entomolaris in mandibular first molars: an endodontic challenge. *Int Endod J* 2004;37:789–799.
4. Tu MG, Huang HL, Hsue SS, et al. Detection of permanent three-rooted mandibular first molars by cone-beam computed tomography imaging in Taiwanese individuals. *J Endod* 2009;35:503–507.
5. Chen G, Yao H, Tong C. Investigation of the root canal configuration of mandibular first molars in a Taiwan Chinese population. *Int Endod J* 2009;42:1044–1049.
6. Chen YC, Lee YY, Pai SF, Yang SF. The morphologic characteristics of the distolingual roots of mandibular first molars in a Taiwanese population. *J Endod* 2009;35:643–645.
7. Gu Y, Lu Q, Wang P, Ni L. Root canal morphology of permanent three-rooted mandibular first molars: Part II--measurement of root canal curvatures. *J Endod* 2010;36:1341–1346.
8. Jin GC, Kim KD, Roh BD, Lee CY, Lee SJ. Buccal bone plate thickness of the Asian people. *J Endod* 2005;31:430–434.
9. Kim SY, Yang SE. Cone-beam computed tomography study of incidence of distolingual root and distance from distolingual canal to buccal cortical bone of mandibular first molars in a Korean population. *J Endod* 2012;38:301–304.
10. Kim S, Kratchman S. Modern endodontic surgery concepts and practice: a review. *J Endod* 2006;32:601–623.
11. Floratos SG, Kratchman SI. Surgical management of vertical root fractures for posterior teeth: report of four cases. *J Endod* 2012;38:550–555.
12. Song JS, Choi HJ, Jung IY, Jung HS, Kim SO. The prevalence and morphologic classification of distolingual roots in the mandibular molars in a Korean population. *J Endod* 2010;36:653–657.
13. Gu Y, Lu Q, Wang H, Ding Y, Wang P, Ni L. Root canal morphology of permanent three-rooted mandibular first molars--part I: pulp floor and root canal system. *J Endod* 2010;36:990–994.
14. Gu Y, Zhou P, Ding Y, Wang P, Ni L. Root canal morphology of permanent three-rooted mandibular first molars: Part III--An odontometric analysis. *J Endod* 2011;37:485–490.