

Simple Myofunctional Therapy Using Ready-made Mouthpiece Device before and after Orthodontic Treatment

Aoi FUKUMOTO¹, Takero OTSUKA¹, Toshitsugu KAWATA¹

The present report describes myofunctional therapy using a ready-made training device, the T4A, in patients with permanent dentition and its effect on the prevention of relapse. The buccinator mechanism maintains the inner pressure of the tongue muscle equivalent to the outer pressure of the perioral soft tissues, such as the orbicular muscles, including the cephalopharyngeus and buccinator muscles. Training is performed so that patients learn to place their tongue and lips in the appropriate resting positions. The shape of the T4A and tongue guard supports the tongue from the bottom, allowing formation of the correct resting tongue position. However, the use of T4A for a long period of time may cause the teeth movement; therefore, caution is required. Use of the T4A is effective for the correction of oral habits, myofunctional therapy and for teaching the correct resting tongue position during the daytime and for the correction of oral habits, teaching correct resting tongue position during sleep.

Key words: myofunctional therapy, orthodontic treatment, ready-made mouthpiece
Chin J Dent Res 2016;19(3):165–169; doi: 10.3290/j.cjdr.a36682

It is widely known that patients with oral habits, such as abnormal swallowing and tongue habits, often develop characteristic malocclusion. When these habits remain after the completion of orthodontic treatment, the risk of relapse after orthodontic treatment and the development of new malocclusion increases. Therefore, a training device for the correction of oral habits may be useful for myofunctional therapy (MFT), depending on the particular oral habit of the patient. The present report describes myofunctional therapy using a ready-made training device, the T4A (TRAINER, ORTHIKA International, Tokyo, Japan), in patients with permanent dentition, and its effect on the prevention of relapse.

It is widely known that patients with oral habits often develop characteristic malocclusion. If oral habits remain after the completion of orthodontic treatment, the risk of relapse or development of later malocclusion increases. Therefore, appropriate retention is necessary

to acquire long-term stable occlusion after orthodontic treatment¹.

Retention is the maintenance of the correct position and condition of the teeth and jawbone, which had been repositioned by active treatment, over a long period of time. It has been reported that retention of repositioned teeth is more difficult than the actual process of moving the teeth, and retention is extremely important for the prevention of relapse.

There are three types of retention: 1) natural retention; 2) mechanical retention; and 3) permanent retention². Although the risk of relapse is low with the use of mechanical or permanent retention, these options are not preferred by patients. However, it is difficult to stabilise the dentition by natural retention, and the following conditions are necessary for achieving dentition stabilisation by this method:

- Normal contribution of mechanical force from the perioral muscles, such as the masticatory, facial and tongue muscles, which help stabilise the acquired occlusion.
- Proper occlusion, including anterior overbite, intercuspal position and proximal contact.
- Support from tooth-associated tissues, including the jawbone.

¹ Orthodontic division, Department of Oral Science, Kanagawa Dental University Graduate School, Yokosuka, Japan.

Corresponding author: Dr Takero OTSUKA, Orthodontic division, Department of Oral Science, Kanagawa Dental University Graduate School, 82 Inaoka-cho, Yokosuka 2388580, Japan. Tel: 81-46-822-8858; Fax: 81-46-8228858. Email: otsuka@kdu.ac.jp



It is important to position the tongue and lips to allow proper nasal breathing and swallowing habits, so that the perioral muscles can exert a normal functional force. The present study provides the details of an easy method of myofunctional therapy (MFT) utilising a ready-made T4A.

Materials and methods

The buccinator mechanism maintains the inner pressure of the tongue muscle equivalent to the outer pressure of the perioral soft tissues, such as the orbicular muscles, including the cephalopharyngeus and buccinator muscles. Training is performed so that patients learn to place their tongue and lips in the appropriate resting positions.

The training sequence was as follows:

- The lips are closed in a relaxed position, with the teeth in contact and the tongue is forced against the palate by negative pressure. The tongue should be relaxed.
- The upper and lower molars are separated by 2 to 3 mm, and the tongue is forced against the palate by negative pressure, with the lips closed.
- The upper and lower molars are separated by 2 to 3 mm, and the tongue is forced against the palate by negative pressure, with the lips slightly open.
- The upper and lower molars are separated by 2 to 3 mm, and the mouth is slowly closed. The tongue is forced against the palate by negative pressure.

If the tongue is separated from the palate at any time during steps 1 to 4, return to the first step.

In the resting position of the tongue, the tip of the tongue is placed posterior to the upper anterior teeth, and the back of the tongue should touch the inside of the upper palate. It is important to be aware that the tongue is forced into the palate by the negative pressure generated by the tongue. After tongue position training, correct swallowing, pronunciation (particularly the “Sa” group of Japanese phonemes) and nasal breathing are taught. The T4A is used while training, and includes functional orthodontic devices such as a lip bumper and tongue crib. The lip bumper and labial bow of the T4A repositions the perioral muscles. As the T4A also includes a resting position for the tongue, patients can easily learn the correct resting tongue position, facilitating myofunctional treatment. The T4A is inserted into the mouth 1 h before going to bed, and is kept during sleep. Patients without a congested nose and who have habitual mouth breathing may use the T4A during the day, as long as they breathe through their nose with their lips closed.

Oral habits and malocclusion factors

Oral habits may cause the following malocclusions:

Tongue habits

- **Low tongue:** The tongue is placed on the lower dentition inside the lower arch. Mouth breathing may cause an open bite. The dental arch is wider in the mandible compared with the maxilla.
- **Child-type swallowing:** The tongue is forced against the palate and the lower lip is moved lingually. Labial inclination of the upper and lower anterior teeth and open bite of the anterior teeth are observed.
- **Tongue protrusion:** The tongue is pressed against the anterior teeth. The tongue protrudes between the upper and lower anterior teeth. Labial inclination of the upper and lower anterior teeth and open bite of the anterior teeth are observed.
- **Tongue biting:** A habit of biting the tongue. Open bites and deep bites are observed.

Lip habits

- **Lip biting and lip sucking habit:** A habit of biting and sucking the lower lip. Labial inclination and the gap of the upper anterior teeth, and lingual inclination and crowding of the lower anterior teeth are observed.
- **Mouth-breathing:** Normal nasal breathing is avoided due to the adenoid, resulting in mouth breathing. Incompetent lip, narrow upper dental arch, labial inclination of the upper anterior teeth, and increase in the anterior facial height and mandibular plane angle are observed, which are characteristics of adenoid face. Mouth-breathing is also caused by thickened oral tonsils and deviation of the nasal septum.
- **Nasopharyngeal disease:** Mouth breathing is present due to airway obstruction. Nasopharyngeal disease may cause labial inclination of the upper anterior teeth and a narrow upper dental arch.

Myofunctional therapy of the tongue (Fig 1)

The following procedures are performed to maintain proper perioral muscle function.

- Patients are taught the correct tongue position (rest position).
- Patients are taught how to use negative pressure to keep the back of the tongue in contact with the inner palate.
- Patients are taught how to swallow and are taught the proper use of the tongue during swallowing.
- Patients are taught proper pronunciation (particularly the “Ta” and “Sa” groups of Japanese phonemes).

Training for acquiring correct tongue rest position (Fig 2)

Subjects were required to practice how to move the teeth, lips and tongue for acquiring correct tongue rest position.

Simultaneous use of an adjunctive device (T4A) (Fig 3)

Simultaneous use of T4A during MFT allows patients to understand the correct position of the tip of the tongue more easily.

The T4A TRAINER utilised in the present study was designed for use in myofunctional training, normalisation of jaw position, assistance in learning correct resting tongue positions (such as placement of the tongue and reduction of orbicular muscle pressure), and an improvement in mouth breathing.

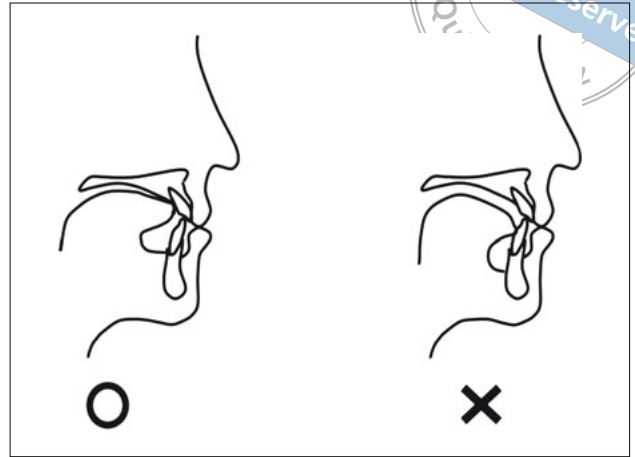


Fig 1 O: The tip of the tongue is located at the posterior part of the upper incisive papilla (spot) and the back of the tongue is in contact with the palate. X: The tongue is thrusting and the position is low.

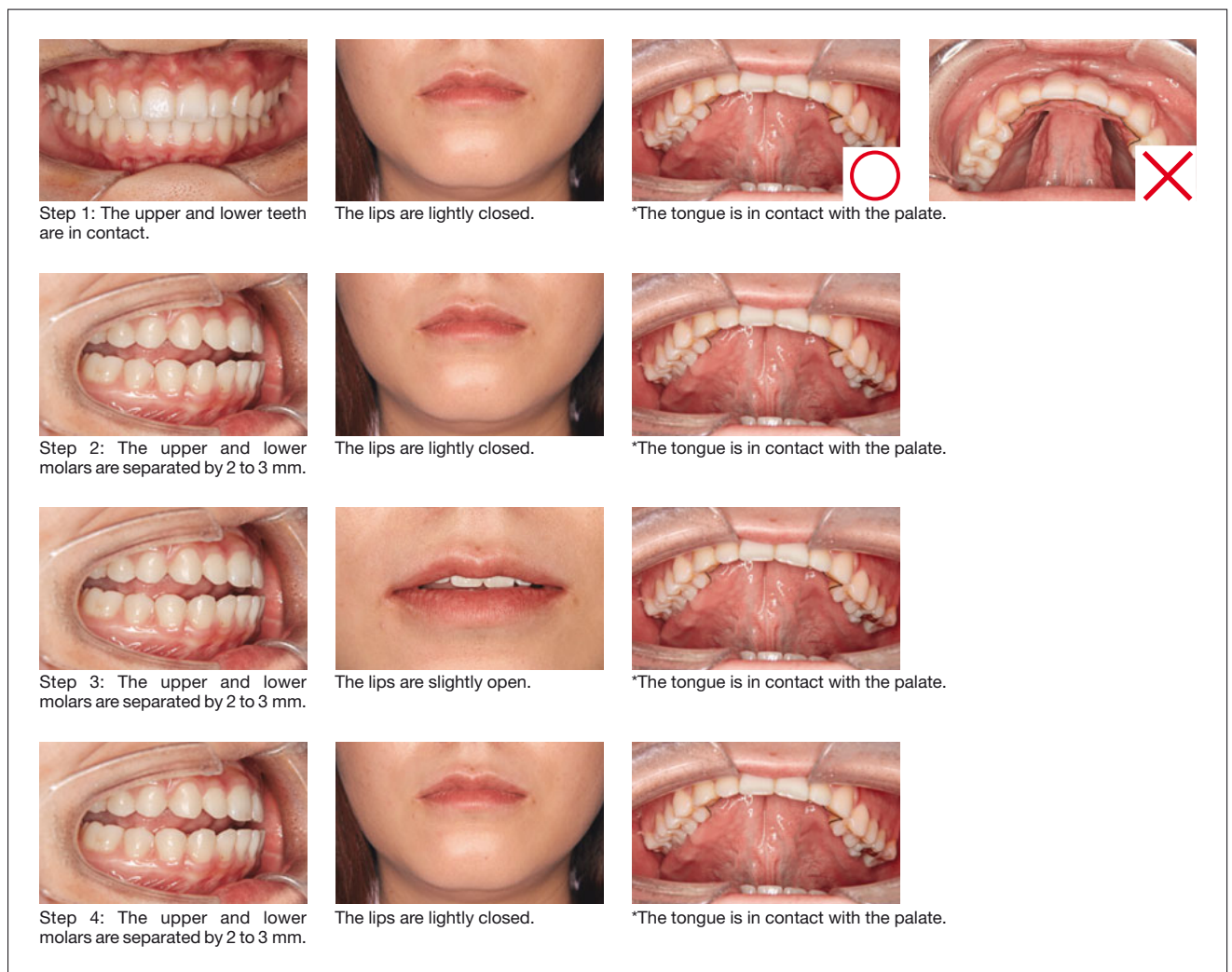


Fig 2 Training for correct resting tongue position. *Patients return to step 1 if the tongue is separated from the palate.




Fig 3 Structure of the T4A. 1) Tongue tag: for active tongue training; 2) Tongue guard: prevents tongue-thrusting; 3) Lip bumper: reduces activation of the mentalis muscle; 4) Wing-like base: relaxes the temporomandibular joint.

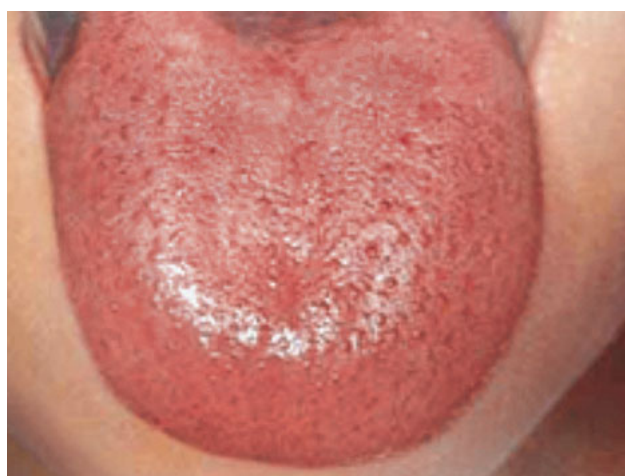

Fig 4 Just before the wearing of the T4A.

The study showed the state of the tongue before adding T4A to a patient (Fig 4). The structure of the T4A facilitates improvement of various oral habits (Fig 5). Cheek muscle pressure is reduced by closing the lips for 1 h with the T4A in the mouth, and natural nasal breathing is promoted by using the T4A during sleep (Fig 6). For patients using an edgewise appliance, oral habit training can be performed in combination with the T4B.

Discussion

Identification of oral habits at the early stage and subsequent training after the mixed dentition period is important^{3,4}. However, there are many patients with permanent dentition who also have oral habits. Myofunctional training during the permanent dentition period allows shortening of the orthodontic treatment period, by correcting tongue position, avoiding malocclusion relapse and balancing the influence of the perioral muscles, which provide a natural retentive force⁵. However, even when the correct tongue position is taught orally, it is difficult to maintain correct resting tongue position during sleep when compared with the daytime (Fig 1)⁶. From the perspective of oral seal theory, it is challenging for patients to completely acquire correct resting tongue position during the daytime by myofunctional training. It is also difficult for operators to confirm improvements in patients' resting tongue positions (Fig 2)⁷. The device for conventional oral habits displayed the position of the tip of the tongue. Thus, it is even more challenging to correctly position the tongue against the palate during sleep. Therefore, the use of an adjunctive device is useful in guiding the tongue to the correct resting position during sleep. In the past, a resin knob was attached to the tongue tip position of the Begg or Hawley type retainers, which were used after completion of orthodontic treatment, so that the patients could identify the correct resting tongue position. However, tongue thrusting, lat-

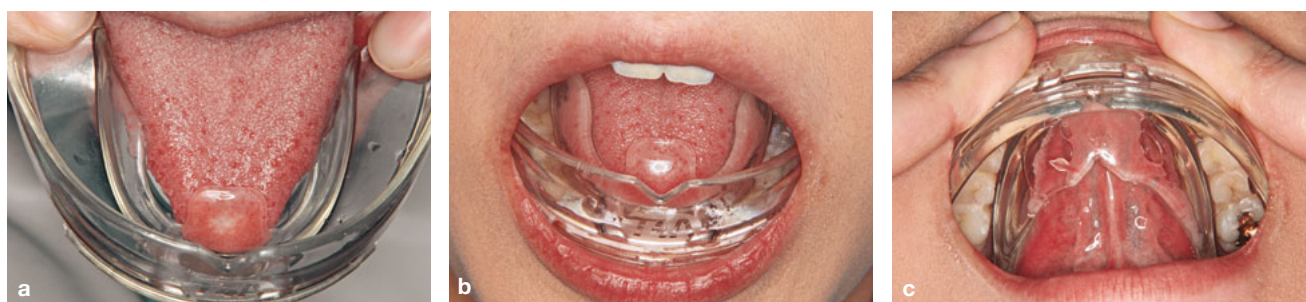

Fig 5 Resting tongue position while using the T4A.

eral pressure of the tongue and tongue bite habits were unable to be corrected utilising this approach. Compared with the T4A, it is more challenging to teach patients the correct resting tongue position using a tongue crib and lip bumper (Fig 3).

In contrast, the T4A are ready-made and therefore do not require any laboratory procedures. They can also be easily adjusted by cutting strong contact positions (Figs 4 and 5). The clinicians are only required to confirm that the tongue is in the correct position (Fig 6). With this approach, patients may find it easier to correct oral habits because they can consciously move their tongue to the correct resting tongue position, even when the T4A is not worn. Furthermore, the shape of the T4A and tongue guard supports the tongue from the bottom, allowing formation of correct resting tongue position habits. However, the use of T4A for a long period of time may cause the teeth movement; therefore, caution is required (Fig 7).

Conclusion

Use of the T4A is effective in the correction of oral habits, myofunctional therapy and for teaching correct resting tongue position.

Daytime: correction of oral habits, myofunctional therapy and teaching correct resting tongue position.

During sleep: correction of oral habits and teaching correct resting tongue position.

Conflicts of interest

The authors reported no conflicts of interest related to this study.

Author contribution

Dr Aoi Fukumoto for carrying out the research; Dr Takero Otsuka for preparing the manuscript; and Dr Toshitugu Kawata for the direction of the research.

(Received March 30, 2016; accepted May 26, 2016)

References

1. Smithpeter J, Covell D Jr. Relapse of anterior open bites treated with orthodontic appliances with and without orofacial myofunctional therapy. *Am J Orthod Dentofacial Orthop* 2010;137:605–614.
2. Thüer U, Ingervall B. Effect of muscle exercise with an oral screen on lip function. *Eur J Orthod* 1990;12:198–208.
3. Ramirez-Yañez GO, Faria P. Early treatment of a Class II, division 2 malocclusion with the Trainer for Kids (T4K): a case report. *J Clin Pediatr Dent* 2008;32:325–329.

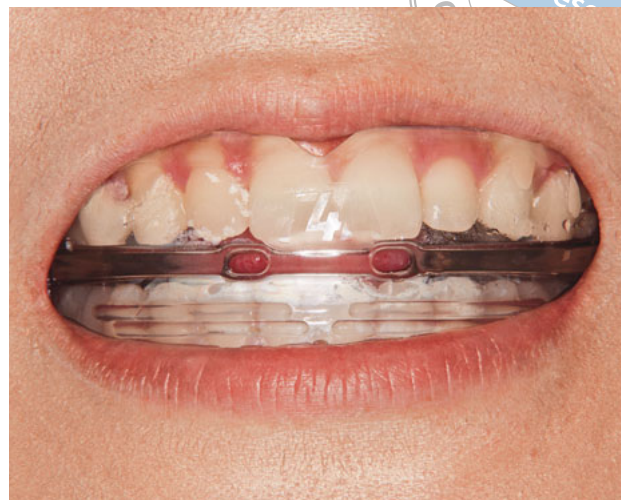

Fig 6 The illustration of the placement of the T4A.

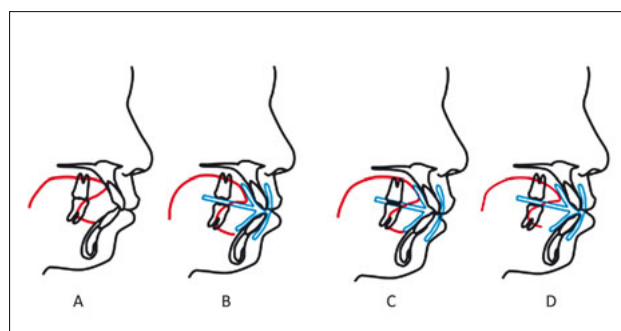


Fig 7 Patient swallows saliva during sleep many times. A) Before use of T4A appliance. B) Attached T4A appliance. The mandible is protruded by the T4A appliance. C) The patient drinks saliva during sleep many times. The mandible moves into a retruded position and the molar tooth occludes. D) The mandible returns to the position of B.

4. Ramirez-Yañez G, Sidlauskas A, Junior E, Flutter J. Dimensional changes in dental arches after treatment with a prefabricated functional appliance. *J Clin Pediatr Dent* 2007;31:279–283.
5. Smithpeter J, Covell D Jr. Relapse of anterior open bites treated with orthodontic appliances with and without orofacial myofunctional therapy. *Am J Orthod Dentofacial Orthop* 2010;137:605–614.
6. Lowe AA, Ozbek MM, Miyamoto K, Pae EK, Fleetham JA. Cephalometric and demographic characteristics of obstructive sleep apnea: an evaluation with partial least squares analysis. *Angle Orthod* 1997;67:143–153.
7. Melink S, Vagner MV, Hocevar-Boltezar I, Ovsenik M. Posterior crossbite in the deciduous dentition period, its relation with sucking habits, irregular orofacial functions, and otolaryngological findings. *Am J Orthod Dentofacial Orthop* 2010;138:32–40.