

Partial Pulpotomy of Immature Teeth with Apical Periodontitis using Bioceramics and Mineral Trioxide Aggregate: A Report of Three Cases

Shan JIANG^{1,2#}, Hao WU^{3#}, Cheng Fei ZHANG²

Pulpal necrosis of an immature permanent tooth with an open apex poses a challenge for the clinician. The conventional apexification technique using calcium hydroxide has yielded short-term success, but this technique has inevitable shortcomings. Hence, this case series aimed to evaluate the effectiveness of using bioceramics (iRoot BP) or mineral trioxide aggregate (MTA) for partial pulpotomies. Three boys aged 9 to 11 years old presented with partial pulp necrosis and symptomatic apical periodontitis of the mandibular right and left second premolar. The involved teeth were treated with a partial pulpotomy using either iRoot BP (case 1 and 2) or MTA (case 3). At the 8-month follow-up, no abnormal clinical signs or symptoms were observed. Periapical radiographs revealed a significant reduction in periapical radiolucency, a marked increase in the root canal wall thickness and ongoing closure of the apical opening. The bioceramic material (iRoot BP) and MTA both produced successful outcomes in the partial pulpotomy of immature teeth with partial pulp necrosis and apical periodontitis. However, iRoot BP was superior in terms of ease of clinical application, and would therefore be a better treatment alternative than MTA.

Key words: bioceramics, iRoot BP, mineral trioxide aggregate, partial pulpotomy
Chin J Dent Res 2016;19(2):115–120; doi: 10.3290/j.cjdr.a36182

Pulpal necrosis of immature teeth with open apices halts further root development, resulting in short and thin roots prone to fracture¹. Traditionally, apexification, using intracanal calcium hydroxide (Ca(OH)₂) medicament to induce apical closure over time, has been applied to treat pulpal necrosis of immature teeth². This

technique has been moderately successful in treating immature teeth with pulpal necrosis, but several obvious shortcomings still exist, including difficulty in controlling infection, the need of multiple visits, unpredictability of the apical closure, poor crown-root ratio, weakening of the dentin and cervical root fracture³.

To obviate the limited apexification achieved with Ca(OH)₂ paste, mineral trioxide aggregate (MTA), originally developed as a root end filling material, has been used in regenerative endodontic therapy to enhance root development in immature permanent teeth⁴. MTA is biocompatible, has better sealing ability and induces greater dentin bridge formation and apical closure of immature teeth when compared with Ca(OH)₂ paste⁵. However, MTA has its own limitations, including handling difficulties, long setting time, high cost and the presence of some toxic elements⁶.

Recently, bioceramics, which are biocompatible, non-cytotoxic, non-shrinking and chemically stable, have been introduced in medicine and dentistry⁷.

1 Department of Endodontics and Operative Dentistry, School and Hospital of Stomatology, Fujian Medical University, Fuzhou, Fujian Province, P.R. China.

2 Comprehensive Dental Care, Endodontics, Faculty of Dentistry, The University of Hong Kong, 34 Hospital Road, Sai Ying Pun, HKSAR, P.R. China.

3 Suzhou MicroDent Clinic, Suzhou, Jiangsu Province, P.R. China

These two authors contributed equally to this work.

Corresponding author: Dr Cheng Fei ZHANG, Comprehensive Dental Care, Endodontics, Faculty of Dentistry, The University of Hong Kong, 34 Hospital Road, Sai Ying Pun, HKSAR, P.R. China. Tel: 852-2859-0371; Fax: 852-2559-9013. Email: zhangcf@hku.hk

This study was supported by a grant from the National Nature Science Foundation of China (NO. 81470735).

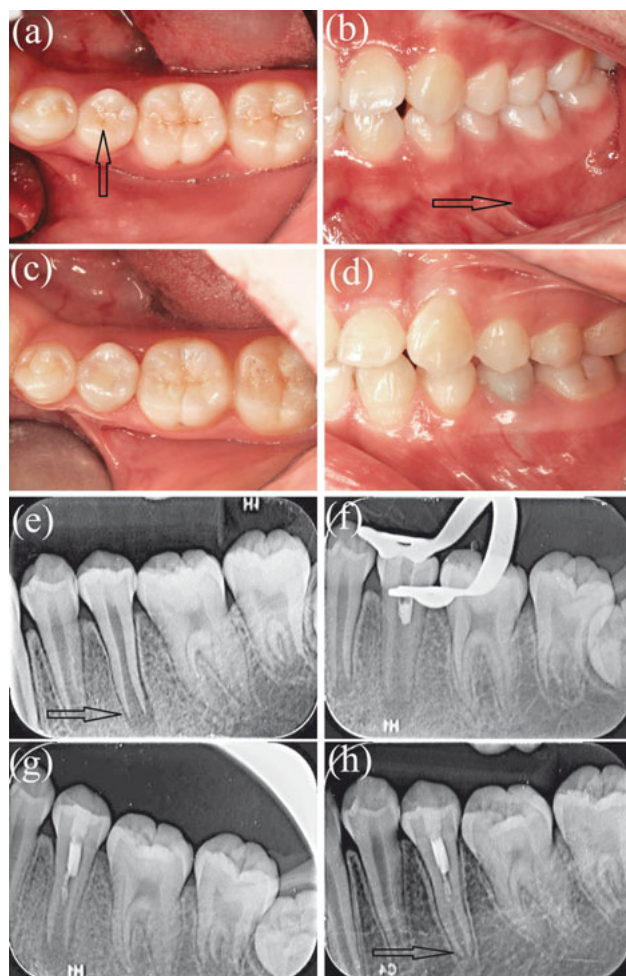


Fig 1 Case 1 intraoral photographs and periapical radiographs. **a)** Pre-treatment occlusal photograph of the mandibular left second premolar (tooth 35) with dens evaginatus and a fractured occlusal tubercle (arrow); **b)** pre-treatment intraoral photograph of tooth 35, showing swelling and redness on the buccal mucosa (arrow); **c)** occlusal photograph at the 8-month follow-up; **d)** intraoral photograph at the 8-month follow-up; **e)** pre-treatment periapical radiograph of tooth 35 showing the periapical radiolucency and immature root (arrow); **f)** periapical radiograph taken during iRoot BP placement; **g)** periapical radiograph taken after completion of the iRoot BP filling at the first treatment visit; **h)** periapical radiograph taken at the 8-month follow-up; the root canal was lengthened, the root wall had thickened and the apical foramen had narrowed (arrow).

Bioceramic paste (iRoot BP) produced a similar pulp tissue response to MTA when used for partial pulpotomy treatment in healthy teeth⁸. Bioceramic sealer packaged in a syringe offers an easy and efficient delivery approach. Therefore, bioceramic materials have raised significant interest amongst endodontists.

Apexification and partial pulpotomy have evolved as treatment options for immature necrotic teeth, espe-

cially in cases of partial pulp necrosis and apical periodontitis involving immature teeth with open apices. Therefore, the present study aimed to clinically and radiographically compare the outcomes of partially pulpotomised immature necrotic permanent molars, treated with iRoot BP or MTA as the capping material.

Case 1

A 10-year-old boy presented with a chief complaint of pain and swelling of the left mandible. The patient had experienced pain on eating or drinking hot or cold food and drunk 6 months earlier, followed by intermittent spontaneous pain and pain during mastication in the same area over the last 2 weeks. The medical history was non-contributory.

On intraoral clinical examination, tooth 35 was discoloured and had dens evaginatus with a fractured occlusal tubercle, but was free of caries (Fig 1a). Localised swelling and redness were observed on the buccal mucosa at the apex of the tooth (Fig 1b). The tooth did not respond to cold testing or electric pulp testing (EPT), whereas positive responses were elicited in the contralateral and neighbouring teeth (45, 34 and 36). Tooth 35 was sensitive to percussion and tender to palpation with class I tooth mobility, with normal periodontal probing depth (2 mm) around the tooth. Periapical radiographic examination revealed that tooth 35 had an open apex with a large periapical radiolucency (Fig 1e).

After clinical and radiographic examination, tooth 35 was diagnosed as an immature tooth with symptomatic apical periodontitis. Given the incomplete root formation and open apex, regenerative endodontic treatment (RET) was proposed. The parent and the child were informed of the risks, complications and possible outcomes of both $\text{Ca}(\text{OH})_2$ apexification and RET. RET was finally chosen for the child and written informed consent was obtained from the parent.

At the first treatment visit, an access cavity was prepared using a fissure bur (Diatech, Heerbrugg, Switzerland) and a high-speed handpiece equipped with a water-spray device under local anaesthesia using 4% articaine (Primacaine Adrenaline, Pierre Rolland, France) and rubber dam isolation. The root canal was gently irrigated with 20 ml of 3% sodium hypochlorite (NaOCl) for 3 min followed by 10 ml sterile normal saline for 3 min with no mechanical instrumentation. Black debris and necrotic pulp tissue was washed out of the root canal, and remnant pink, coherent vital pulp tissue was noted in the middle and coronal parts of the root canal. The canal was then dried with sterile paper

points (Dentsply/Herpo, Rio de Janeiro, Brazil), and a blood clot formed at the exposed vital pulp tissue. iRoot BP (Brasseler USA, Georgia, USA) was placed on the blood clot and vital pulp tissue (Figs 1f and 1g). The access cavity was sealed with glass ionomer cement (3M ESPE, Seefeld, Germany). The patient and his parents received oral hygiene instructions, and were informed that they should return immediately if there was any pain or swelling.

At the 8-month follow-up, the patient returned to our hospital, and stated that his pain and gingival swelling had gradually disappeared following the partial pulpotomy treatment, and there was no other clinical discomfort during this period, apart from a transient throbbing in tooth 35, produced by exposure to cold water. Clinical examination revealed normal periradicular tissues around tooth 35 (Figs 1c and 1d), which was nonsensitive to percussion and palpation testing. Periodontal examination revealed physiological mobility and normal probing depth (< 3 mm) around the tooth. Positive responses were elicited by both cold testing and EPT (value 24), and was similar to the neighbouring tooth 36 (EPT 20). Radiographically, the periapical radiolucency of tooth 35 had significantly decreased in size (Fig 1h).

Case 2

An 11-year-old boy presented with pain and swelling lasting for 3 days in the left mandible. Six months earlier, the patient had suffered from spontaneous pain for several days before visiting his general clinician. At that time, tooth 35 was diagnosed with a fracture of the dens evaginatus and the patient did not receive any treatment. Clinical examination revealed that tooth 35 was free of caries but had dens evaginatus with a fractured occlusal tubercle. Tooth 35 showed no response to cold testing and EPT, but positive responses were elicited in the neighbouring teeth (34 and 36). Tooth 35 was tender to percussion and palpation with slight mobility (class I). A swelling was observed at the apical region of tooth 35 on the buccal side. Periodontal probing depths were all within normal limits. Radiographic examination of the tooth showed an immature root with an open apex and a periapical radiolucency (Fig 2c).

Based on the clinical and radiographic findings, a preliminary diagnosis of symptomatic apical periodontitis of tooth 35 was made. After the access cavity preparation, the pink, coherent vital pulp tissue was observed in the middle and coronal parts of the root canal. A final diagnosis of partial pulp necrosis and symptomatic apical periodontitis was made. Given

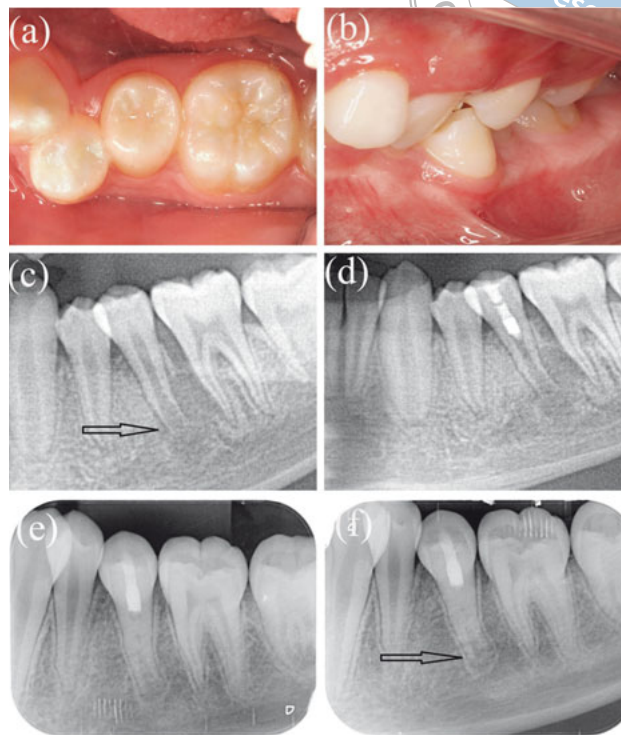


Fig 2 Case 2 intraoral photographs and periapical radiographs. **a)** Occlusal photograph of tooth 35 at the 8-month follow-up; **b)** intraoral photograph at the 8-month follow-up **c)** pre-treatment periapical radiograph of the mandibular left second premolar (tooth 35) showing periapical radiolucency and root immaturity (arrow); **d)** periapical radiograph taken immediately after placement of iRoot BP in the root canal at the first treatment visit; **e)** periapical radiograph taken at the 6-month follow-up; the periapical radiolucency disappeared completely; **f)** periapical radiograph taken at the 8-month follow-up; the thickness of the root wall was increased and the apical foramen was narrowed (arrow).

the incomplete root formation and open apex, partial pulpotomy treatment of tooth 35 was proposed. The treatment procedures were the same as case 1 (Fig 2d).

Six months later, the patient returned to our hospital for a follow-up visit. Radiographic examination revealed that the periapical radiolucency of tooth 35 had disappeared completely (Fig 2e). At the 8-month follow-up, tooth 35 was asymptomatic except for a transient throbbing when exposed to hot water. Radiographically, periapical healing, root lengthening and dentinal thickening of the walls of tooth 35 were observed (Fig 2f). No clinical signs or symptoms were observed (Figs 2a and 2b). Positive responses were elicited by both thermal testing and EPT (value 31), and was similar to the neighbouring tooth 36 (EPT 21).

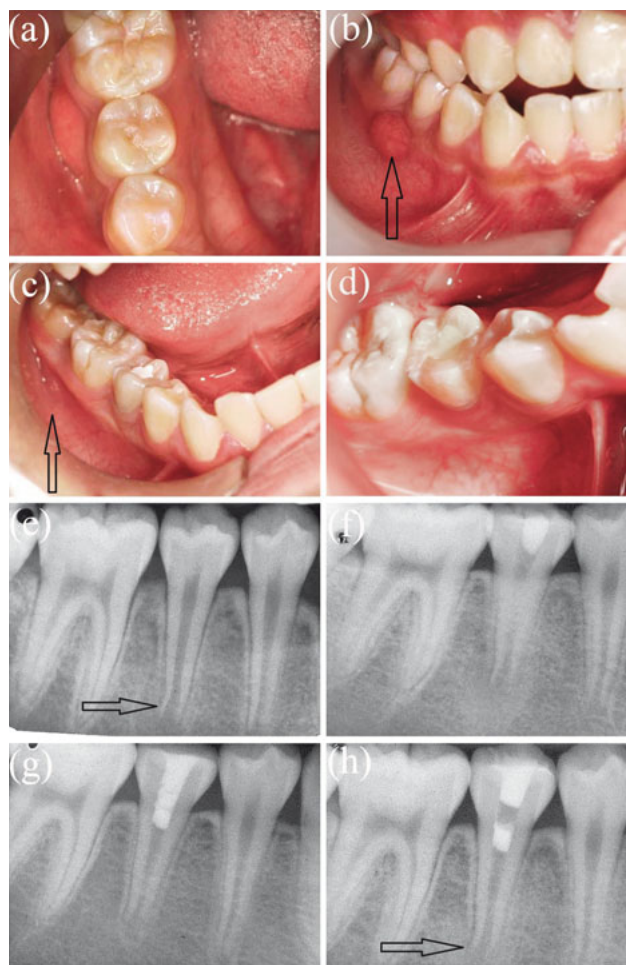


Fig 3 Case 3 intraoral photographs and periapical radiographs. **a)** Pre-treatment occlusal photograph of the mandibular right second premolar (tooth 45); **b)** pre-treatment intraoral photograph showing the draining sinus tract on the buccal side (arrow); **c)** intraoral photograph 2 weeks later; the draining sinus tract had disappeared (arrow); **d)** intraoral photograph at the 8-month follow-up; **e)** pre-treatment periapical radiograph of tooth 45 showing the periapical radiolucency and immature root (arrow); **f)** periapical radiograph taken after filling with calcium hydroxide paste; **g)** periapical radiograph taken 2 weeks later after filling with mineral trioxide aggregate (MTA); **h)** periapical radiograph taken at the 8-month follow-up; the root canal had lengthened and the root wall had thickened (arrow).

Case 3

A 9-year-old boy presented with pain during mastication in the right mandible over the previous 2 weeks. The patient had suffered from pain and swelling in the upper right jaw about 6 months before visiting our department, for which he did not receive any treatment. His medical history was unremarkable. Clinical examination revealed that tooth 45 had a fractured occlusal tubercle (dens

evaginatus) but was free of caries (Fig 3a). A sinus tract was observed on the buccal attached gingival between tooth 45 and tooth 46 (Fig 3b). Tooth 45 was tender to percussion and palpation with class II mobility, and did not respond to cold testing or EPT. Radiographic examination of tooth 45 revealed an immature root with an open apex and a periapical radiolucency (Fig 3e). A preliminary diagnosis of the chronic periradicular abscess was made on the basis of the clinical and radiographic findings. Taking into account the incomplete root development and wide open apex, regenerative endodontic treatment (partial pulpotomy treatment) using MTA was recommended. After informed consent was obtained, treatment was initiated at the same visit.

Local anaesthesia was administered using 2% lidocaine (3M Deutschland GmbH, Seefeld, Germany), and tooth 45 was isolated with a rubber dam. An access cavity was created using a high-speed handpiece equipped with water spray. Then, the pink, coherent vital pulp tissue was noted in the coronal portion of the root canal. The final diagnosis of partial pulp necrosis with a chronic periradicular abscess was made. Thereafter, the coronal portion of the necrotic pulp was amputated, and the canal was irrigated with 20 ml of 3% NaOCl for 3 min and then with 10 ml sterile normal saline for 3 min. The canal was dried with sterile paper points, dressed with $\text{Ca}(\text{OH})_2$ paste (Fig 3f), and sealed with Intermediate Restorative Material (IRM) (Dentsply Caulk, Delaware, USA).

At the second visit 2 weeks later, the patient reported no pain after the treatment. Clinical examination revealed that the buccal sinus tract and gingival swelling had completely disappeared (Fig 3c). Tooth 45 was slightly sensitive to percussion and palpation with class I mobility. The IRM was removed, and the access was opened again under rubber dam isolation. Calcium hydroxide paste was thoroughly removed by irrigating with 20 ml of 3% NaOCl for 3 min and then with 10 ml of sterile normal saline for 3 min. The root canal was then dried with sterile paper points. MTA (ProRoot, Dentsply Tulsa Dental, Tennessee, USA) was placed on the vital tissue and the access cavity was restored with Cavit (GC Corp, Tokyo, Japan) and glass ionomer cement (Fig 3g).

At the 8-month follow-up, tooth 45 was asymptomatic and was not tender to percussion or palpation. No abnormal clinical signs were found in the clinical examination, and tooth 45 had positive responses to cold testing and EPT. Radiographic examination revealed continued root growth and root apex development. The periapical radiolucency had almost completely disappeared, and marked thickening of the root wall,

conspicuous narrowing of the apical foramen, and normal periradicular architecture were observed (Fig 3h). The Cavit was removed and replaced by a resin restoration (Filtek Z350 XT; 3M ESPE Dental Products, Minnesota, USA) (Fig 3d).

Discussion

Fracture of the occlusal tubercle on posterior teeth may cause pulpitis, pulp necrosis and periapical periodontitis owing to tubercular wear or trauma. Historically, apexification or partial pulpotomy has been undertaken by placing Ca(OH)₂ medicament into the canal of the necrotic immature permanent tooth⁹. Recently, MTA has been successfully applied as a pulpotomy medicament for partial pulpotomy in cariously exposed permanent first molars¹⁰. More recently, bioceramics, which possess excellent biocompatibility and physical properties, have attracted attention in the field of endodontics. In addition, the nontoxicity of bioceramics offers a major improvement over MTA, which contains toxic heavy metal components⁶.

In the present case report, MTA and bioceramics were used as pulpotomy medicaments for partial pulpotomies in mandibular second premolars with open apices, partial pulp necrosis and symptomatic apical periodontitis. As expected, the 8-month follow-up results of both the bioceramic material (iRoot BP) and MTA in partial pulpotomies of involved teeth were favourable. The present case series confirms that the biocompatibility and bioactivity of bioceramic materials are comparable with those of MTA, although the chemical composition of the two materials differ. This finding is consistent with a recent randomised controlled trial, that found that the response to partial pulpotomy treatment with both MTA and iRoot BP was satisfactory when treating teeth with healthy pulps⁷.

Unlike MTA, which contains large size particles, iRoot BP is produced with bioceramic nanotechnology and can be extruded through a capillary tip, offering superior handling properties⁷. Furthermore, iRoot BP features a longer working time and shorter setting time than MTA. The setting time of iRoot BP is significantly shorter than MTA because water in the dentinal tubules is used by iRoot BP to drive the hydration reaction; this is different from the mechanism of the MTA setting reaction¹¹. As described in cases 1 and 2, the partial pulpotomies using iRoot BP were carried out in a single visit, whereas in case 3, which used MTA as the pulpotomy agent, two visits were conducted. In fact, MTA has been successfully used as a pulpotomy agent in a single visit without the necessity of Ca(OH)₂

medication¹². Nevertheless, in some clinical cases, the first visit using Ca(OH)₂ dressing is essential due to the persistent bleeding, indistinguishable vital pulp position and acute symptoms of the patient. This advantage of bioceramics over MTA makes it a more clinically practical method. Additionally, MTA is more difficult to remove after setting, when a pulpotomy fails¹¹.

Taken together, based on our 8-month follow-up clinical and radiographic results, we conclude that partial pulpotomies using MTA or bioceramics (iRoot BP) facilitate the continuation of root canal development and maturation, especially in immature permanent teeth with pulp necrosis. In addition, iRoot BP is a viable alternative to MTA, as a pulpotomy medicament, for partial pulpotomy, due to its ease of clinical application. However, long-term follow-up observations are required to assess whether the root apex closes, whether the root structure thickens and whether the root continues to develop.

Conflicts of interest

The authors reported no conflicts of interest related to this study.

Author contributions

- Dr Shan Jiang for the design of the study, for collecting the clinical data, for assisting the surgery and for preparing the manuscript.
- Dr Hao Wu for completing the surgery and preparing the manuscript.
- Dr Cheng Fei Zhang for designing the study, completing the surgery; for revision and final approval of the manuscript.

References

1. Thibodeau B, Trope M. Pulp revascularization of a necrotic infected immature permanent tooth: case report and review of the literature. *Pediatr Dent* 2007;29:47–50.
2. Shabahang S. Treatment options: apexogenesis and apexification. *J Endod* 2013;39(3 Suppl):S26–S29.
3. Andreasen JO, Farik B, Munksgaard EC. Long-term calcium hydroxide as a root canal dressing may increase risk of root fracture. *Dent Traumatol* 2002;18:134–137.
4. Chacko V, Kurikose S. Human pulpal response to mineral trioxide aggregate (MTA): a histologic study. *J Clin Pediatr Dent* 2006;30:203–209.
5. El-Meligy OA, Avery DR. Comparison of apexification with mineral trioxide aggregate and calcium hydroxide. *Pediatr Dent* 2006;28:248–253.
6. Camilleri J, Montesin FE, Brady K, Sweeney R, Curtis RV, Ford TR. The constitution of mineral trioxide aggregate. *Dent Mater* 2005;21:297–303.

7. Koch KA, Brave DG. Bioceramics, part I: the clinician's viewpoint. *Dent Today* 2012;31:130–135.
8. Azimi S, Fazlyab M, Sadri D, Saghiri MA, Khosravanifard B, Asgary S. Comparison of pulp response to mineral trioxide aggregate and a bioceramic paste in partial pulpotomy of sound human premolars: a randomized controlled trial. *Int Endod J* 2014;47:873–881.
9. Frank AL. Therapy for the divergent pulpless tooth by continued apical formation. *J Am Dent Assoc* 1966;72:87–93.
10. Barrieshi-Nusair KM, Qudeimat MA. A prospective clinical study of mineral trioxide aggregate for partial pulpotomy in cariously exposed permanent teeth. *J Endod* 2006;32:731–735.
11. Parirokh M, Torabinejad M. Mineral trioxide aggregate: a comprehensive literature review--Part III: Clinical applications, drawbacks, and mechanism of action. *J Endod* 2010;36:400–413.
12. Qudeimat MA, Alyahya A, Hasan AA, Barrieshi-Nusair KM. MTA pulpotomy for permanent molars with clinical signs indicative of irreversible pulpitis: a preliminary study [Epub ahead of print]. *Int Endod J* 2016 doi: 10.1111/iej.12614.

