

# Evaluation by CBCT of Root and Canal Morphology in Mandibular Premolars in an Iranian Population

Maryam KAZEMIPOOR<sup>1</sup>, Mina POORKHERADMAND<sup>1</sup>, Mehdi REZAEIAN<sup>2</sup>, Yaser SAFI<sup>3</sup>

**Objective:** To compare the root canal morphology in the left and right mandibular premolars on cone beam computed tomography (CBCT) images.

**Methods:** In this analytical cross-sectional study, 457 CBCT images, including human left and right mandibular premolars were evaluated. CBCT scans were investigated in the three spatial planes and differences in the number of roots and canals were recorded. Data were analysed using chi-square test. The significance level was set at  $P < 0.05$ .

**Results:** From 914 mandibular first premolars, in the left side, 85.6% had one root and 14.4% had two roots; 69.6% had one canal and 30.4% had two canals. In the right side 87.3% had one root and 12.7% had two roots; 66.5% had one canal and 33.5% had two canals. There was no statistically significant difference in the number of roots ( $P = 0.440$ ) and canals ( $P = 0.321$ ) between left and right mandibular first premolars. From 914 mandibular second premolars, in the left side, 94.3% had one root and 5.7% had two roots; 77.9% had one canal and 22.1% had two canals. In the right side, 95.6% had one root and 4.4% had two roots; 83.4% had one canal and 16.6% had two canals. There was a significant difference in the number of canals between the left and right mandibular second premolars ( $P = 0.036$ ).

**Conclusions:** The root canal morphology in the mandibular left and right premolars was different, but there was a significant difference only in the number of canals in the mandibular second premolars.

**Key words:** cone-beam computed tomography, mandibular premolar, number of canals, number of roots, root canal morphology

Various factors affect the tooth structure and therefore the need for root canal treatment becomes necessary. The success of root canal treatment depends on the sufficient knowledge about the root canal morphology and also on cleaning, debridement, shaping and sealing of all the canal spaces<sup>1</sup>.

From the early study by Hess and Zurcher<sup>2</sup> to the recent studies, which show the complexity of the root canal anatomy, it has become evident that one root with one conical canal and one foramen is an exception rather than a law<sup>3,4</sup>. Based on numerous studies, the mandibular premolars because of their morphological complexity and given that they consist of a variety of canals, are amongst the most difficult teeth for endodontic treatment<sup>5</sup>.

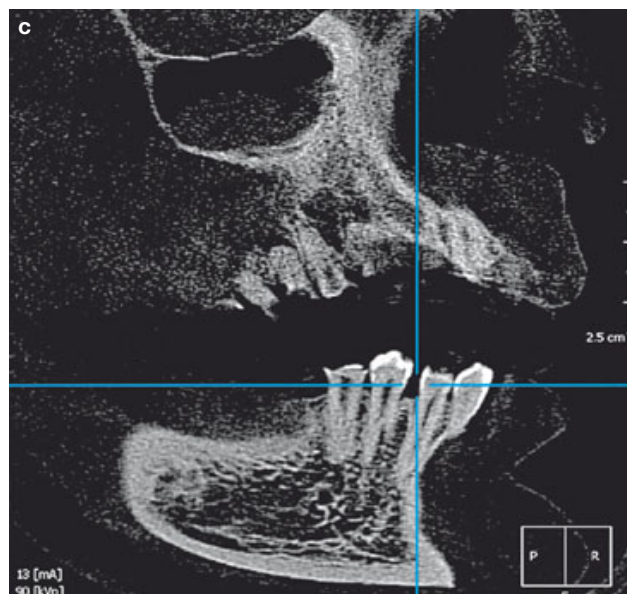
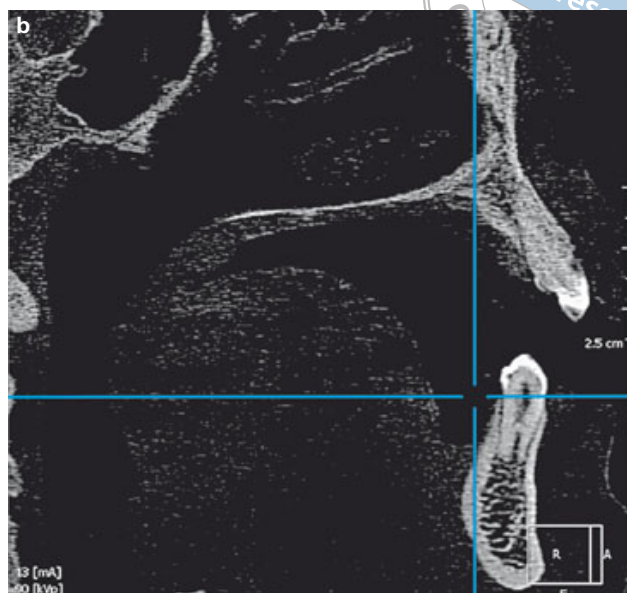
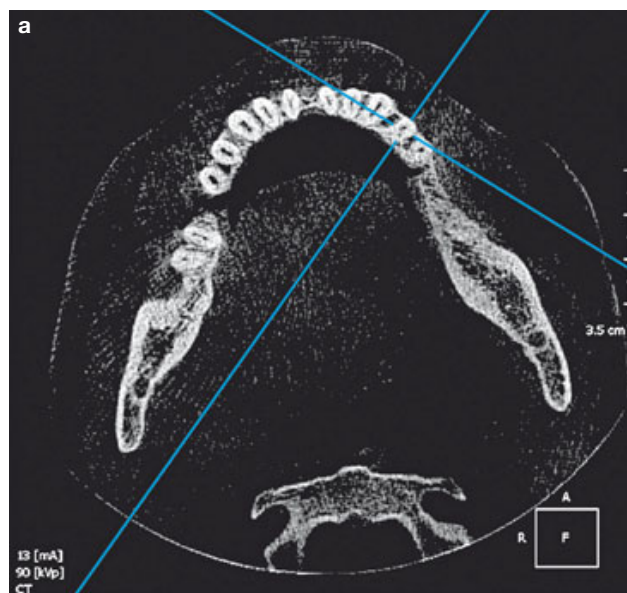
During the last 30 years, various methods such as clearing<sup>6,7</sup>, modelling<sup>8</sup>, histological approaches<sup>9,10</sup> etc have been applied when evaluating the root canal structure<sup>11,12</sup>. Most of these methods are destructive and only provide the 2D evaluation of the root canal system. Recently, the 3D evaluation of the root canal system, which offers higher quality data, without a

1 Department of Endodontics, School of Dentistry, Shahid Sadoughi University of Medical Sciences, Yazd, Iran.

2 Department of Electrical & Computer Engineering, Yazd University, Yazd, Iran.

3 Department of Oral & Maxillofacial Radiology, School of Dentistry, Shahid Beheshti University of Medical Sciences, Tehran, Iran.

**Corresponding author:** Dr Maryam KAZEMIPOOR, Department of Endodontics, School of Dentistry, Emam St. Dahe Fajr Blv, Yazd, Iran. Tel: 98-353-8229076; Fax: 98-353-6250344; Email: dr.kazemipoor@gmail.com



**Fig 1** Cross-sectional CBCT images of the left mandibular first premolar with two clearly distinguished roots and canals: **a)** axial plane; **b)** sagittal plane; **c)** coronal plane.

destructive effect on the tooth structure, can be made with the cone beam computed tomography (CBCT) imaging technique<sup>13</sup>.

The root canal morphology is affected by a number of factors such as race, age, gender, tooth position etc<sup>11</sup>. According to some studies, in different race groups, numerous and various changes have been observed in the root canal system<sup>14</sup>. For example, mostly in the Africa-American race, the mandibular premolar with an extra canal has been observed<sup>15</sup>. Previously, a few studies have shown the impact of tooth position (right and

left) on the structure of the root canal in the mandibular premolars<sup>11,13</sup>.

The purpose of this clinical study was to evaluate and compare the root canal structure in the mandibular left and right premolars in an Iranian population, using CBCT imaging technique.

**Materials and methods**

All the experimental methods in this study were approved by the Ethics Committee of the Shahid Sad-

**Table 1** Number and percentage of roots and canals in the mandibular first premolars.

		Root		Canal	
		Number	Percentage	Number	Percentage
Left	1	391	85.6	318	69.6
	2	66	14.4	139	30.4
Right	1	399	87.3	304	66.5
	2	58	12.7	153	33.5
<i>P</i> value*		0.440		0.321	

\*Chi-square test

**Table 2** Number and percentage of roots and canals in the mandibular second premolars.

		Root		Canal	
		Number	Percentage	Number	Percentage
Left	1	431	94.3	356	77.9
	2	26	5.7	101	22.1
Right	1	437	95.6	381	83.4
	2	20	4.4	76	16.6
<i>P</i> value*		0.364		0.036	

\*Chi-square test

ooghi University of Medical Sciences. CBCT images, which consisted of the mandibular first and second premolars captured bilaterally, were selected from an imaging centre in Tehran city between March 2011 and July 2013. The samples belonged to 457 patients (228 females and 229 males) aged between 15 to 60 years old. CBCT images were captured by Scanora 3D (Soredex, Tuusula, Finland) with image capture parameters set at 90 Kvp and 13 mA and with a scan/exposure time of 16/3.75 s. The slice thickness was 0.50 mm and the Voxel size was 0.20 mm. The exclusion criteria was as follows: the presence of periapical radiolucency, root resorption, open apex, root canal calcification, erosion and attrition, previous root canal treatment, the presence of post, core and extensive restoration. The CBCT images were saved in the DICOM format (Digital Imaging and Communications in Medicine) and analysed with On Demand 3D software (On Demand 3D software version 1, Cyber Med, Seoul, South Korea) using a Toshiba Satellite A200-TH1 notebook (Toshiba Corporation, Class B, Hangzhou, China). Two-dimensional sectional images at the axial, coronal and sagittal planes were displayed on a 15.40 inch, Toshiba Satellite LCD screen with a resolution of 1280 × 800 pixels in a semidark room with fixed light inten-

sity. The CBCT sections at all three planes (especially axial and sagittal) were assessed from the CEJ to the apex and the number of roots and canals were reported (Fig 1). The subsequent data were analysed with SPSS 17 software (SPSS, Illinois, USA) and using the chi-square test. The statistical significance was set at  $P < 0.05$ . The CBCT images were evaluated by an endodontist and a professional oral radiologist.

## Results

The results of this study are summarised in Tables 1 and 2.

### *Mandibular first premolar (MFP)*

- Number of roots: the presence of MFP with one root is higher than with two roots and the occurrence of the roots between the left and the right side did not display any significant difference ( $P_v = 0.440$ ) (Table 1).
- Number of canals: the presence of MFP with one canal is higher than with two canals and the occurrence of the canals between the left and the right side did not display any significant difference ( $P_v = 0.321$ ) (Table 1).

### Mandibular second premolar (MSP)

- Number of roots: the presence of MSP with one root is higher than with two roots and the occurrence of the roots between the left and the right side did not display any significant difference ( $P_v = 0.364$ ) (Table 2).
- Number of canals: the presence of MSP with one canal is higher than with two canals and the occurrence of the canals between the left and the right side showed significant difference ( $P_v = 0.036$ ) (Table 2).

### Discussion

Thorough knowledge of root canal morphology is a basic step in the endodontic treatment. Mandibular premolars, because of the high variability in root canal morphology, are amongst the most difficult teeth for root canal therapy<sup>16</sup>.

Most of the presented clinical and laboratory methods for the anatomical evaluation of the root canal are destructive and have a 2D evaluation of the structure. Recently, the CBCT imaging technique makes it possible to perform 3D evaluation of the root canal, allowing generation of high-quality data, without destruction of the tooth structure<sup>13,17</sup>.

This study used CBCT to assess root canal morphology of mandibular premolars in 457 Iranian individuals. Since various factors such as ethnicity<sup>1,15</sup>, age<sup>2</sup>, gender<sup>3,4</sup>, tooth position<sup>11,13</sup> and the methods for assessment of root canal morphology<sup>18</sup> could affect the results, in the following, we discuss different studies looking into this issue.

### Mandibular first premolar (MFP)

Based on the present study, 86.4% of MFPs had one root and 13.6% had two roots. Moreover, 68.1% of MFPs had a single canal and 31.9% had two canals. According to Kuzekanani et al<sup>19</sup>, out of 280 MFPs, 84.6% had one canal, 13.9% had two canals and 1.5% had three canals. Although the two studies focused on the Iranian population, the difference in results may be due to the method of root canal morphology assessment (CBCT imaging vs clearing method), sample size (914 teeth vs 280 teeth) and given that age and gender were ignored as a contributing factor. Clearing technique is an *in vitro* method that evaluates root canal morphology in the 3D format, however in doing so, the tooth structure is probably destroyed. In comparison to the techniques for detecting the root canal, the CBCT imaging technique reconstructs a 3D aspect of this structure without any destructive effect<sup>20</sup>.

Amin-Sobhani et al<sup>21</sup> conducted a survey on the morphology of MFPs amongst an Iranian population using 400 CBCT samples from patients aged between 20 and 60 years old. According to the results, 98.4% of MFPs had one root, 1.6% had two roots, 87.3% had one canal and 12.7% had two canals. The sample size, ignoring gender as a factor and the type of CBCT equipment used, may have lead to the different results. Scanora 3D, in comparison to other CBCT equipment, has more accuracy and precision in all three spatial planes when evaluating delicate structures such as the root canal system<sup>22</sup>.

Cleghorn et al<sup>14</sup> in a review article reported that approximately 98% of MFPs had one root, 1.8% had two roots, 0.2% had three roots and < 0.1% had four roots. Of the mandibular first premolars, 75.8% had one canal and 24.2% had two canals or more. Trope et al<sup>15</sup>, Lu et al<sup>16</sup> and Walker<sup>23</sup> have also evaluated the root canal morphology of MFPs in different races and have reported different results.

The impact of another factor is also overlooked in these types of studies: gender. According to the existing studies, the genes, which codify the root canal morphology, are located on the X-chromosome<sup>24</sup>. The probability of the presence of two or more canals and roots in MFPs is higher in the females<sup>4,25,26</sup>. Therefore, the present study tried to equally eliminate this interfering factor between the two genders.

Deposition of secondary dentin on the interior walls of the dentin would change the canal structure and even create two or more separate canals<sup>27</sup>. This factor could be controlled properly in the clinical studies and not in the laboratory studies<sup>17</sup>. In this clinical survey, the participants' age was 15 to 60 years old. For participants under 15 years old the root development in this tooth group had not been completed and many changes in the root canal structure may occur in this period of time<sup>2,28,29</sup>.

Presently, a few studies have evaluated the effect of position (left and right) on the root canal morphology<sup>11,13</sup>. Park et al<sup>13</sup> conducted a survey to compare the root canal morphology in the MFPs at the left and right side in a Korean population. Amongst 396 MFPs in the right side, 49.6% had one root and 0.1% had two roots. In the left side, 50.3% were one-rooted and two-rooted MFPs were not observed. There was no statistically significant difference between left and right MFPs in the root canal morphology.

According to a study by Yu et al<sup>11</sup>, in a Western Chinese population of 178 MFPs, in the left side, 78 teeth had one root, 1 tooth had two roots, 68 teeth had one canal, 9 teeth had two canals, and 1 tooth had a C-shaped canal. In the right side 96 teeth had one root,

3 teeth had two roots, 87 teeth had one canal, 11 teeth had two canals, and 1 tooth had three canals.

In the present study, out of 457 MFPs in the left side, 85.6% were one-rooted, 14.4% were two-rooted, 69.6% had one canal and 30.4% had two canals. In the right side, out of 457 MFPs, 87.3% had one root, 12.7% had two roots, 66.5% had one canal and 33.5% had two canals. The probability of being two-rooted and having one canal was slightly higher in the left side but the difference was not statistically significant. The findings of the present study differ from the Park et al and Yu et al studies. It may be because of the race difference, gender, sample size, the type of the CBCT set and the applied software.

#### *Mandibular second premolar (MSP)*

In this study, 95.0% of MSPs had one root, 5.0% had two roots, 80.6% had one canal and 19.4% had two canals. According to Cleghorn et al<sup>30</sup>, approximately 99.6% of MSPs had one root, 0.3% had two roots, < 0.1% had three roots, 91.0% had one canal and 9.9% had more than one canal. Caliskan<sup>3</sup>, in a study on a Turkish population, reported that the prevalence of MSPs with more than one canal was 6.4%. The difference in the ethnicity, age group and methods of root canal morphology assessment may lead to different results.

In the present study, out of 457 MSPs in the left side, 94.3% were one-rooted and 5.7% were two-rooted. Out of 457 MSPs, in the right side, 95.6% had one root and 4.4% had two roots. In the left side of 457 MSPs, 77.9% had one canal and 22.1% had two canals; in contrast in the right side 83.4% had one canal and 16.6% had two canals.

Based on the Park et al<sup>13</sup> study, out of 397 MSPs, in the left side 49.4% had one root and 0.3% had two roots. In the right side 49.9% had one root and 0.4% had two roots. In this population, there was no significant difference in the root canal morphology of the left and right MSPs.

Yu et al<sup>11</sup> reported that out of 178 MSPs, 79 teeth in the left side and 99 teeth in the right side were one-rooted. Also in the left side 76 teeth had one canal and 3 teeth had two canals. In the right side, 94 teeth had one canal, 3 teeth had two canals and 1 tooth had a C shaped canal.

Overall, the root canal morphology in the left and right mandibular second premolars is not the same and the number of canals in one side does not determine the root canal morphology in the opposite site.

Based on our findings, in the left and right MSPs, the difference in the number of canals was statistically

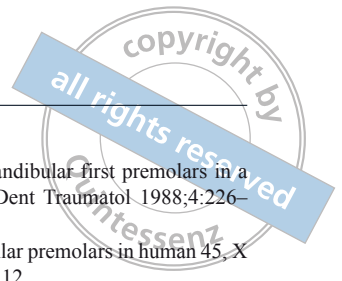
significant, however there was no statistical significance in the number of roots. The difference in the results may be caused by sample size, ethnicity, the variation in the evaluation method (2D vs 3D evaluation), and given that gender and age were ignored as contributing factors.

#### **Acknowledgement**

The authors wish to give special thanks to Roqayeh Hakimian for her contributions to the manuscript and Mohammad Hossein Ahmadi for his statistical advice.

#### **References**

1. Uzun O, Topuz O, Yalpi F, Unsal F, Aydin C, Bodrumlu E. The evaluation of two rotary instrumentation techniques under „operator-related variables“ standardized conditions. *Eur J Dent* 2013;7:395–398.
2. Pattanshetti N, Gaidhane M, Al Kandari AM. Root and canal morphology of the mesiobuccal and distal roots of permanent first molars in a Kuwait population--a clinical study. *Int Endod J* 2008;41:755–762.
3. Caliřkan MK, Pehlivan Y, Sepetçiođlu F, Türkün M, Tuncer SS. Root canal morphology of human permanent teeth in a Turkish population. *J Endod* 1995;21:200–204.
4. Sert S, Bayirli GS. Evaluation of the root canal configurations of the mandibular and maxillary permanent teeth by gender in the Turkish population. *J Endod* 2004;30:391–398.
5. Vertucci FJ. Root canal anatomy of the human permanent teeth. *Oral Surg Oral Med Oral Pathol* 1984;58:589–599.
6. Rwenyonyi CM, Kutesa AM, Muwazi LM, Buwembo W. Root and canal morphology of maxillary first and second permanent molar teeth in a Ugandan population. *Int Endod J* 2007;40:679–683.
7. Madeira MC, Hetem S. Incidence of bifurcations in mandibular incisors. *Oral Surg Oral Med Oral Pathol* 1973;36:589–591.
8. Gomes BP, Rodrigues H, Tancredo N. The use of a modelling technique to investigate the root canal morphology of mandibular incisors. *Int Endod J* 1996;29:29–36.
9. Bagherian A, Kalhori KA, Sadeghi M, Mirhosseini F, Parisay I. An in vitro study of root and canal morphology of human deciduous molars in an Iranian population. *J Oral Sci* 2010;52:397–403.
10. Michetti J, Maret D, Mallet JP, Diemer F. Validation of cone beam computed tomography as a tool to explore root canal anatomy. *J Endod* 2010;36:1187–1190.
11. Yu X, Guo B, Li KZ, et al. Cone-beam computed tomography study of root and canal morphology of mandibular premolars in a western Chinese population. *BMC Med Imaging* 2012;12:18.
12. Kim Y, Perinpanayagam H, Lee JK, et al. Comparison of mandibular first molar mesial root canal morphology using micro-computed tomography and clearing technique. *Acta Odontol Scand* 2014;1–6.
13. Park JB, Kim N, Park S, Kim Y, Ko Y. Evaluation of root anatomy of permanent mandibular premolars and molars in a Korean population with cone-beam computed tomography. *Eur J Dent* 2013;7:94–101.
14. Cleghorn BM, Christie WH, Dong CC. The root and root canal morphology of the human mandibular first premolar: a literature review. *J Endod* 2007;33:509–516.
15. Trope M, Elfenbein L, Tronstad L. Mandibular premolars with more than one root canal in different race groups. *J Endod* 1986;12:343–345.
16. Lu TY, Yang SF, Pai SF. Complicated root canal morphology of mandibular first premolar in a Chinese population using the cross section method. *J Endod* 2006;32:932–936.



17. Kottoor J, Albuquerque D, Velmurugan N, Kuruville J. Root anatomy and root canal configuration of human permanent mandibular premolars: a systematic review. *Anat Res Int* 2013.
18. Neelakantan P, Subbarao C, Subbarao CV. Comparative evaluation of modified canal staining and clearing technique, cone-beam computed tomography, peripheral quantitative computed tomography, spiral computed tomography, and plain and contrast medium-enhanced digital radiography in studying root canal morphology. *J Endod* 2010;36:1547–1551.
19. Kuzekanani M, Asgari E. The incidence of mandibular first premolar teeth with 2 canals in a group of Kerman population (2002-2003). *J Dent Sch* 2005;23:286–293.
20. Lauber R, Bornstein MM, von Arx T. Cone beam computed tomography in mandibular molars referred for apical surgery [in German]. *Schweiz Monatsschr Zahnmed* 2012;122:12–24.
21. Amin Sobhani M, Razmi H, Sadegh M. Evaluation of anatomy and morphology of human mandibular premolar teeth by cone-beam computed tomography in Iranian population. *JDM, Tehran University of Medical Sciences* 2013;26:203–210.
22. Hassan B, Metska ME, Ozok AR, van der Stelt P, Wesselink PR. Comparison of five cone beam computed tomography systems for the detection of vertical root fractures. *J Endod* 2010;36:126–129.
23. Walker RT. Root canal anatomy of mandibular first premolars in a southern Chinese population. *Endod Dent Traumatol* 1988;4:226–228.
24. Varrel J. Root morphology of mandibular premolars in human 45-X females. *Arch Oral Biol* 1990;35:109–112.
25. Serman NJ, Hasselgren G. The radiographic incidence of multiple roots and canals in human mandibular premolars. *Int Endod J* 1992;25:234–237.
26. Iyer VH, Indira R, Ramachandran S, Srinivasan MR. Anatomical variations of mandibular premolars in Chennai population. *Indian J Dent Res* 2006;17:7–10.
27. Morse DR. Age-related changes of the dental pulp complex and their relationship to systemic aging. *Oral Surg Oral Med Oral Pathol* 1991;72:721–745.
28. Lunt RC, Law DB. A review of the chronology of eruption of deciduous teeth. *J Am Dent Assoc* 1974;89:872–879.
29. Barrett MT. The internal anatomy of the teeth with special reference to the pulp and its branches. *Dent Cosmos* 1925;67:581–592.
30. Cleghorn BM, Christie WH, Dong CC. The root and root canal morphology of the human mandibular second premolar: a literature review. *J Endod* 2007;33:1031–1037.