

# Prosthodontic Treatment for Severe Oligodontia with Long-term Follow-up

Xiao Xia ZHANG<sup>1</sup>, Dong PENG<sup>1</sup>, Hai Lan FENG<sup>1</sup>

**Objective:** To express the early prosthodontic treatment strategies for severe oligodontia patients with or without a syndrome and to share details of their experiences of the long-term follow-up.

**Methods:** Patients with severe oligodontia (excluding the third molars, and with six or more congenitally missing permanent teeth) who had finished prosthetic rehabilitation between 2001 and 2014 and who had undergone at least 1-year follow-up at the Department of Prosthodontics, Peking University School of Stomatology were included in the study. The general and oral characteristics were determined and examined, interdisciplinary plans were provided, and the prosthodontic treatment conditions were described and evaluated.

**Results:** In total 26 subjects were included. Twenty males and six females, whose first dental visit occurred between the ages of 2 years and 9 months old, and 31 years old were recorded, of which, 12 (46.2%) subjects had non-syndromic oligodontia and 14 (53.8%) had oligodontia with different syndromes. The number of congenitally missing teeth (excluding the third molars) was between 7 to 28 (mean = 18), with 14 and 21 teeth in the non-syndromic and syndromic oligodontia patients, respectively. Most of the patients accepted conventional prostheses and two had implant-supported crowns or bridges. The age of the first prosthesis delivery ranged from 3.5 to 31 years old. The follow-up period ranged from 15 months (1 year and 3 months) to 162 months (13.5 years), with a mean of 108 months (9 years).

**Conclusion:** Early treatment for young patients and long-term follow-up greatly benefits patients. Interdisciplinary treatment ensures more satisfactory results.

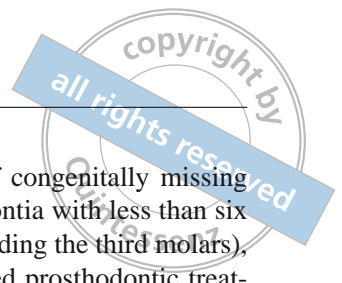
**Key words:** follow-up, oligodontia, prosthodontics, treatment

Hypodontia, also known as selective tooth agenesis or congenitally missing teeth, is the developmental absence of at least one permanent tooth and is the most common dental anomaly in man. The overall prevalence of hypodontia (excluding the third molars) in the present literature is 6.4% (3.2% to 13.4%), with differences in terms of the continent and populations, of which, mild, moderate and severe hypodontia was found to be 81.6%, 14.3% and 3.1% respectively<sup>1</sup>. Oligodontia, usually referring to severe hypodontia, is defined as the con-

genital absence of six or more teeth (excluding the third molars) and has an estimated prevalence of approximately 0.10% to 0.42%, according to the data reviewed by Khalaf et al<sup>1</sup>. Oligodontia may occur either sporadic or familial, and present as an isolated symptom or as part of the syndrome<sup>2</sup>. The isolated oligodontia is more commonly called non-syndromic oligodontia at present, in which the patients have only congenitally missing teeth without other developmental abnormalities. In more cases, the severe oligodontia appears as a simultaneous phenomenon with several systemic syndromes. The ectodermal dysplasias (EDs) are a large and complex group of diseases that have anomalies of the hair, teeth, nails and sweat glands, with or without anomalies in other organs and systems. X-linked anhidrotic (hypohidrotic) ectodermal dysplasia (HED/EDA) is one of the most common types of genetic ectodermal dysplasia

<sup>1</sup> Department of Prosthodontics, Peking University School and Hospital of Stomatology, Beijing, P.R. China.

**Corresponding author:** Dr Hai Lan FENG, Department of Prosthodontics, Peking University School and Hospital of Stomatology, #22 Zhongguancun South Avenue, Haidian District, Beijing 100081, P.R. China. Tel: 86-10-82195232; Fax: 86-10-62173402. Email: kqfenghl@bjmu.edu.cn



disorders with oligodontia, which is characterised by hypohidrosis, sparse hair and teeth abnormalities, with an overall prevalence range between 3.4 and 15.8 per 100,000 people<sup>3</sup>. Odonto-onycho-dermal dysplasia is a rare syndrome in which the presenting phenotype is dry hair, severe hypodontia, smooth tongue with a marked reduction of fungiform and filiform papillae, onychodysplasia, keratoderma and hyperhidrosis of palms and soles, and hyperkeratosis of the skin<sup>4</sup>. Several rare forms of syndromic oligodontia may be seen in dental clinics like Rieger syndrome, a rare autosomal-dominant disorder characterised by dental, ocular and periumbilical abnormalities<sup>5</sup>, and Hallermann-Streiff syndrome (HSS), a rare congenital disorder characterised by significant craniofacial findings with additional features of dental anomalies, micrognathia, skeletal defects, and short stature<sup>6,7</sup>.

Severe oligodontia contributes to masticatory dysfunction, speech alteration, aesthetic problems and malocclusion, while even more anodontia may cause psychological damage and lower social adaptability, especially to those affected with primary teeth. Although numerous gene mutations and underlying functions have been found to be associated with oligodontia<sup>8-13</sup>, the treatment of oligodontia remains a challenge to clinicians and requires an interdisciplinary team approach involving pedodontists, orthodontists, maxillofacial surgeons and prosthodontists<sup>14</sup>. In this article, the authors' experiences of the interdisciplinary plan and the prosthodontic rehabilitation of the 26 severe oligodontia cases, with or without a syndrome, were reported and long-term follow-up and early treatment strategy were implemented.

## Materials and methods

### *Patients and methods*

The patients with severe oligodontia that came to the Department of Prosthodontics, Peking University School and the Hospital of Stomatology for oral rehabilitation, from 2000 to 2014, underwent oral examination, impression and plaster model analysis, X-ray panoramic examination, dental and systemic history recording and investigation of their family histories. Patients whose congenitally missing teeth could be confirmed and who had six or more congenitally missing teeth (excluding the third molars), were included in this study. They were provided with an interdisciplinary treatment plan, completed the prosthodontic rehabilitation and at least 1-year follow-up during May 2015. In patients who could not

confirm the status or number of congenitally missing teeth, or where there was hypodontia with less than six congenitally missing teeth (excluding the third molars), or for those who had not received prosthodontic treatment, these patients were excluded.

For all subjects, clinical data were collected and diagnosis was carried out, acceptable treatment and prosthodontic rehabilitation were provided and some received molecular genetic diagnosis, which was confirmed afterwards by other studies carried out by the research group<sup>5,10,15</sup>. The characteristics of the subjects, prosthodontic treatment and the status of follow-up were described and evaluated.

All patients and the parents, for patients who were underage, were briefed on the study procedures and informed consent was obtained.

## Results

In total 26 severe oligodontia subjects completed interdisciplinary treatment and prosthodontic rehabilitation with more than 1 year of follow-up. The general characteristics of the patients are presented in Table 1. Twenty males and six females, whose first dental visit was between the ages of 2 years and 9 months old and 31 years old were recorded, of which, 12 (46.2%) subjects were diagnosed as non-syndromic oligodontia and 14 (53.8%) were diagnosed as oligodontia with different syndromes.

The number of congenitally missing teeth (excluding the third molars) ranged from 7 to 28 (mean = 18), with 14 and 21 teeth in non-syndromic and syndromic oligodontia patients, respectively. Eleven patients were affected by primary teeth agenesis, of which, nine were diagnosed with syndromic oligodontia (all were HED/EDA patients) and two were diagnosed with non-syndromic oligodontia. With regard to the absence of permanent teeth, ten had typically conical incisors, of which most were maxillary central incisors of HED/EDA patients and some were pig-shaped maxillary lateral incisors in the non-syndromic oligodontia patients (Table 2). All patients had multiple diastemas and malocclusion, and some had severe jaw dysplasia, especially those with Rieger syndrome.

Table 3 shows the treatment plan which was carried out and the prosthodontic rehabilitation for the patients: five with fixed restorations (veneers, crowns and bridges), 23 with removable dentures (partial dentures and complete dentures including overdentures) and two with implant-supported restorations. Also there were some patients who received more than one kind of restoration. Aside from the conventional treatment

**Table 1** General characteristics of the patients.

Diagnosis		Number of patients			Age at first dental visit (year)			
		Total	Male	Female	2 to 6	7 to 12	13 to 20	> 20
Non-syndromic		12	9	3	2		4	6
Syndromic	HED/EDA	8	8	0	7	1		
	RS	4	2	2			3	1
	HSS	1		1			1	
	ODDD	1	1				1	

HED/EDA: hypohidrotic/anhidrotic ectodermal dysplasia; RS: Rieger's syndrome; HSS: Hallermann-Streif syndrome; ODDD: Odonto-onycho-dermal dysplasia.

**Table 2** Number of congenitally missing teeth and the incidence of teeth anomalies.

	Non-syndromic oligodontia	Syndromic oligodontia	Total
Number of congenitally missing permanent teeth per patient	7 to 19 (mean 14)	11 to 28 (mean 21)	7 to 28 (mean 18)
Primary teeth affected	2/12	9/14	11/26
Conical shape of incisors	3/12	7/14	10/26

of necessary pedodontic, periodontic, endodontic or carries restorations, four patients underwent orthodontic treatment before the prosthodontic rehabilitation; one with a removable appliance and three with a fixed appliance, of which one individual received implant-anchored orthodontic treatment. The age of the first prosthesis delivered ranged between 3.5 years old and 31 years old. The follow-up period ranged from 15 months (1 year and 3 months) to 162 months (13 years and 6 months), with a mean of 108 months (9 years). During the follow-up period, due to growth, 8 patients underwent prostheses change two or more times; of which, 2 patients underwent prostheses change three times, 1 patient underwent prostheses change four times and 1 patient underwent prostheses change eight times.

### Typical cases

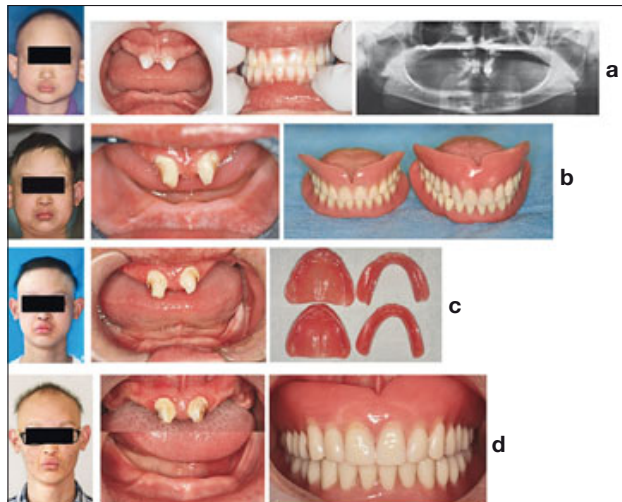
#### Case 1

A boy with typical characteristics of EDA underwent prostheses changes four times during the 13.5-year follow-up period, with the first rehabilitation at the age of 5.5 years old when the prostheses were delivered.

**Table 3** Prosthetic rehabilitation of 26 patients who had completed treatment.

Type of prosthetics	Number of the patients
Veneer, crown and conventional bridges	5
Removable partial dentures or complete (over) denture	23
Implant-supported crown and bridges	2
Orthodontic treatment before prosthetics	4

The other three occasions at which prostheses change occurred were at 10, 13 and 17 years old, respectively. Only the two maxillary central incisors existed in both the primary and permanent dentition. Due to the

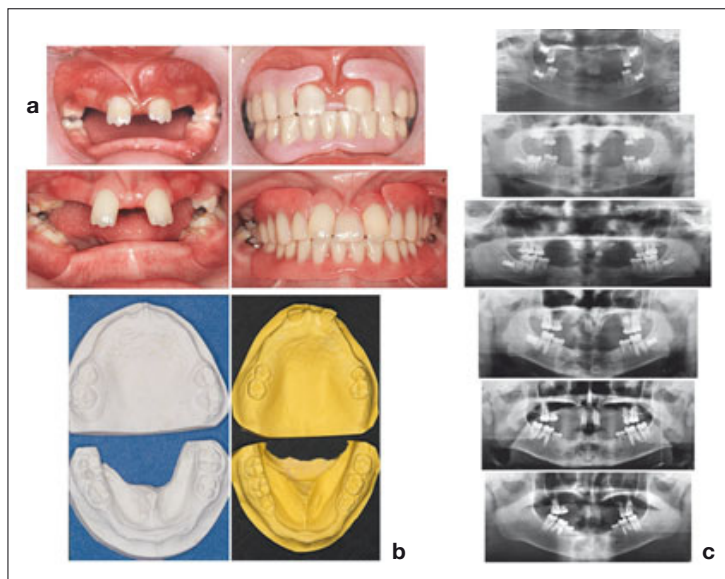

**Fig 1** The changes in our patient in case 1 with typical symptoms of hypohidrotic/anhidrotic ectodermal dysplasia (HED/EDA) and his dentures are shown. These were taken at the ages of 5.5 years, 10.0 years, 13.0 years and 17.0 years in (a), (b), (c) and (d), respectively. The panoramic radiograph revealed that only two primary teeth and two permanent teeth exited (51 and 61, and 11 and 21, respectively). The natural teeth erupted conically with enamel hypoplasia in the two permanent teeth, the dentures compared with the former (in b and c), and jaw and alveolar development was observed.

abnormal shape of the incisors, the poorly developed alveolar process, and the young age of the individual, complete overdentures were provided and were changed subsequently during growth. Figure 1 illustrates the four prosthodontic treatments and the growth of the patient. This sufficiently helped in rehabilitating his oral function and the patient was satisfied with the dentures.

**Case 2**

The patient in case 2 was a young boy diagnosed with non-syndromic oligodontia whose first dental visit was at 2 years and 9 months old. His parents complained of many congenitally missing primary teeth. The panoramic radiograph further revealed that most of his permanent teeth germs were missing. Due to difficulties in the dental treatment, the patient accepted prosthodontic treatment until 5.5 years old, with maxillary and mandibular removable partial dentures, which greatly improved the oral function of chewing and his physical development. The casts and the changing panoramic radiographs showed that the dentition and the alveolar developed in conjunction with the growth of the child (Fig 2). Due to the continuous growth of the patient and his new teeth, as well as the compliance of his parents, he changed his dentures 8 times in total from the age of 5.5 years old to 16.5 years old in the 13-year follow-up, at a frequency of almost once every year during the rapid growth period. Moreover, the selective grinding of the dentures was carried out on each visit, in order to make them more adaptive to the continuous eruption of the teeth with development.



**Fig 2** The non-syndromic oligodontia patient from a young age to adolescence. (a) The four panels show the oral view and the dentures at the ages of 7 years and 4 months and 12 years 7 months, which were two examples of his eight prostheses changes, during the 13-year follow-up period. The conservative attitude of his parents meant that they did not accept any traumatic treatment including orthodontics. (b) In the two lower panels, the casts at the age of 5 years and 6 months (left, white) and 13 years and 9 months (right, yellow) showed significant growth of the teeth and the dentoalveolar. Note that the lower second primary molar teeth 'subsided' with the development of the mandible and the eruption of the second molars. (c) The six panoramic radiographs (right column) presented from the top down were recorded at the ages of 2 years and 9 months, 4 years and 4 months, 5 years and 4 months, 6 years and 9 months, 11 years, and 13 years and 9 months, respectively. This is a clear example of the existing teeth changes in accordance with the child's growth.



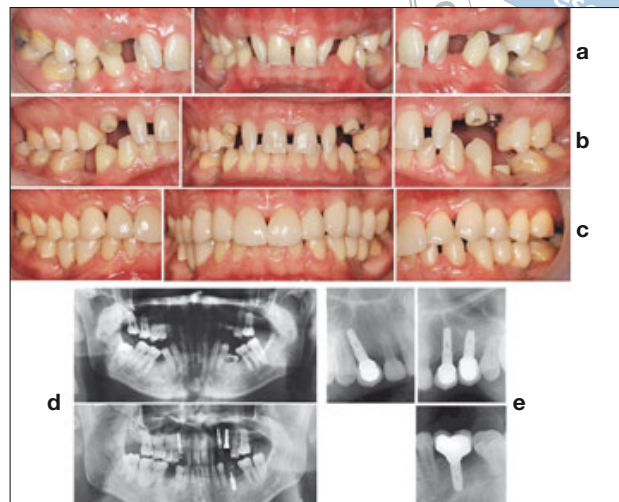### Case 3

The 22-year-old male patient who was well-developed and in good health, showed the typical symptoms of teeth abnormalities in non-syndromic oligodontia: some congenitally missing permanent teeth, central incisors with a slightly small width, conical or pig-shaped lateral incisors, retained deciduous teeth, inclination and diastemas which together resulted in malocclusion. Fortunately, almost all molars were normally erupted and could provide vertical support by the natural teeth. Long-term orthodontic treatment with an implanted anchor was fulfilled, and finally, ceramic veneers for 11 and 21; ceramic crowns for 12 and 22; porcelain fused metal bridges for 45 (44 and 46 as retainers); and implant-supported crowns for 13, 23, 24 and 35 were completed, in order to ensure a satisfactory prosthodontic rehabilitation, both in terms of aesthetics and function (Fig 3).

### Discussion

It is not such an issue when there is only one or a few congenitally missing teeth, while it brings a challenge to the clinicians facing the status of many, most or even all of the congenitally missing teeth, especially in patients who are young children. With the absence of tooth germs, the alveolar could not develop normally which results in supporting tissue which is insufficient for prosthodontic treatment. However there are many other dentoalveolar characteristics often associated with oligodontia, such as occlusal disturbances like deep bite, cross bite, steep inclination of maxillary incisors, abnormal attrition, disturbances of eruption like over eruption of teeth antagonising hypodontia, ectopic eruption, multiple diastemas, rotation of teeth; and alterations of tooth morphology like microdontia and the conical shape of incisors and canines<sup>14</sup>, all of which were indicated in our patients.

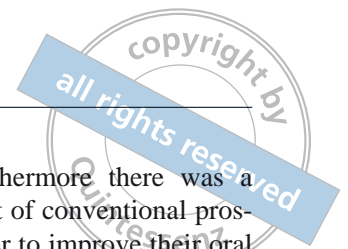Generally, in comparison to non-syndromic patients, oligodontia results in a more severe affect on the number of missing teeth, malocclusion, unsatisfactory jaw relationship and affected primary teeth in syndromic patients, according to reported literature<sup>2</sup> and our clinical experiences in the treatment of this type of patient. Amongst the limited literature concerning congenitally missing primary teeth<sup>16,17</sup>, the prevalence is under 1% in the epidemiology study, which is much less than hypodontia in permanent dentition. With regard to the results of our study, all subjects with hypodontia of the primary dentition presented with hypodontia of the permanent dentition, which is similar to that reported in the literature<sup>16-18</sup>, while most of the permanent teeth hypodontia patients have normal primary dentition. The



**Fig 3** The oral views (nine upper panels) of the original status (a) after orthodontic treatment and after implant surgery (with temporary abutments) (b), and the completed prosthodontic treatment of ceramic veneers for 11 and 21, the ceramic crowns for 12 and 22, the porcelain fused metal bridge for 45 (44 and 46 as retainers), and the implant-supported crowns of 13, 23, 24, 35 (c). (d) The panoramic radiographs of the original status (upper) and after orthodontic treatment and implant surgery (lower). (e) The periapical radiographs of implant-supported crowns for 13, 23, 24 and 35, respectively, which were recorded 9 months after the prosthodontic treatment was completed.

patients with agenesis of primary dentition usually are referred to clinicians at an early age before school years, which is why more than one third (9/26) of the subjects in our study received the first prosthetics between 3 to 6 years old, of which, HED/EDA is the main cause of primary teeth hypodontia.

Nowadays, dental implants are more widely used and have become more popular with both clinicians and patients. Many studies have reported successful rehabilitation of patients with oligodontia with implant-supported prostheses<sup>19-22</sup>; even in severe oligodontia at an early age, with implant-supported dentures<sup>23-27</sup>, the aesthetic and functional outcomes were satisfactory and the quality of life was greatly improved. As far as early dental implant therapy in tooth agenesis is concerned, Worsae<sup>14</sup> agreed that unless special circumstances indicate the use of implants in adolescents, they should not be inserted until skeletal growth is completed. Also Yap



et al<sup>28</sup> found that implant survival rates varied between 88.5% and 97.6% in patients with ectodermal dysplasia (ED) and between 90.0% and 100% in patients with tooth agenesis. Furthermore no randomised controlled studies or case-controlled studies were found to provide evidence that the implants placed in adolescent ED patients have a significant effect on craniofacial growth, while implants placed in ED patients younger than 18 years old have a higher risk of failure. There are several studies which claim that, providing that other treatment options are considered, the areas of skeletal growth are respected and the patients are well-informed, specifically adolescents with extensive oligodontia<sup>29</sup>. Early implant-borne prosthetic rehabilitation is an alternative, which could become a first-line treatment, given that it restores orofacial functions, allowing for better development of maxillofacial bones<sup>24</sup>.

The results of our study indicate most patients accepted removable partial dentures, complete dentures or overdentures and during the follow-up period, they were satisfied with the improvement in oral function and aesthetics. The ideal interdisciplinary plan should be a team approach involving pedodontists, orthodontists, prosthodontists and maxillofacial surgeons. However, there are many factors affecting the treatment plan provided and the actual conditions accepted by the patients and their parents. For example, the patients' age and growth, the lengthy time period of orthodontic visits, the risk of orthognathic surgery, the financial burden of implant prostheses for those diagnosed with severe oligodontia with poor supporting tissue, the compliance of the patients/or the parents, and the acceptance of complicated and traumatic treatment. Many psychological and social determinants influence patients' values and decision-making when planning for restorative dentistry. This leads to a treatment plan agreed between the patient and the clinician. Often an element of compromise is considered acceptable to both parties when the evidence would suggest an alternative treatment to be preferable<sup>30</sup>. In our study, most patients were below the age of adolescence and with extensive oligodontia to anodontia, which is why only two patients who had the least number of teeth missing (7 and 8 teeth) received implant-supported crowns (Fig 3) or bridges, whilst conventional and minor traumatic treatment was more easily accepted and used in most patients. As the patients grow older, there will be more preferable options available to them which meet the higher requirements of function and aesthetics.

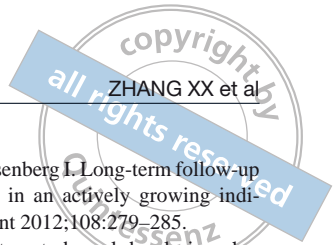The implant-supported prosthetics were successful in patients who were very young children and who were adolescents, however these require more long-

term outcome evaluation. Furthermore there was a consensus on the early treatment of conventional prostheses for these children, in order to improve their oral function, dentoalveolar growth, and their physical and mental health<sup>31,32</sup>. This was similar to what most of our patients experienced, i.e. those who received early prosthodontic rehabilitation from a very young age to adulthood during the follow-up period.

Based on our own experiences it is difficult to complete a long term follow-up for patients who are very young children. This is due to the compliance of these patients and their parents, the migration of the family, the distance and convenience that the patient has to a high level dental treatment facility, the acceptance of the treatment, the socioeconomic conditions of the family, and finally how proactive the parents are about the treatment. A good relationship between the clinician and the patient which is based on adequate communication and trust is important. This will ensure each patient receives the confidence and support to complete the treatment and the follow-up.

## References

1. Khalaf K, Miskelly J, Voge E, Macfarlane TV. Prevalence of hypodontia and associated factors: a systematic review and meta-analysis. *J Orthod* 2014;41:299–316.
2. Schalk-van der Weide Y, Steen WH, Bosman F. Distribution of missing teeth and tooth morphology in patients with oligodontia. *ASDC J Dent Child* 1992;59:133–140.
3. Nguyen-Nielsen M, Skovbo S, Svaneby D, Pedersen L, Fryzek J. The prevalence of X-linked hypohidrotic ectodermal dysplasia (XLHED) in Denmark, 1995–2010. *Eur J Med Genet* 2013;56:236–242.
4. Adaimy L, Chouery E, Megarbane H et al. Mutation in WNT10A is associated with an autosomal recessive ectodermal dysplasia: the odonto-onycho-dermal dysplasia. *Am J Hum Genet* 2007;81:821–828.
5. Wang Y, Zhao H, Zhang X, Feng H. Novel identification of a four-base-pair deletion mutation in PITX2 in a Rieger syndrome family. *J Dent Res* 2003;82:1008–1012.
6. Tuna EB, Sulun T, Rosti O, El Abdallah F, Kayserili H, Aktoren O. Craniofacial manifestations in Hallermann-Streiff syndrome. *Cranio* 2009;27:33–38.
7. Zhang XX, Feng HL. Hallermann-Streiff syndrome: Two typical cases with dental treatment and primary aetiological investigation. *Chin J Dent Res* 2008;11:137–141.
8. Vastardis H, Karimbux N, Guthua SW, Seidman JG, Seidman CE. A human MSX1 homeodomain missense mutation causes selective tooth agenesis. *Nat Genet* 1996;13:417–421.
9. Stockton DW, Das P, Goldenberg M, D'Souza RN, Patel PI. Mutation of PAX9 is associated with oligodontia. *Nat Genet* 2000;24:18–19.
10. Song S, Han D, Qu H, et al. EDA gene mutations underlie non-syndromic oligodontia. *J Dent Res* 2009;88:126–131.
11. van den Boogaard MJ, Créton M, Bronkhorst Y, et al. Mutations in WNT10A are present in more than half of isolated hypodontia cases. *J Med Genet* 2012;49:327–331.
12. Wong S, Liu H, Bai B, et al. Novel missense mutations in the AXIN2 gene associated with non-syndromic oligodontia. *Arch Oral Biol* 2014;59:349–353.



13. Thesleff I. Genetic basis of tooth development and dental defects. *Acta Odontol Scand* 2000;58:191–194.
14. Worsaae N, Jensen BN, Holm B, Holsko J. Treatment of severe hypodontia-oligodontia--an interdisciplinary concept. *Int J Oral Maxillofac Surg* 2007;36:473–480.
15. Wang Y, Zhao H, Zhang X, Feng H. Mutation detection in ED1 gene in hypohidrotic ectodermal dysplasia (HED) families [in Chinese]. *Beijing Da Xue Xue Bao* 2003;35:419–422.
16. Järvinen S, Lehtinen L. Supernumerary and congenitally missing primary teeth in Finnish children. An epidemiologic study. *Acta Odontol Scand* 1981;39:83–86.
17. Whittington BR, Durward CS. Survey of anomalies in primary teeth and their correlation with the permanent dentition. *N Z Dent J* 1996;92:4–8.
18. Nik-Hussein NN, Abdul Majid Z. Dental anomalies in the primary dentition: distribution and correlation with the permanent dentition. *J Clin Pediatr Dent* 1996;21:15–19.
19. Zou D, Wu Y, Wang XD, Huang W, Zhang Z, Zhang Z. A retrospective 3- to 5-year study of the reconstruction of oral function using implant-supported prostheses in patients with hypohidrotic ectodermal dysplasia. *J Oral Implantol* 2014;40:571–580.
20. Dhima M, Salinas TJ, Cofer SA, Rieck KL. Rehabilitation of medically complex ectodermal dysplasia with novel surgical and prosthodontic protocols. *Int J Oral Maxillofac Surg* 2014;43:301–304.
21. Hosseini M, Worsaae N, Schjødt M, Gotfredsen K. A 3-year prospective study of implant-supported, single-tooth restorations of all-ceramic and metal-ceramic materials in patients with tooth agenesis. *Clin Oral Implants Res* 2013;24:1078–1087.
22. Hu XL, Li JH, Luo J, Qiu LX, Lin Y. Multidisciplinary management of congenitally missing teeth with osseointegrated dental implants: a long-term report. *Chin J Dent Res* 2011;14:29–36.
23. Singer SL, Henry PJ, Liddelow G, Rosenberg I. Long-term follow-up of implant treatment for oligodontia in an actively growing individual: a clinical report. *J Prosthet Dent* 2012;108:279–285.
24. Paulus C, Martin P. Hypodontia due to ectodermal dysplasia: rehabilitation with very early dental implants [in French]. *Rev Stomatol Chir Maxillofac Chir Orale* 2013;114:106–109.
25. Filius MA, Vissink A, Raghoebar GM, Visser A. Implant-retained overdentures for young children with severe oligodontia: a series of four cases. *J Oral Maxillofac Surg* 2014;72:1684–1690.
26. Toomarian L, Ardakani MR, Ramezani J, Adli AR, Tabari ZA. Using implants for prosthodontic rehabilitation of a 4-year-old with ectodermal dysplasia. *Gen Dent* 2014;62:e1–e5.
27. Cassi D, Di Blasio A, Gandolfini M. Determination of vertical dimension in prosthodontic rehabilitation of a growing patient with severe oligodontia. *Eur J Paediatr Dent* 2015;16:61–64.
28. Yap AK, Klineberg I. Dental implants in patients with ectodermal dysplasia and tooth agenesis: a critical review of the literature. *Int J Prosthodont* 2009;22:268–276.
29. Heuberger S, Dvorak G, Mayer C, Watzek G, Zechner W. Dental implants are a viable alternative for compensating oligodontia in adolescents. *Clin Oral Implants Res* 2015;26:e22–e27.
30. Kalsi JS, Hemmings K. The influence of patients' decisions on treatment planning in restorative dentistry. *Dent Update* 2013;40:698–700, 702–704, 707–708, 710.
31. Till MJ, Marques AP. Ectodermal dysplasia: treatment considerations and case reports. *Northwest Dent* 1992;71:25–28.
32. Nowak AJ. Dental treatment for patients with ectodermal dysplasias. *Birth Defects Orig Artic Ser* 1988;24:243–252.