

# Internal Organ Involvement in IgG4-related Sialadenitis: A Systemic Review

Xia HONG<sup>1</sup>, Wei LI<sup>1</sup>, Jia Zeng SU<sup>1</sup>, Zhen WANG<sup>1</sup>, Guang Yan YU<sup>1</sup>

**Objective:** To provide an overview of internal organ involvement (IOI) in immunoglobulin G4-related sialadenitis (IgG4-RS) patients, with a focus on the prevalence and clinical features of IOI, the analysis of serum IgG4 levels in patients with or without IOI, and the usefulness of positron emission tomography (PET) for examination of the whole body.

**Methods:** A systematic search was performed using PubMed, CNKI, Wanfang Data and CQVIP databases.

**Results:** A total of 99 articles, including 493 IgG4-RS cases, were analysed in this study. The male-to-female ratio was 1.57:1 and the mean age was 61.67 years. IOI was observed in 71.6% patients, including lesions of the pancreas (38.5%), the biliary system and liver (17.8%), distant lymphadenopathy (20.3%), the respiratory system (15.6%), the urinary system (12.0%) and retroperitoneal fibrosis (11.4%). The lesions could occur homeochronously or metachronously with IgG4-RS. The serum IgG4 levels in the IOI-positive and IOI-negative groups were  $1,131 \pm 952$  mg/dL and  $659 \pm 843$  mg/dL, respectively ( $P < 0.01$ ). The prevalence of IOI and the number of involved internal organs between the PET and the non-PET groups showed no significant difference ( $P = 0.399$  and  $P = 0.823$ , respectively), but were significantly higher in the PET group, amongst patients whose first symptom or chief complaint was salivary gland swelling ( $P = 0.002$  and  $P = 0.001$ , respectively).

**Conclusion:** IOI is common in IgG4-RS and almost every organ can be affected. High levels of serum IgG4 represent a potential indicator of IOI. Furthermore, PET is a useful tool for evaluation of the whole body.

**Key words:** IgG4-RD, IgG4-RS, internal organ involvement, serum IgG4 level, PET

Immunoglobulin G4-related disease (IgG4-RD) is a systemic immune-mediated disease that has recently attracted attention in many areas of medicine. It is characterised by dense lymphoplasmacytic infiltrates, storiform fibrosis and elevated serum IgG4 levels<sup>1</sup>. In 2001, Hamano et al first suggested a relationship between high serum IgG4 levels and sclerosing pancreatitis, but it was not until 2003 that Kamisawa et al identified extrapancreatic manifestations and classified it as a systemic disease<sup>2,3</sup>. To date, more than 40 different organs have been reported to be involved in IgG4-RD, and salivary gland

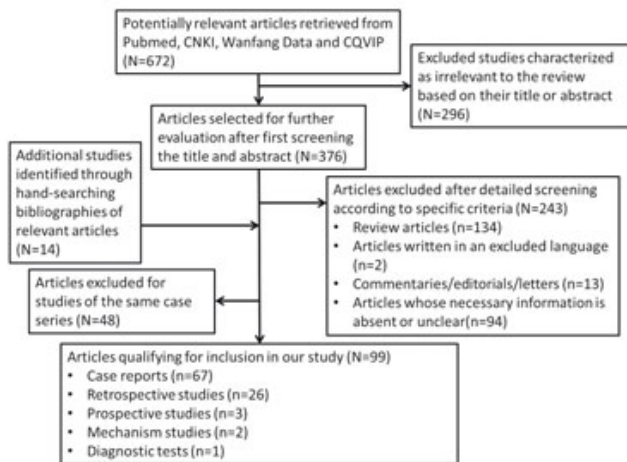
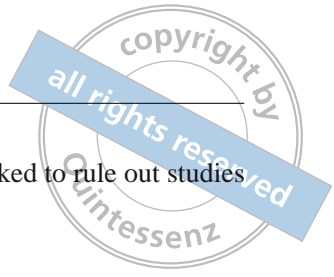involvement or IgG4-related sialadenitis (IgG4-RS), is amongst the most common types of lesions<sup>4</sup>.

IgG4-RS is characterised by the swelling of single or multiple salivary and/or lacrimal glands, with dysfunction of the involved glands<sup>5,6</sup>. Previously, we showed that comorbid diseases of IgG4-RS in the head and neck were rather common (data not shown). The involvement of internal organs has also been reported in many clinical studies and case reports<sup>4</sup>. However, the prevalence of internal organ involvement (IOI) and its relationship with IgG4-RS has remained unclear. Furthermore, the relationship between serum IgG4 levels and IOI is not yet fully understood. Positron emission tomography (PET) is a good way to carry out evaluations of the whole body, but its application and usefulness in IgG4-RD patients has been rarely reported<sup>7-12</sup>.

In this study, we collected and analysed all IgG4-RS patients reported in the English and Chinese literature

<sup>1</sup> Department of Oral and Maxillofacial Surgery, Peking University School and Hospital of Stomatology, Beijing, P.R. China.

**Corresponding author:** Dr Guang Yan YU, Department of Oral and Maxillofacial Surgery, Peking University School and Hospital of Stomatology, #22 Zhongguancun South Avenue, Haidian District, Beijing 100081, P.R.China. Tel: 86-10-62195245; Fax: 86-10-62173402; Email: gyyu@263.net



**Fig 1** A detailed flow chart of the process for selecting articles for inclusion in our review.

to 1) characterise the prevalence and clinical features of IOI in IgG4-RS patients; 2) analyse serum IgG4 levels in patients with or without IOI, and 3) evaluate the usefulness of PET in examining the whole body for IgG4-RD.

**Methods**

*Data sources*

Systematic searches were performed in the Pubmed database (Jan 12 2015) for articles written in English, and in the China Knowledge Resource Integrated Database (CNKI), Wanfang Data and Chongqing VIP Information (CQVIP) databases (Jan 13, 2015) for articles written in Chinese. The strategy used for all database searches included a combination of the keywords ‘salivary gland’ OR ‘parotid gland’ OR ‘submandibular gland’ OR ‘Mikulicz’s disease’ OR ‘Küttner’s tumour’ OR ‘sialadenitis’ AND ‘IgG4’. The reference lists of the articles that were identified were also searched.

*Study selection*

Publications referring to data on IgG4-RS with or without IOI were considered to be eligible for inclusion in this review. Only studies written in English or Chinese were included. Reviews, conference papers, letters to the editor, short surveys and commentaries were excluded from our analysis. Studies with information regarding IOI that were unclear were excluded. Articles from the

same research group were rechecked to rule out studies of the same case series.

*Clinical data accumulation*

The major characteristics of the included studies (study design, number of patients, patient age and gender, conditions of IOI, medical history, serological examinations and the application of PET) were recorded.

*Statistical analysis*

Continuous variables were presented as means ± standard deviation; categorical variables were expressed as numbers and percentages. Continuous variables in the two groups that followed a normal distribution were compared using Student’s t-test, while those that did not exhibit a normal distribution were compared using the Mann–Whitney U test. Dichotomous variables in the two groups were compared using the chi-square test. Instances where *P* < 0.05 were considered to indicate statistically significant differences. Analyses were performed using SPSS version 20.0 (SPSS, Chicago, Illinois, USA).

**Results**

A total of 99 articles, including 87 English and 12 Chinese articles, were included in this study. The process for article selection is shown in Figure 1.

Most of these articles were published by authors from Asia (n = 72), followed by authors from North America (n = 13), Europe (n = 11), Oceania (n = 2), and South America (n = 1). Amongst them, Japanese authors contributed 49 papers. Except for 67 articles that were case reports, 12 of the remaining 32 articles mainly focused on IgG4-RS, while the other 20 were studies of IOI with salivary gland involvement.

Overall, 493 IgG4-RS patients were included in this study. Amongst them, 295 were men and 188 were women (the male-to-female ratio was 1.57:1; the genders of 10 patients were unclear). There were much more men than women. The mean patient age was 61.67 years (range: 11 to 89 years). IOI was observed in 353 patients (71.6%), including lesions of the pancreas, biliary system and liver, distant lymphadenopathy, respiratory system, urinary system, retroperitoneal fibrosis and so on (Table 1). The number of involved internal organs was clear for 412 patients, and an investigation of these cases showed that IOI could be detected in 306 patients (74.3%), including one internal organ in 118 cases (28.6%), two internal organs in 92 cases (22.3%),

**Table 1** IOI of IgG4-RS and its prevalence.

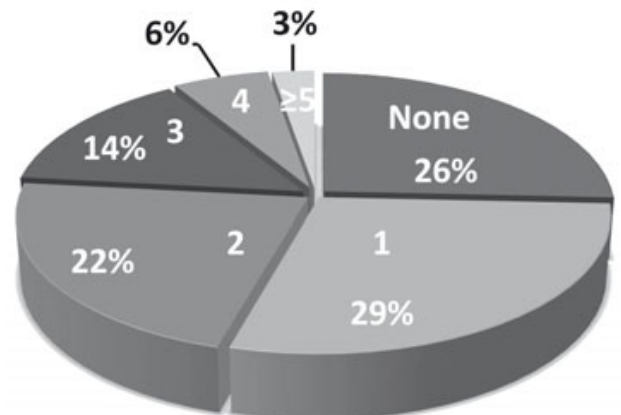
| Involved Organs                      | No. of cases | Prevalence (%) | References   |
|--------------------------------------|--------------|----------------|--|
| IOI                                  | 353          | 71.6           | 7-105  |
| AIP                                  | 190          | 38.5           | 7,8,10-12,14-18,20-28,32,33,37,39,41,44,46,48-52,57-60,62,64-66,69,71,76-78,80-84,88,91-93,95-103,105                  |
| Biliary system and liver involvement | 88           | 17.8           | 8,11,12,14,16-18,20,21,23,24,27,32,46,48-52,55,60,62,65,66,68,69,71,77,78,83,91,95-97,100                              |
| Distant lymphadenopathy              | 100          | 20.3           | 8-11,14,18,19,23,24,26,27,29,34,35,37,43-45,48,52,53,55,58,63,64,66,67,70-73,75,77,80,84,86,88,93,94,96,98-102,104,105 |
| Respiratory system involvement       | 77           | 15.6           | 7-10,12,15,18,24,26,33,37,44,46,49,52,58,60,62-65,67,69,70,72,73,78,81,84,88,91,93,94,96,99,101,102,104                |
| Urinary system involvement           | 59           | 12.0           | 7-9,12,16,18,22,27,30,31,33,34,37,44,52,55,58,59,62,64,69,72,74,76-78,81,83,84,90,91,93,100,105                        |
| Retroperitoneal fibrosis             | 56           | 11.4           | 7,8,10,15,19,26,41,44,47-49,53,55,64,71,77,81,84,85,89,91,94   |
| Prostate involvement                 | 30           | 6.1            | 7,8,11,21,24,50,52,65,69,76,84,88,90,91,101  |
| Cardiovascular involvement           | 28           | 5.7            | 7-9,11,41,52,57,58,60,65,66,70,74,84,86  |
| Hypophysitis                         | 9            | 1.8            | 7,10,12,19,26,46,64,65,74  |
| Meninges involvement                 | 7            | 1.4            | 10,38,63,65,74,91  |
| Gastrointestinal tract involvement   | 4            | 0.8            | 25,75,91   |
| Spleen involvement                   | 3            | 0.6            | 8,9,24   |
| Breast involvement                   | 3            | 0.6            | 7,65   |

IOI: Internal organ involvement  
AIP: Autoimmune pancreatitis

three internal organs in 60 cases (14.6%), four internal organs in 25 cases (6.1%) and five or more internal organ lesions in 11 cases (2.7%) (Fig 2).

**Autoimmune pancreatitis (AIP)**

AIP was the most common lesion that was reported for 190 IgG4-RS patients with a prevalence of 38.5%. The symptoms related to pancreatitis were the chief complaint for 70 of 107 patients, while the chief complaint of the other 83 patients was not clear. The main symptoms were jaundice in 21 patients, abdominal pain in eight patients, and weight loss or loss of appetite in six patients. Additionally, 44 patients with no symptoms were found to have AIP during subsequent examinations. The course of disease was clearly reported in 74 patients. This included 17 patients who suffered AIP prior to swelling of the salivary glands with the longest



**Fig 2** The number of involved internal organs in IgG4-RS patients. IOI was detected in 74.3% of patients. Specifically, one IOI lesion in 28.6% of cases; two IOI lesions in 22.3% of cases; three IOI lesions in 14.6% of cases; four IOI lesions in 6.1% of cases; and five or more IOI lesions in 2.7% of cases were detected.

time interval being 10 years. Additionally, 38 patients were found to have AIP and IgG4-RS almost simultaneously and another 19 patients turned to doctors because of AIP, following the appearance of salivary gland swelling, with the longest time interval being 15 years. The main radiological characteristics of AIP were occupying lesions in 13 patients, localised or diffuse swelling of the pancreas in 46 patients and an abnormality of the pancreatic ducts in 12 patients.

#### *Biliary system and liver involvement*

Biliary system and liver involvement was reported in 88 cases (17.8%), including 78 cases that were combined with AIP. A total of 12 patients were found to have biliary system and liver involvement at the first visit. Based on the detailed medical history of 17 patients, biliary system and liver involvement occurred prior to IgG4-RS in two patients, at the same time in eight cases, and after enlargement of the salivary glands in seven patients with the longest time interval being 2 years. Based on endoscopic retrograde cholangiopancreatography (ERCP) or other radiological examinations, involvement of the bile duct or sclerosing cholangitis, was the most common lesion, which could be observed in 71 patients. Other lesions, including involvement of the gall bladder ( $n = 6$ ) and liver ( $n = 7$ ), were also reported.

#### *Distant lymphadenopathy*

Distant lymphadenopathy was fairly common and reported in 100 patients (20.3%). Swelling of the axillary, hilar/mediastinal, abdominal and inguinal lymph nodes was observed in 15, 74, 15, and 13 patients, respectively. There were 46 patients who were found to have distant lymphadenopathy at the first visit. A study of 46 patients, who were able to provide a detailed medical history, showed that distant lymphadenopathy could present prior to ( $n = 6$ ), concurrent with ( $n = 23$ ) or after ( $n = 17$ ) the appearance of IgG4-RS.

#### *Respiratory system involvement*

Lesions of the lungs and bronchi affected 77 IgG4-RS patients (15.6%); this was the chief complaint of 13 patients, with the symptom of cough exhibited in 10 patients and dyspnea observed in eight cases. An investigation of 21 IgG4-RS patients with a clear medical history showed that lung involvement occurred prior to, concurrent with, or after salivary gland swelling in two, eight and 11 patients, respectively. The lung manifestations could be masses or inflammatory pseudotumours

( $n = 15$ ), interstitial pneumonia or consolidation ( $n = 19$ ), or multiple nodules ( $n = 2$ ). Bronchi involvement was observed in eight patients that manifested as thickness of the bronchi walls or abnormal intake values in PET. Thickness of the pleura occurred in nine patients and was combined with pleural effusion in one patient.

#### *Urinary system involvement*

The involvement of the urinary system occurred in 59 cases (12.0%); this was the chief complaint of four patients and was observed on the first visit in 10 patients. There were two out of 20 cases who reported urinary system involvement prior to IgG4-RS, eight cases that occurred homeochronously, and 10 cases that showed an abnormality of the urinary system after salivary gland swelling, with the longest time interval being 8 years. Interstitial nephritis was the most common lesion, which affected 11 patients, including four who also suffered from chronic renal failure. There were six patients with occupying lesions of the kidney. Increased thickness of the pelvis, ureter, or bladder was observed in five patients.

#### *Retroperitoneal fibrosis*

Retroperitoneal fibrosis was observed in 56 cases (11.4%) and was recorded as the chief complaint in five patients. Retroperitoneal masses were located around the pelvis or ureter in 10 patients, and around the abdominal aorta or iliac artery in eight patients. Different degrees of secondary hydronephrosis were observed in 10 cases.

#### *Involvement of other organs*

The involvement of the prostate was observed in 30 patients. Cardiovascular involvement occurred in 28 patients. Specifically, 28 patients showed complications of periaortitis, including two patients with perivascular soft tissue of the coronary artery, seven patients who were reported to have pericardium involvement, and pericardial effusion in one patient. Another patient was reported to have multiple aneurysms and died of an aneurysm rupture with a pathological confirmation of IgG4-related disease. Furthermore, nine IgG4-RS patients also suffered hypophysitis. Involvement of other organs, including the meninges, gastrointestinal tract, spleen, and breast, were occasionally reported in seven, four, three and three patients, respectively.

### Serum IgG4 levels

The serum levels of IgG4 were reported at the time of diagnosis in 383 cases, including in 250 cases for which individual patient values were available and in the form of mean  $\pm$  standard deviation in two studies that contained 133 cases. Elevated levels of serum IgG4 were observed in 372 patients (97.4%). We divided patients into groups based on the presence or absence of IOI, and compared levels of serum IgG4 between the two groups. The IOI-positive group included 286 patients (74.7%), while the IOI-negative group included 97 patients (25.3%). The mean levels of serum IgG in the IOI-positive group ( $1,131 \pm 952$  mg/dL) were much higher than those in the IOI-negative group ( $659 \pm 843$  mg/dL;  $P < 0.01$ ). A comparison of the 220 IOI-positive cases with precisely reported serum IgG4 levels also revealed that the mean serum IgG4 levels of the 71 individuals with three or more IOI lesions ( $1,509 \pm 1,166$  mg/dL) were much higher than those in the 149 cases with only one or two IOI lesions ( $1,094 \pm 899$  mg/dL,  $P < 0.01$ ).

### Evaluation of PET

PET was performed in 145 cases which were described in 22 articles. After excluding papers that did not describe whether PET was performed in each individual or the detailed condition of IOI, we included 390 cases and divided them into the PET group or the non-PET group based on whether the patient received a PET examination. We found that PET was performed in 132 patients (33.8%). No significant difference was observed between the groups for the prevalence of IOI ( $P = 0.399$ ) and involved internal organs ( $P = 0.823$ ). A comparison of different involved organs revealed that the detection rate of retroperitoneal fibrosis, prostate involvement and cardiovascular involvement in the PET group were significantly higher than those of the non-PET group ( $P = 0.003$ ,  $P < 0.001$  and  $P = 0.002$ , respectively). However, the detection rate of AIP, biliary system and liver involvement, and distant lymphadenopathy in the PET group were significantly lower than those of the non-PET group ( $P = 0.002$ ,  $P = 0.002$  and  $P = 0.007$ , respectively). The detection rates of respiratory and urinary system involvement of the two groups were not significantly different ( $P = 0.543$  and  $P = 0.074$ , respectively). Further analysis of the 130 cases with clear descriptions of the first symptom or chief complaint being swelling of the salivary glands showed that PET was performed in 36 patients (27.7%). Unlike the aforementioned results, the prevalence of IOI and the number of involved internal organs were significantly

higher in the PET group than in the non-PET group ( $P = 0.002$  and  $P = 0.001$ , respectively). A comparison of the different involved organs showed that the detection rate of retroperitoneal fibrosis, prostate involvement, cardiovascular involvement, and respiratory system involvement in the PET group were all significantly higher than those in the non-PET group ( $P = 0.007$ ,  $P = 0.001$ ,  $P < 0.001$  and  $P < 0.001$ , respectively). No significant difference was observed for the detection rate of AIP, biliary system and liver involvement, distant lymphadenopathy, or urinary system involvement ( $P = 0.156$ ,  $P = 0.181$ ,  $P = 0.363$ , and  $P = 0.403$ , respectively). Detailed results are listed in Table 2.

### Discussion

IgG4-RS is a newly recognised autoimmune disease that mostly affects Asian individuals, especially those of Japanese descent<sup>4</sup>. Its pathogenesis is unclear, and to the best of our knowledge, this phenomenon may be associated with the initial identification of IgG4-RD in Japan. The epidemiological features of IgG4-RS have not yet been definitively described. However, according to a nationwide survey conducted in Japan, there are approximately 8000 patients with IgG4-RD and about 4300 patients with IgG4-RS<sup>106</sup>. Unlike Sjögren syndrome, male patients are more frequently affected than female patients<sup>107,108</sup>. The mean age at diagnosis was 61.67 years, and ranged from 11 to 89 years old<sup>43,61</sup>.

The features of IgG-RS have been studied in detail and, to avoid unnecessary invasive treatments, it is important for oral and maxillofacial surgeons to distinguish this disease from tumours and other inflammatory diseases<sup>69,109,110</sup>. It is also important to consider this systemic disease from the perspective of the whole body. According to our study, IOI occurred in 71.6% of patients, which represents nearly three quarters of IgG4-RS patients combined with IOI, although they can sometimes be asymptomatic. So, once a diagnosis of IgG4-RS is made, it is necessary to perform an evaluation of the whole body to obtain a full view of the general condition of the patient. Moreover, histories of AIP, sclerosing cholangitis, interstitial pneumonia, interstitial nephritis, and retroperitoneal fibrosis are all potential indicators of this systemic disease when patients arrive at the clinic, presenting for salivary gland swelling alone.

AIP has been regarded as the most common lesion of IgG4-RD<sup>2,106</sup>. It is also the most common IOI in IgG4-RS patients, occurring in 38.5% of cases according to our study. This can occur either homeochronously or metachronously with IgG4-RS. Its symptoms include



**Table 2** Detection rate of IOI in the PET and the non-PET groups.

|                                      | Without concern for the first symptom or chief complaint (n = 390) |                             |         | Concerning salivary glands swelling as the first symptom or chief complaint (n = 130) |                            |         |
|--------------------------------------|--|-----------------------------|---------|---|----------------------------|---------|
|                                      | PET group (n = 132) (%)  | Non-PET group (n = 258) (%) | P-value | PET group (n = 36) (%)  | Non-PET group (n = 94) (%) | P-value |
| IOI                                  | 98 (74.2)  | 196 (76.0)                  | 0.399   | 30 (83.3)   | 52 (55.3)                  | 0.002   |
| AIP                                  | 43 (32.6)  | 125 (48.4)                  | 0.002   | 18 (50.0)   | 36 (38.3)                  | 0.156   |
| Biliary system and liver involvement | 15 (11.4)  | 61 (23.6)                   | 0.002   | 11 (30.6)   | 20 (21.3)                  | 0.181   |
| Distant lymphadenopathy              | 21 (15.9)  | 71 (27.5)                   | 0.007   | 10 (27.8)   | 31 (33.0)                  | 0.363   |
| Respiratory system involvement       | 29 (22.0)  | 57 (22.1)                   | 0.543   | 16 (44.4)   | 5 (5.3)                    | < 0.001 |
| Urinary system involvement           | 9 (6.8)  | 31 (12.0)                   | 0.074   | 5 (13.9)  | 10 (10.6)                  | 0.403   |
| Retroperitoneal fibrosis             | 27 (20.5)  | 25 (9.7)                    | 0.003   | 10 (27.8)   | 8 (8.5)                    | 0.007   |
| Prostate involvement                 | 18 (13.6)  | 9 (3.5)                     | < 0.001 | 7 (19.4)  | 1 (1.1)                    | 0.001   |
| Cardiovascular Involvement           | 17 (12.9)  | 11 (4.3)                    | 0.002   | 10 (27.8)   | 1 (1.1)                    | < 0.001 |

IOI: Internal organ involvement; AIP: Autoimmune pancreatitis

jaundice, abdominal pain, weight loss, and anorexia in the IgG4-RS cases that were included. Other symptoms, such as pruritus and steatorrhea, were also reported in AIP studies<sup>111</sup>. Ultrasonography, computed tomography (CT), magnetic resonance (MR), PET and ERCP can all be used for the diagnosis and evaluation of AIP<sup>112</sup>. Importantly, pancreatic cancer should be differentiated when the lesion appears as a mass<sup>112</sup>. Involvement of the biliary system and liver is also frequently observed in IgG4-RD and often occurs along with AIP<sup>113</sup>. Sclerosing cholangitis, which can manifest with increased thickness of the bile duct wall, stenosis of the duct, and dilatation of the distal or intrahepatic bile duct, is the most common lesion<sup>23</sup>.

Lymphadenopathy is common in IgG4-RS patients. Previously, we have shown that almost 80% of cases occurred simultaneously with cervical lymphadenopathy (data not shown). However, distant lymphadenopathy can also be observed and was observed in 20.3% of cases in our study. Its actual prevalence could be higher because of the low detection rate using a chest radiograph. Lymph nodes of the hilum and mediastinum were the most frequently affected<sup>23,58</sup>. Diseases such as lymphoma and sarcoidosis should be excluded during diagnosis.

Involvement of the respiratory and urinary systems can often be observed in IgG4-RD patients and, in our

study of IgG4-RS cases, the prevalence was 15.2% and 8.7%, respectively. Interstitial tissue involvement of the lung or kidney is the most common lesion, which can potentially cause respiratory or renal failure<sup>26,27</sup>. A inflammatory pseudotumour is another common lesion that should be differentiated from malignant tumours. When involvement of the respiratory or urinary tract occurs, it sometimes appears as increased tract wall thickness<sup>31,64</sup>.

Retroperitoneal fibrosis is a periaortic sclerotic disease that encases adjacent retroperitoneal structures, particularly the ureters, and this could cause obstruction of the urinary tracts along with secondary hydronephrosis<sup>114</sup>. Cardiovascular involvement occasionally occurs and could potentially cause sudden death, or a condition in which surgical intervention may be necessary<sup>60</sup>.

Based on an analysis of the clinical course of IgG4-RS patients, we concluded that all IOI lesions can either precede, coexist with, or follow swelling of the salivary glands. The time interval between IgG4-RS and IOI could be as long as 10 years, or potentially greater<sup>23</sup>. Therefore it is assumed that the longer the medical history is, the greater the chance of IOI. A retrospective study of the natural clinical history and histopathological characteristics of IgG4-RS showed that the amount of salivary secretion decreased along with histological changes and delayed therapeutic intervention<sup>115</sup>.

Therefore, we suggest that early intervention is needed to avoid further IOI and to improve outcomes in IgG4-RS patients.

Based on the comprehensive diagnosis criteria for IgG4-RD published by Umehara et al, elevated serum IgG4 levels is an important, but not a prerequisite criterion for IgG4-RD<sup>116</sup>. Although some IgG4-RD patients were found to have normal serum IgG4 levels, several studies also reported higher serum IgG4 levels in the multiple organ involvement group compared with those in the single organ involvement group<sup>7,113</sup>. In this present study, we compared serum IgG4 levels in the IOI-positive and IOI-negative groups and obtained results that were consistent with those of previous studies, suggesting that serum IgG4 level is a potential predictor of IOI. The serum IgG4 levels of patients with three or more IOI lesions were also higher than those with one or two IOI lesions. Although no clear conclusion has been reached concerning whether serum IgG4 levels reflect the activity of IgG4-RS, we could at least presume that the higher the IgG4 level is, the more probable that a patient suffers from IOI and therefore more attention should be paid to monitoring IOI.

Irrespective of economic factors, PET is a good way to acquire images of the whole body and obtain functional information about disease activity<sup>117</sup>. A prospective cohort study carried out in 35 patients with IgG4-RD showed that 71.4% of patients were found with more organ involvement by PET than by conventional evaluations, including physical examination, ultrasonography, and CT, especially in arteries and lymph nodes<sup>8</sup>. It is also a useful tool to evaluate the response of a patient to steroid therapy<sup>11</sup>. In our present study, although no significant differences with regard to the prevalence of IOI and the overall number of involved internal organs were observed between the PET and the non-PET groups, PET was able to detect more IOI lesions than traditional methods regarding the enlargement of salivary glands as the first symptom or chief complaint. One probable reason is that the degree of IOI might be minimal and relatively difficult to detect in patients whose first symptom or chief complaint is salivary gland swelling, while patients with obvious internal organ dysfunctions were easier to identify with IOI, even by some traditional methods that have lower sensitivity. Our results also suggested the great advantages of PET in detecting retroperitoneal fibrosis, prostate involvement and cardiovascular involvement, most of which were asymptomatic. Considering all of our results, we suggest that PET has a higher sensitivity for detecting asymptomatic or early-stage lesions com-

pared with traditional methods. However, the possibility of false-negative evaluation results of small-sized lesions and brain or kidney contiguous lesions, should be considered<sup>10,12</sup>.

## Conclusions

IgG4-RS is a systemic disease and IOI is frequently reported. Almost any organ could be affected by IgG4-RS and the involvement of the pancreas, biliary system and liver, respiratory system and urinary system, as well as retroperitoneal fibrosis and distant lymphadenopathy are common. All IOI lesions can occur homeochronously or metachronously with IgG4-RS and early intervention is necessary. A high level of serum IgG4 is a potential indicator of IOI. PET potentially has a higher sensitivity for detecting asymptomatic or early-stage lesions compared with traditional methods and represents a useful tool for evaluations of the whole body.

## References

1. Stone JH, Zen Y, Deshpande V. IgG4-related disease. *N Engl J Med* 2012;366:539–551.
2. Hamano H, Kawa S, Horiuchi A et al. High serum IgG4 concentrations in patients with sclerosing pancreatitis. *N Engl J Med* 2001;344:732–738.
3. Kamisawa T, Funata N, Hayashi Y et al. A new clinicopathological entity of IgG4-related autoimmune disease. *J Gastroenterol* 2003;38:982–984.
4. Brito-Zeron P, Ramos-Casals M, Bosch X, Stone JH. The clinical spectrum of IgG4-related disease. *Autoimmun Rev* 2014;13:1203–1210.
5. Ferry JA, Deshpande V. IgG4-related disease in the head and neck. *Semin Diagn Pathol* 2012;29:235–244.
6. Bhatti RM, Stelow EB. IgG4-related disease of the head and neck. *Adv Anat Pathol* 2013;20:10–16.
7. Yamamoto M, Yajima H, Takahashi H et al. Everyday clinical practice in IgG4-related dacryoadenitis and/or sialadenitis: Results from the SMART database. *Mod Rheumatol* 2015;25:199–204.
8. Zhang J, Chen H, Ma Y et al. Characterizing IgG4-related disease with <sup>18</sup>F-FDG PET/CT: a prospective cohort study. *Eur J Nucl Med Mol Imaging* 2014;41:1624–1634.
9. Taniguchi Y, Ogata K, Inoue K, Terada Y. Clinical implication of FDG-PET/CT in monitoring disease activity in IgG4-related disease. *Rheumatology (Oxford)* 2013;52:1508.
10. Takahashi H, Yamashita H, Morooka M et al. The utility of FDG-PET/CT and other imaging techniques in the evaluation of IgG4-related disease. *Joint Bone Spine* 2014;81:331–336.
11. Matsubayashi H, Furukawa H, Maeda A et al. Usefulness of positron emission tomography in the evaluation of distribution and activity of systemic lesions associated with autoimmune pancreatitis. *Pancreatology* 2009;9:694–699.
12. Ebbo M, Grados A, Guedj E et al. Usefulness of 2-[18F]-fluoro-2-deoxy-D-glucose-positron emission tomography/computed tomography for staging and evaluation of treatment response in IgG4-related disease: a retrospective multicenter study. *Arthritis Care Res (Hoboken)* 2014;66:86–96.
13. Saegusa H, Momose M, Kawa S et al. Hilar and pancreatic gallium-67 accumulation is characteristic feature of autoimmune pancreatitis. *Pancreas* 2003;27:20–25.



14. Pickartz T, Pickartz H, Lochs H, Ockenga J. Overlap syndrome of autoimmune pancreatitis and cholangitis associated with secondary Sjogren's syndrome. *Eur J Gastroenterol Hepatol* 2004;16:1295–1299.
15. van der Vliet HJ, Perenboom RM. Multiple pseudotumors in IgG4-associated multifocal systemic fibrosis. *Ann Intern Med* 2004;141:896–897.
16. Taguchi M, Aridome G, Abe S et al. Autoimmune pancreatitis with IgG4-positive plasma cell infiltration in salivary glands and biliary tract. *World J Gastroenterol* 2005;11:5577–5581.
17. Aoki S, Nakazawa T, Ohara H et al. Immunohistochemical study of autoimmune pancreatitis using anti-IgG4 antibody and patients' sera. *Histopathology* 2005;47:147–158.
18. Deshpande V, Chicano S, Finkelberg D et al. Autoimmune pancreatitis: a systemic immune complex mediated disease. *Am J Surg Pathol* 2006;30:1537–1545.
19. Tanabe T, Tsushima K, Yasuo M et al. IgG4-associated multifocal systemic fibrosis complicating sclerosing sialadenitis, hypophysitis, and retroperitoneal fibrosis, but lacking pancreatic involvement. *Intern Med* 2006;45:1243–1247.
20. Nishino T, Toki F, Oyama H, Shimizu K, Shiratori K. Long-term outcome of autoimmune pancreatitis after oral prednisolone therapy. *Intern Med* 2006;45:497–501.
21. Yoshimura Y, Takeda S, Ieki Y, Takazakura E, Koizumi H, Takagawa K. IgG4-associated prostatitis complicating autoimmune pancreatitis. *Intern Med* 2006;45:897–901.
22. Saeki T, Saito A, Hiura T et al. Lymphoplasmacytic infiltration of multiple organs with immunoreactivity for IgG4: IgG4-related systemic disease. *Intern Med* 2006;45:163–167.
23. Hamano H, Arakura N, Muraki T, Ozaki Y, Kiyosawa K, Kawa S. Prevalence and distribution of extrapancreatic lesions complicating autoimmune pancreatitis. *J Gastroenterol* 2006;41:1197–1205.
24. Hamed G, Tsushima K, Yasuo M et al. Inflammatory lesions of the lung, submandibular gland, bile duct and prostate in a patient with IgG4-associated multifocal systemic fibrosclerosis. *Respirology* 2007;12:455–457.
25. Deheragoda MG, Church NI, Rodriguez-Justo M et al. The use of immunoglobulin G4 immunostaining in diagnosing pancreatic and extrapancreatic involvement in autoimmune pancreatitis. *Clin Gastroenterol Hepatol* 2007;5:1229–1234.
26. Tsuboi H, Inokuma S, Setoguchi K et al. Inflammatory pseudotumors in multiple organs associated with elevated serum IgG4 level: recovery by only a small replacement dose of steroid. *Intern Med* 2008;47:1139–1142.
27. Sato M, Okumura T, Shioyama Y, Imura J. Extrapancreatic F-18 FDG accumulation in autoimmune pancreatitis. *Ann Nucl Med* 2008;22:215–219.
28. Kojima M, Miyawaki S, Takada S et al. Lymphoplasmacytic infiltrate of regional lymph nodes in Kuttner's tumor (chronic sclerosing sialadenitis): a report of 3 cases. *Int J Surg Pathol* 2008;16:263–268.
29. Cheuk W, Yuen HK, Chu SY, Chiu EK, Lam LK, Chan JK. Lymphadenopathy of IgG4-related sclerosing disease. *Am J Surg Pathol* 2008;32:671–681.
30. Aoki A, Sato K, Itabashi M et al. A case of Mikulicz's disease complicated with severe interstitial nephritis associated with IgG4. *Clin Exp Nephrol* 2009;13:367–372.
31. Kuroda N, Nakamura S, Miyazaki K et al. Chronic sclerosing pyelitis with an increased number of IgG4-positive plasma cells. *Med Mol Morphol* 2009;42:236–238.
32. Kudo-Tanaka E, Nakatsuka S, Hirano T et al. A case of Mikulicz's disease with Th2-biased cytokine profile: possible feature discriminable from Sjogren's syndrome. *Mod Rheumatol* 2009;19:691–695.
33. Takahashi N, Ghazale AH, Smyrk TC, Mandrekar JN, Chari ST. Possible association between IgG4-associated systemic disease with or without autoimmune pancreatitis and non-Hodgkin lymphoma. *Pancreas* 2009;38:523–526.
34. Cheuk W, Lee KC, Chong LY, Yuen ST, Chan JK. IgG4-related Sclerosing disease: a potential new etiology of cutaneous pseudolymphoma. *Am J Surg Pathol* 2009;33:1713–1719.
35. Gill J, Angelo N, Yeong ML, McIvor N. Salivary duct carcinoma arising in IgG4-related autoimmune disease of the parotid gland. *Hum Pathol* 2009;40:881–886.
36. Ishida M, Hotta M, Kushima R, Shibayama M, Shimizu T, Okabe H. Multiple IgG4-related sclerosing lesions in the maxillary sinus, parotid gland and nasal septum. *Pathol Int* 2009;59:670–675.
37. Dhobale S, Bedetti C, Killian P et al. IgG4 related sclerosing disease with multiple organ involvements and response to corticosteroid treatment. *J Clin Rheumatol* 2009;15:354–357.
38. Chan SK, Cheuk W, Chan KT, Chan JK. IgG4-related sclerosing pachymeningitis: a previously unrecognized form of central nervous system involvement in IgG4-related sclerosing disease. *Am J Surg Pathol* 2009;33:1249–1252.
39. Abe T, Sato T, Tomaru Y et al. Immunoglobulin G4-related sclerosing sialadenitis: report of two cases and review of the literature. *Oral Surg Oral Med Oral Pathol Oral Radiol Endod* 2009;108:544–550.
40. Stone JH, Caruso PA, Deshpande V. Case records of the Massachusetts General Hospital. Case 24-2009. A 26-year-old woman with painful swelling of the neck. *N Engl J Med* 2009;361:511–518.
41. Suga K, Kawakami Y, Hiyama A, Hori K, Takeuchi M. F-18 FDG PET-CT findings in Mikulicz disease and systemic involvement of IgG4-related lesions. *Clin Nucl Med* 2009;34:164–167.
42. Jakobiec FA, Stacy RC, Mehta M, Fay A. IgG4-positive dacryoadenitis and Kuttner submandibular sclerosing inflammatory tumor. *Arch Ophthalmol* 2010;128:942–944.
43. Cheuk W, Tam FK, Chan AN et al. Idiopathic cervical fibrosis--a new member of IgG4-related sclerosing diseases: report of 4 cases, 1 complicated by composite lymphoma. *Am J Surg Pathol* 2010;34:1678–1685.
44. Geyer JT, Ferry JA, Harris NL et al. Chronic sclerosing sialadenitis (Kuttner tumor) is an IgG4-associated disease. *Am J Surg Pathol* 2010;34:202–210.
45. Kubota T, Moritani S, Katayama M, Terasaki H. Ocular adnexal IgG4-related lymphoplasmacytic infiltrative disorder. *Arch Ophthalmol* 2010;128:577–584.
46. Hori M, Makita N, Andoh T et al. Long-term clinical course of IgG4-related systemic disease accompanied by hypophysitis. *Endocr J* 2010;57:485–492.
47. Nagai K, Andoh K, Ogata A et al. A new category for chronic sclerosing sialadenitis as an IgG4 related syndrome. *BMJ Case Rep* 2010;2010.
48. Kubota K, Wada T, Kato S et al. Highly active state of autoimmune pancreatitis with mikulicz disease. *Pancreas* 2010;39:e6–e10.
49. Moteki H, Yasuo M, Hamano H, Uehara T, Usami S. IgG4-related chronic rhinosinusitis: a new clinical entity of nasal disease. *Acta Otolaryngol* 2011;131:518–526.
50. Ng TL, Leong IS, Tang WL et al. Immunoglobulin G4-related sclerosing disease: experience with this novel entity in a local hospital. *Hong Kong Med J* 2011;17:280–285.
51. Takuma K, Kamisawa T, Tabata T et al. Visual field deficit: a rare initial symptom of autoimmune pancreatitis. *Intern Med* 2011;50:887–891.
52. Nguyen VX, De Petris G, Nguyen BD. Usefulness of PET/CT imaging in systemic IgG4-related sclerosing disease. A report of three cases. *JOP* 2011;12:297–305.
53. Hsu BB, Lai NS, Tung CH. Clinical images: lacrimal gland and renal involvement in IgG4-related sclerosing disease. *Arthritis Rheum* 2011;63:3875.
54. Kakuchi Y, Yamada K, Suzuki Y et al. IgG4-related skin lesions in a patient with IgG4-related chronic sclerosing dacryoadenitis and sialoadenitis. *Intern Med* 2011;50:1465–1469.



55. Zaidan M, Cervera-Pierot P, de Seigneux S et al. Evidence of follicular T-cell implication in a case of IgG4-related systemic disease with interstitial nephritis. *Nephrol Dial Transplant* 2011;26:2047–2050.
56. Suzuki M, Mizumachi T, Morita S, Kubota K, Lizuka K. A case of immunoglobulin 4-related disease with bilateral mass-forming lesions in the nasolacrimal ducts. *J Clin Rheumatol* 2011;17:207–210.
57. Ikutomi M, Matsumura T, Iwata H et al. Giant tumorous lesions (correction of legions) surrounding the right coronary artery associated with immunoglobulin-G4-related systemic disease. *Cardiology* 2011;120:22–26.
58. Ishii S, Shishido F, Miyajima M, Sakuma K, Shigihara T, Kikuchi K. Whole-body gallium-67 scintigraphic findings in IgG4-related disease. *Clin Nucl Med* 2011;36:542–545.
59. Cravedi P, Abbate M, Gagliardini E et al. Membranous nephropathy associated with IgG4-related disease. *Am J Kidney Dis* 2011;58:272–275.
60. Takei H, Nagasawa H, Sakai R et al. A case of multiple giant coronary aneurysms and abdominal aortic aneurysm coexisting with IgG4-related disease. *Intern Med* 2012;51:963–967.
61. Melo JC, Kitsko D, Reyes-Mugica M. Pediatric chronic sclerosing sialadenitis: Kuttner tumor. *Pediatr Dev Pathol* 2012;15:165–169.
62. Maehara T, Moriyama M, Nakashima H et al. Interleukin-21 contributes to germinal centre formation and immunoglobulin G4 production in IgG4-related dacryoadenitis and sialoadenitis, so-called Mikulicz's disease. *Ann Rheum Dis* 2012;71:2011–2019.
63. Yamashita H, Takahashi Y, Ishiura H, Kano T, Kaneko H, Mimori A. Hypertrophic pachymeningitis and tracheobronchial stenosis in IgG4-related disease: case presentation and literature review. *Intern Med* 2012;51:935–941.
64. Matsui S, Taki H, Shinoda K et al. Respiratory involvement in IgG4-related Mikulicz's disease. *Mod Rheumatol* 2012;22:31–39.
65. Katsura M, Mori H, Kunimatsu A et al. Radiological features of IgG4-related disease in the head, neck, and brain. *Neuroradiology* 2012;54:873–882.
66. Khosroshahi A, Carruthers MN, Deshpande V, Unizony S, Bloch DB, Stone JH. Rituximab for the treatment of IgG4-related disease: lessons from 10 consecutive patients. *Medicine (Baltimore)* 2012;91:57–66.
67. Nakazawa S, Shimizu K, Nakano T et al. An immunoglobulin G4-related disease mimicking postoperative lung cancer recurrence. *Mod Rheumatol* 2012;22:787–790.
68. Huang WC, Hsiao CH, Chang MH. Metachronous multiple clinical presentations in a patient with immunoglobulin G4-related sclerosing disease. *Clin Gastroenterol Hepatol* 2012;10:e34–e35.
69. Moriyama M, Tanaka A, Maehara T et al. Clinical characteristics of Mikulicz's disease as an IgG4-related disease. *Clin Oral Investig* 2013;17:1995–2002.
70. Baer AN, Gourin CG, Westra WH et al. Rare diagnosis of IgG4-related systemic disease by lip biopsy in an international Sjogren syndrome registry. *Oral Surg Oral Med Oral Pathol Oral Radiol* 2013;115:e34–e39.
71. Kuruma S, Kamisawa T, Tabata T et al. Clinical Characteristics of Patients with Autoimmune Pancreatitis with or without Mikulicz's Disease and Mikulicz's Disease Alone. *Gut Liver* 2013;7:96–99.
72. Sekiguchi H, Horie R, Aksamit TR, Yi ES, Ryu JH. Immunoglobulin G4-related disease mimicking asthma. *Can Respir J* 2013;20:87–89.
73. Masri KR, Shaver T. IgG4-related systemic disease: an uncommon presentation for an uncommon disease. *Rheumatol Int* 2013;33:1865–1866.
74. Nishino T, Toda J, Nakatsuka T, Kimura T, Inaoka T, Terada H. IgG4-related inflammatory pseudotumors mimicking multiple meningiomas. *Jpn J Radiol* 2013;31:405–407.
75. Origuchi T, Yano H, Nakamura H, Hirano A, Kawakami A. Three cases of IgG4-related orbital inflammation presented as unilateral pseudotumor and review of the literature. *Rheumatol Int* 2013;33:2931–2936.
76. Rolla D, Bellino D, Peloso G, Pia Rastaldi M, Simonini P, Louis Ravetti J. The first case of IgG4-related disease in Italy. *J Nephropathol* 2013;2:144–149.
77. Asai S, Okami K, Nakamura N et al. Localized or diffuse lesions of the submandibular glands in immunoglobulin g4-related disease in association with differential organ involvement. *J Ultrasound Med* 2013;32:731–736.
78. Yamada K, Hamaguchi Y, Saeki T et al. Investigations of IgG4-related disease involving the skin. *Mod Rheumatol* 2013;23:986–993.
79. Sato Y, Takeuchi M, Takata K et al. Clinicopathologic analysis of IgG4-related skin disease. *Mod Pathol* 2013;26:523–532.
80. Yao Q, Wu G, Hoschar A. IgG4-related Mikulicz's disease is a multiorgan lymphoproliferative disease distinct from Sjogren's syndrome: a Caucasian patient and literature review. *Clin Exp Rheumatol* 2013;31:289–294.
81. Ohta N, Kurakami K, Ishida A et al. Roles of TGF-beta and periostin in fibrosclerosis in patients with IgG4-related diseases. *Acta Otolaryngol* 2013;133:1322–1327.
82. Qu LM, Liu YH, Brigstock DR et al. IgG4-related autoimmune pancreatitis overlapping with Mikulicz's disease and lymphadenitis: a case report. *World J Gastroenterol* 2013;19:9490–9494.
83. Maida M, Macaluso FS, Cabibbo G, Lo Re G, Alessi N. Progressive multi-organ expression of immunoglobulin G4-related disease: A case report. *World J Hepatol* 2013;5:336–339.
84. Hagiya C, Tsuboi H, Yokosawa M et al. Clinicopathological features of IgG4-related disease complicated with orbital involvement. *Mod Rheumatol* 2014;24:471–476.
85. De Cocker LJ, D'Arco F, De Beule T, Tousseyn T, Blockmans D, Hermans R. IgG4-related systemic disease affecting the parotid and submandibular glands: magnetic resonance imaging features of IgG4-related chronic sclerosing sialadenitis and concomitant lymphadenitis. *Clin Imaging* 2014;38:195–198.
86. Morita T, Izawa A, Hamano H et al. Significant pericardial involvement of immunoglobulin G4-related disease. *Ann Thorac Surg* 2014;98:e47–49.
87. Andrew N, Kearney D, Sladden N, Goss A, Selva D. Immunoglobulin G4-related disease of the hard palate. *J Oral Maxillofac Surg* 2014;72:717–723.
88. Dy RV, Atlas SA. So many organs, 1 diagnosis: IgG4-related disease. *Am J Med* 2014;127:195–197.
89. Kempeneers D, Hauben E, De Haes P. IgG4-related skin lesions: case report and review of the literature. *Clin Exp Dermatol* 2014;39:479–483.
90. Nakashima Y, Nakamura H, Horai Y et al. Comorbid case of IgG4-related disease and primary Sjogren's syndrome. *Mod Rheumatol* 2015;25:462–467.
91. Chen H, Lin W, Wang Q et al. IgG4-related disease in a Chinese cohort: a prospective study. *Scand J Rheumatol* 2014;43:70–74.
92. Szanto A, Nagy G, Molnar CS, Griger Z, Tarr T, Zeher M. Description of patients with IgG4-related disease from a Hungarian centre. *Scand J Rheumatol* 2014;43:334–337.
93. Lee YS, Cho HJ, Yoo HS et al. A case of IgG4-related disease with bronchial asthma and chronic rhinosinusitis in Korea. *J Korean Med Sci* 2014;29:599–603.
94. Jiang LD, Ji Y, Zhang CY et al. IgG4-related disease: report of three cases [In Chinese]. *Zhonghua Feng Shi Bing Xue Za Zhi (Chin J Rheumatol)* 2010;14:283–284.
95. Zhao CC, Wang XM, Cen JH, Li J. A case of IgG4-related sclerosing disease with submandibular glands swelling, pancreatitis and bile duct obstruction [In Chinese]. *Zhonghua Yi Xue Za Zhi (Nat Med J China)* 2011;91:3151–3153.
96. He JX, Zhang HW, Xu EW. A case of IgG4-related lymphadenopathy and review of literature [In Chinese]. *Zhonghua Xue Ye Xue Za Zhi (Chin J Hematol)* 2012;33:677–678.

97. Zhang YL, Yang XL, Wu YH. A case of IgG4-related disease [In Chinese]. *Zhonghua Feng Shi Bing Xue Za Zhi (Chin J Rheumatol)* 2012;16:857–858.
98. Liu WX, Ren Y, Zhang K, et al. A case of IgG4 positive autoimmune pancreatitis with extensive lymphadenopathy and multiple glands involvement [In Chinese]. *Zhonghua Lin Chuang Yi Shi Za Zhi (Chin J Clinicians)* 2012;6:8436–8437.
99. Zhang YJ, Zhao JX, Liu R, Liu XY. A case report of IgG4-related sclerosing disease with lung involvement [In Chinese]. *Beijing Da Xue Xue Bao (Yi Xue Ban) (J Peking University(Health Sciences))* 2012;42:311–315.
100. Liu X, Li JT, Fan YH, et al. A case of IgG4-related disease misdiagnosed as pancreatic carcinoma [In Chinese]. *Zhonghua Feng Shi Bing Xue Za Zhi (Chin J Rheumatol)* 2012;16:854–855.
101. Sun L, Ma Y, Yu L, et al. A case of IgG4-related disease with multiple organs involvement [In Chinese]. *Zhonghua Lin Chuang Mian Yi He Bian Tai Fan Ying Za Zhi (Chinese Journal of Allergy and Clinical Immunology)* 2013;7:307–309.
102. Guo LJ, Cui LG. Radiological features of IgG4-related disease: a case report [In Chinese]. *Zhonghua Yi Xue Chao Sheng Za Zhi (Chin J Med Ultrasound)* 2013;10:693–694.
103. Li YJ, Sun L, Tian ZZ, et al. Overlap of IgG4-related autoimmune pancreatitis and Mikulicz's disease: a case report [In Chinese]. *Lin Chuang Gan Dan Bing Za Zhi (J Clin Hepatol)* 2014;30:681–682.
104. Yang CH, Li X, Wu HL, Yang XY. Treatment of IgG4-related disease with assistant of corticosteroid: one case report [In Chinese]. *Xin Yi Xue (Journal of New Medicine)* 2014;45:632–635.
105. Guo XX, Li YM, Hu ZD, et al. IgG4-related sclerosing disease with multiple organs involvement: case report and review of literature [In Chinese]. *Lin Chuang Yu Shi Yan Bing Li Xue Za Zhi (J Clin Exp Pathol)* 2014;30:64–67.
106. Uchida K, Masamune A, Shimosegawa T, Okazaki K. Prevalence of IgG4-Related Disease in Japan Based on Nationwide Survey in 2009. *Int J Rheumatol* 2012;2012:358–371.
107. Yamamoto M, Harada S, Ohara M et al. Clinical and pathological differences between Mikulicz's disease and Sjogren's syndrome. *Rheumatology (Oxford)* 2005;44:227–234.
108. Masaki Y, Dong L, Kurose N et al. Proposal for a new clinical entity, IgG4-positive multiorgan lymphoproliferative syndrome: analysis of 64 cases of IgG4-related disorders. *Ann Rheum Dis* 2009;68:1310–1315.
109. Ohta N, Kurakami K, Ishida A et al. Clinical and pathological characteristics of IgG4-related sclerosing sialadenitis. *Laryngoscope* 2012;122:572–577.
110. Yamamoto M, Takahashi H, Sugai S, Imai K. Clinical and pathological characteristics of Mikulicz's disease (IgG4-related plasmacytic exocrinopathy). *Autoimmun Rev* 2005;4:195–200.
111. Patel H, Khalili K, Kyoung KT et al. IgG4 related disease - a retrospective descriptive study highlighting Canadian experiences in diagnosis and management. *BMC Gastroenterol* 2013;13:168.
112. Crosara S, D'Onofrio M, De Robertis R et al. Autoimmune pancreatitis: Multimodality non-invasive imaging diagnosis. *World J Gastroenterol* 2014;20:16881–16890.
113. Kamisawa T, Nakajima H, Egawa N, Funata N, Tsuruta K, Okamoto A. IgG4-related sclerosing disease incorporating sclerosing pancreatitis, cholangitis, sialadenitis and retroperitoneal fibrosis with lymphadenopathy. *Pancreatol* 2006;6:132–137.
114. Khosroshahi A, Carruthers MN, Stone JH et al. Rethinking Ormond's disease: „idiopathic“ retroperitoneal fibrosis in the era of IgG4-related disease. *Medicine (Baltimore)* 2013;92:82–91.
115. Shimizu Y, Yamamoto M, Naishiro Y et al. Necessity of early intervention for IgG4-related disease--delayed treatment induces fibrosis progression. *Rheumatology (Oxford)* 2013;52:679–683.
116. Umehara H, Okazaki K, Masaki Y et al. Comprehensive diagnostic criteria for IgG4-related disease (IgG4-RD), 2011. *Mod Rheumatol* 2012;22:21–30.
117. Nakatani K, Nakamoto Y, Togashi K. Utility of FDG PET/CT in IgG4-related systemic disease. *Clin Radiol* 2012;67:297–305.