

Dynamic Implant Valve Approach for Dental Implant Procedures

Oded NAHLIELI¹

Objective: *To present the results of our current research involving the dynamic implant valve approach (DIVA) in cases with human patients.*

Methods: *The new kind of implant was designed with an internal sealing screw that might serve for drug delivery system and possible endoscopic direct observation via its channel. The DIVA was used in cases when the implant insertion should be combined with the maxillary sinus floor lifting and/or bone augmentation procedure. A total of 63 patients (female n = 31, male n = 32, age range 33–67 years old, mean age 49 years old) were treated with DIVA and 218 new type implants were inserted.*

Results: *Out of 218 inserted implants, 146 implants were inserted in the maxilla with bone level < 5 mm, and 72 implants were inserted in the maxilla with bone level > 5 mm. The number of implants per patients varied from one to eight. The failure consisted of seven implants (3.2%) in five patients. No correlation was found between failure cases and the bone density or quality. Follow up (4 to 18 months) showed that in 211 cases (96.8%), the implantation was totally successful both from objective clinical, imaging (cone beam computed tomography) and subjective patients' viewpoints.*

Conclusion: *The new dynamic implant valve approach simplified dental implantation procedure and postoperative treatment. The implant with an inner sealing screw could be considered for use in cases when elevation of the maxillary sinus membrane is needed, as well as in cases when bone augmentation procedures or future treatment might be suspected.*

Key words: *dental implant, maxillary sinus floor lifting, bone augmentation*

When dental restoration began to shift from fixed bridges to dental implants, contemporary dentistry appreciated the importance of anatomy of the maxillary sinus and the bone quality of the maxillary bone. The low position of the maxillary sinus could prevent effective dental implantology below the sinus. Fortunately, it soon became clear that maxillary sinus floor lifting procedure with bone augmentation might help to overcome this problem and dental implantology gained new stimulus. However, despite all recent improvements in

dental implantology, complications are still unavoidable in this area of dentistry¹. While blinded or endoscopically guided, an implant insertion procedure can damage of anatomical structures such as inferior alveolar nerve, other nerves the maxillary sinus, and to lingual perforation²⁻⁴. Loosening of implant or fracture of the implant head during insertion also can occur^{3,5}. The sinus floor lifting/augmentation itself is not perfected yet and also can lead to further complications^{6,7}.

In the 1980s and '90s, several works of Tatum et al indicated possibilities to combine sinus floor augmentation with implant placement⁸⁻¹⁰. However, inflammatory diseases around the implant area presented a problem that has not yet been solved. This problem only appeared at the beginning of the 1990s^{11,12} and was inevitably following the development of implantology. Researchers and clinicians are in need of finding predictable techniques to treat peri-implant bone loss and stop its progression, but up to now their results have

¹ Department of Oral and Maxillofacial Surgery, Barzilai Medical center, Ashkelon, Israel, affiliated to the Ben Gurion University of the Negev, Beer Sheba Israel.

Associate Professor, Michigan University, MI, USA.

Professor, Ben Gurion University of the Negev, Beer Sheba, Israel.

Corresponding author: Prof. Oded Nahlieli, Department of Oral and Maxillofacial Surgery, Barzilai Medical Center, Ashkelon 78306, Israel. Tel: 972 86745533; Fax: 972 86745532; E-mail: nahlieli@yahoo.com




Fig 1a to d The DIVA implants with the internal sealing screw.

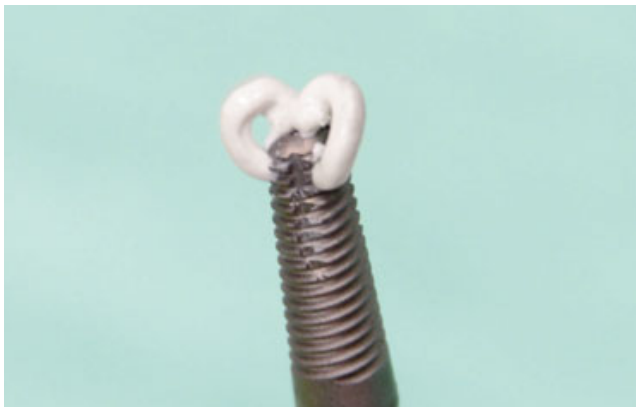

Fig 2 Injection of bony substitute via the implant channel.

not been satisfactory¹³. Inflammation due to implant insertion procedures or due to implant relocation can affect the maxillary sinus^{14,15}, which stresses the need to improve maxillary sinus augmentation.

High demand for minimally invasive procedures led us to invent the implant for a one-stage transcresal augmentation of the sinus and implant placement. This dynamic implant valve approach (DIVA) (Uplagon Dental) consists of an implant with an inner sealing screw, which facilitates and expedites the closed sinus lift procedure, which further reduces the risk for inadvertently tearing the Schneiderian membrane. This system was tested *in vitro*, and later its feasibility was tested in a large animal model (swine)¹⁶. The testing revealed that the DIVA can be successfully used for augmentation procedures, especially of the maxillary

sinus, in a standard fashion, as well as for intra- or postoperative delivery of therapeutic agents, and in combination with a dental endoscope for direct vision during the procedure. Our current research presents the first results of the DIVA usage in cases with human patients.

Materials and methods

The implant

The Titanium-Aluminum-Vanadium implant (Ti-6Al-4V ELI) was designed with an internal sealing screw that might serve for endoscopic direct observation and as a drug delivery system via its channel (Figs 1 and 2). The implants have external standard platform diameters of 3.25 and 3.75 and were tested in the ISRAC – Israel Laboratory Accreditation Authority for dynamic fatigue test as requested for endosseous dental implants (ISO 14801:2007). As it was said previously, they were successfully tested on the animal model. The additional fatigue test (EndoLab Mechanical Engineering) revealed that the run-out bending moment for the newly proposed implant was above the range reached by dental implants of the predicate devices (metal dental implants with a diameter of 3.75 mm were chosen for comparison). The implants were successfully tested for a possible inner screw leakage during screw-unscrew procedures (leakage sealing test, ISO 11737-2:2009; ISO 11737-1:2006; Milouda SOPs – 200.04.01¹⁶). In this test, no bacteria growth was detected and the test group and control group met the test's acceptance criteria.

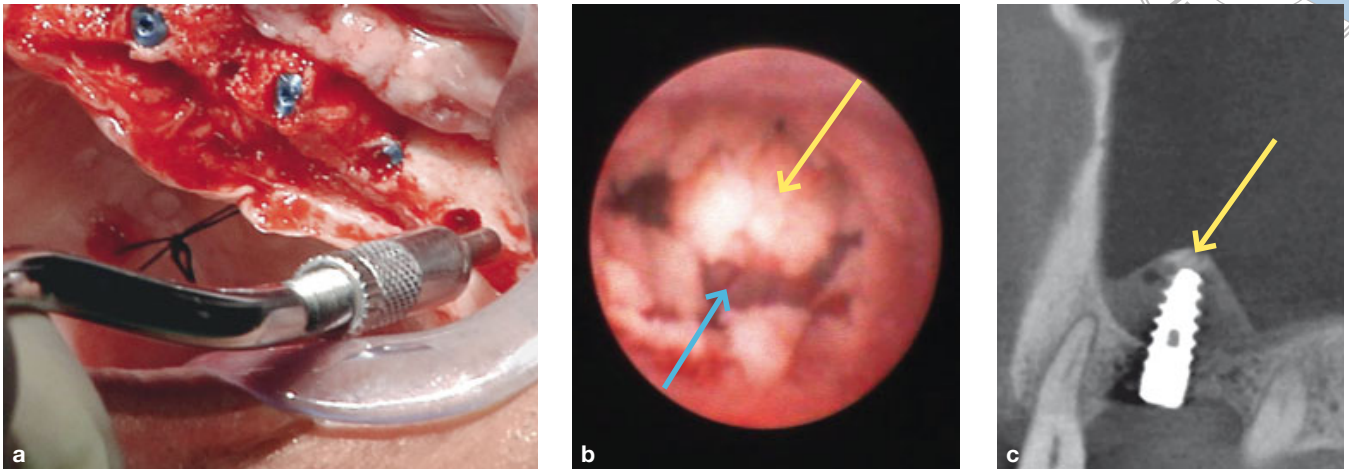


Fig 3 a The osteotome technique – preparation of the implant site with 2.7 mm curved osteotome. b Endoscopic view following the osteotome technique. The yellow arrow directed to the bony disk, the blue arrow directed to the Schneiderian membrane. c CBCT demonstrating the creation of the stable tent with the bony disk supported by the implant (the yellow arrow directed to the bony disk).

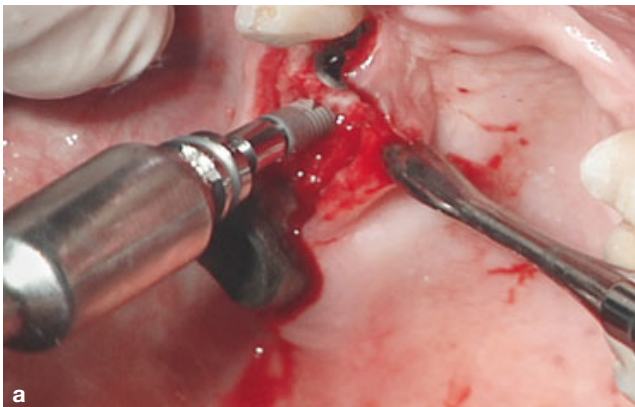


Fig 4a Insertion of the DIVA implant till the implant is stable.

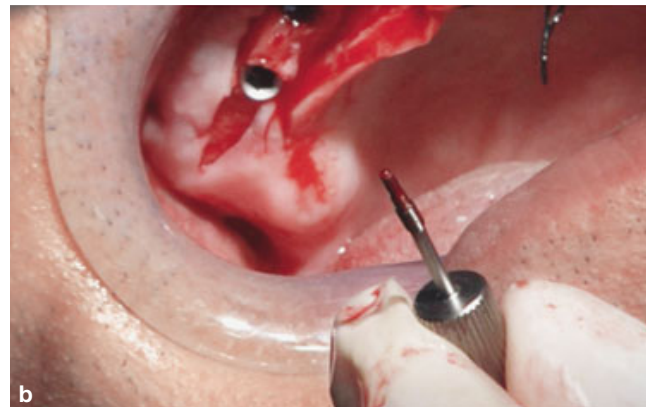


Fig 4b Removal of the sealing screw.

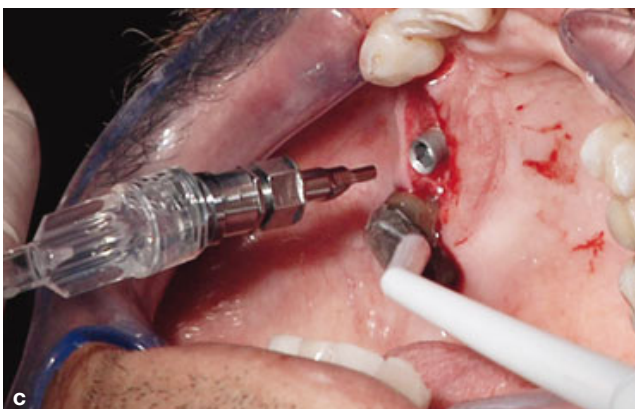

Fig 4c Connection of the DIVA implant to the saline irrigation device.

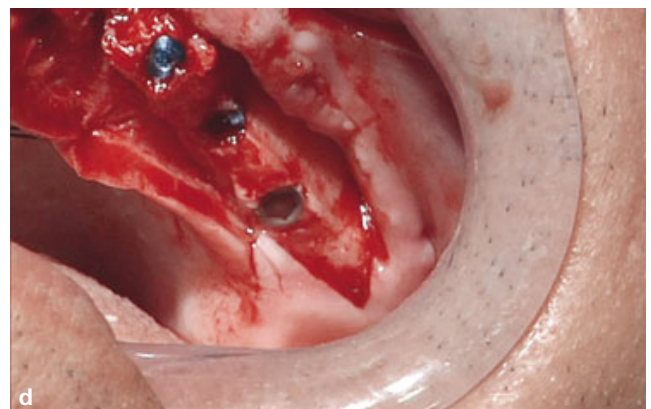


Fig 4d Bleeding sign from the implant coronal side – fracture of the sinus floor.

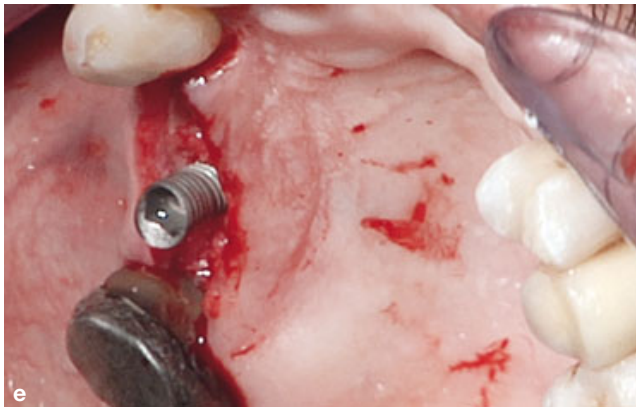

Fig 4e Saline movement according to the respiratory movement.

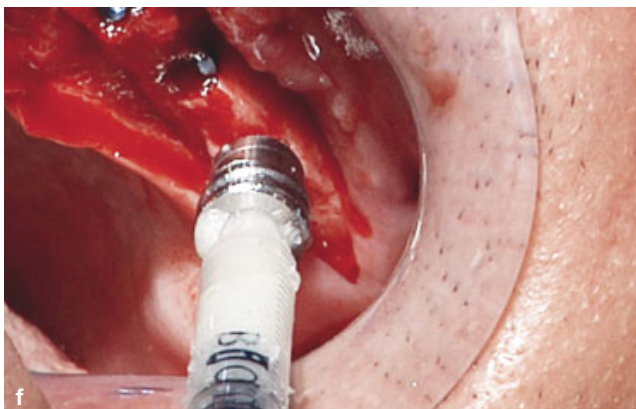


Fig 4f Injection of collagen gel via the implant port.

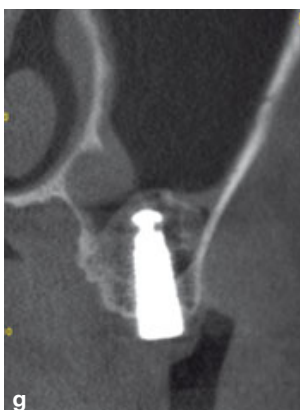


Fig 4g CBCT immediately following the insertion of the DIVA implant, demonstrating the creation of the selective sinus elevation.

The patients

During 2012 and 2013, 63 patients (31 women, 32 men, age range 33 to 67 years, mean age 49 years) were treated with DIVA and 218 new type implants were inserted. The main inclusion criterion was a need for maxillary

sinus floor elevation/augmentation to be performed for successful implant insertion. The exclusion criteria were: unhealthy sinuses, thickness of the sinus walls less than 3 mm, and calculated suspicion that primary stability of the implant could not be achieved.

The bone quality of the patients was initially assessed by cone beam computed tomography (CBCT), and CT images were further evaluated by endoscopy during the surgery. The bone density was measured on the CT images by Hounsfield units (HU)¹⁷.

The procedure

The DIVA approach is a minimally invasive approach procedure.

In cases of the bone level being smaller than 5 mm, the operative technique to gain primary stability and to achieve stable tent and bone connected to the sinus membrane was the osteotome technique, first described by Tatum and extensively used since¹⁸⁻²⁰. As the first step, we used a 2 mm drill to move up to 1 mm from the sinus floor (according to the CT image). Following the drilling, we used a 2.7 mm curved osteotome to reach 1 mm level from the sinus floor (Figs 3a, 3b and 3c). This technique compressed the crestal bone and created a bone disk that was further transferred to the sinus by the implant slow ratcheting. The next step was to place a 5 mm collagen sponge in the drilling site to protect the membrane of the sinus. The implant (diameter: 3.75 mm; length: 13 mm) was inserted in the bone till the stability is reached (Fig 4a). After that, the internal screw was removed (Fig 4b). That followed by saline irrigation via the internal port; 1 cc of saline followed by 1 mm of slow ratcheting (Fig 4c). This procedure was performed until we reached the level needed for the length of the implant. The bleeding of the sinus floor at the site of a fracture could be seen by a naked eye or by the endoscope that was inserted into the implant (Fig 4d). The integrity of the membrane was evaluated by the respiratory movement of the saline level via the implant coronal space (Fig 4e).

Injection of jelly bony substitute via the inner channel space was an option (6 patients, 10%) after completion of the sinus elevation in flat sinus configuration in order to stabilise the tent formation (Fig 4d). We used 0.5 mL of either liquid Avitene Microfibrillar Collagen (BARD Davol RI USA) or microporous biphasic calcium phosphate gel (MBCP, Biomatlantes) for optional augmentation purposes. These gels were delivered through the implant into the sinus (sub-antrally) via the DIVA injection adaptor. The screw was then inserted back and tightened. The procedure ended with ratcheting of the implant and primary closure of the flap (Fig 4f).

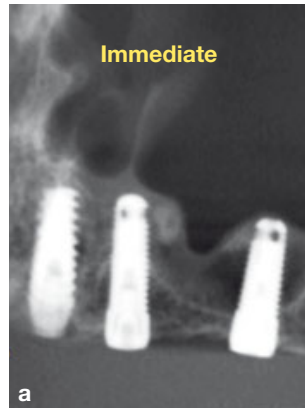

Fig 5a CBCT (sagittal view) of 56-year-old woman immediately after the selective sinus elevation and creation of the stable tent.

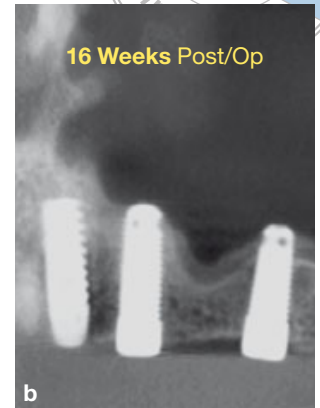


Fig 5b CBCT (sagittal view) 16 weeks after the procedure, demonstrating the formation of bone in the tent.

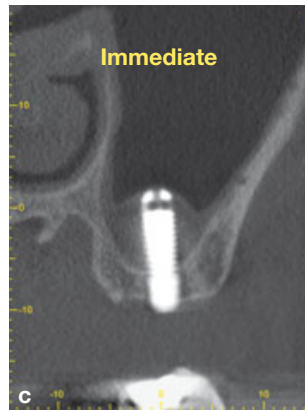

Fig 5c CBCT (coronal view) of the same patient immediately following the procedure.

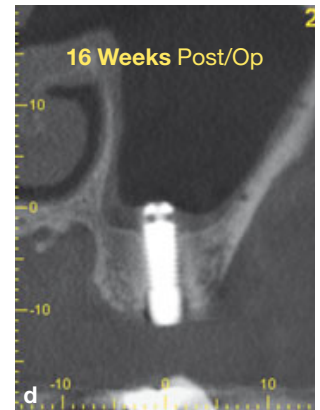


Fig 5d CBCT (coronal view) of the same patient 16 weeks following the procedure, demonstrating the formation of bone in the tent.

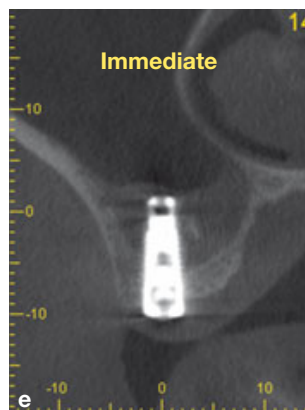


Fig 5e CBCT (coronal view) of 60-year-old man immediately following the procedure.

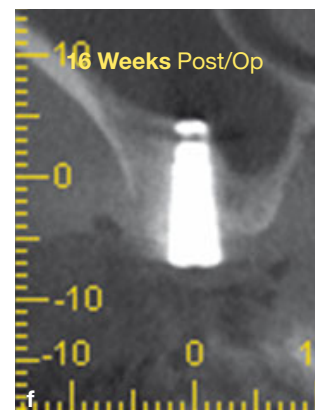


Fig 5f CBCT (coronal view) of the same patient 16 weeks following the procedure, demonstrating the formation of bone in the tent.

In cases of bone level exceeding 5 mm, we used regular drilling technique to reach 1 mm level from the sinus floor and then the same ratcheting and irrigating technique was implemented.

Perioperative antibiotics were administered. The follow-up period was from 1 to 18 months.

Statistics

The Chi-squared test was used to find a possible correlation between the results and the bone quality and density, and between the results and cases when a patient suffered from diabetes and osteoporosis.

Results

Out of 218 inserted implants, 146 implants were inserted in the maxilla with bone level < 5 mm, and 72 implants were inserted in the maxilla with bone level > 5 mm. The number of implants per patient varied from one to eight. The failure consisted of seven implants (3.2%) in five patients. Postoperative follow-up intervals of the patients were carried out after 1, 4, 6, 12 and 18 months. CBCT scans were taken immediately after the procedure and after 4 and 12 months.

Signs of local infection were the main cause of a failure (4 out of 5 patients) and the implants were removed two weeks after the insertion (average). The failure cases were tested for correlation with the bone quality and the bone density. The correlation was negative in both tests (failure vs D3 or D4 bone quality: $r =$ or < 0.21 , $P < 0.01$; failure vs density in HU: $r =$ or < 0.17 , $P < 0.01$). Three out of five patients with unsuccessful implantation suffered from diabetes but no statistically sound conclusions might be made because of the small numbers.

During the follow-up period, the assessment was made by taking subjective information from the patient, intraoral clinical observation, and by endoscopic control via the internal port (screw) of the implant. In 211 cases (96.8%), the implantation was totally successful both from objective CBCT clinical and subjective patients' viewpoints (Figs 5a to 5f).

Discussion

The aim of the present study was to report the first results of DIVA implant usage in adult humans after it was successfully tested on animals. While designing the type of the implant, we hypothesised that proper changes in the construction of the implant itself might solve several problems, i.e. 1) to reduce risk of complications; 2) to improve the maxillary sinus floor lifting/augmentation; and 3) to secure proper management of inflammatory diseases, bone loss, and low density bone. Having these three problems in mind, we developed the dynamic implant valve approach (DIVA) for the dental implant procedures that uses an implant with an inner sealing screw. This innovation was put to test successfully and the current article describes the results that we obtained in adult patients.

The current goal of the dental implantation development is to increase the longevity of oral implants by securing proper implant placement into bone of sufficient density. In the maxillary bone, this density varies significantly from 443 to 1,580 HU in various

parts of the bone¹⁷. Hopefully the highest bone density is observed in the canine and premolar areas. It was shown that bone mineral density in the maxilla is significantly lower if compared with the mandible density²¹. Therefore, the bone augmentation is a frequent procedure for the maxilla. Another fundamental cause for differences in the survival of dental implants is that bone quality is also weaker in the maxilla (D3 or D4 types) than in the mandible (D1 and D2 types). Currently, the assessment of bone quality is based on radiographic evaluation, endoscopic observation, and on the subjective sensation of resistance experienced by the surgeon when preparing the implant site.

The first results from the DIVA implant use in cases when elevation of the sinus membrane and/or augmentation procedure of the maxilla were needed revealed that this minimally invasive procedure is simple, rarely requires the lateral open approach, and leads to immediate expansion of the sinus membrane. The procedure itself can be performed with or without endoscopic control, but the endoscopic observation is desirable for bone quality assessment and precise anatomical guidance.

There are several reports in the literature supporting the technique of sinus elevation using stable tent formation and creation of bone via the osteogenic potential of the Schneiderian membrane^{18-20,22}. The use of the osteotome technique creates a vital bone disk, which is connected to the Schneiderian membrane and is supported by the DIVA implant. When dealing with narrow or curved sinus topography (the majority of cases) the elevation of the sinus floor with our DIVA implant system irrigation and slow ratcheting technique separates the membrane with the hydro dissection procedure and the ratcheting stretches the membrane without tearing it. Thus, building a tent includes a vascularised bone, the Schneiderian membrane and the blood around the implant that can stabilise the tent. In such a condition, the bone formation takes 4 to 6 months.

In cases of flat sinus configuration, in order to stabilise the tent, bone substitute gel might be injected through the screw channel before sealing the inner channel. This procedure is, however, optional as some studies show that this procedure might not be necessary²². The implant channel, however, can serve many purposes, such as delivering drugs inside the bone in cases of inflammatory diseases, further bone augmentation, delivering other agents when the bone quality is poor, and for endoscopic monitoring during and after the procedure. Our previous research using an animal model and the results of the current study led us to believe that the DIVA approach might successfully serve in all three scenarios of the implant insertion:

1) when a sinus floor lift is needed, 2) when bone augmentation is needed, and 3) when floor lifting and bone augmentation are needed for the same patient. The reliability and longevity of medical devices are very important issues. In the case of our new implant, the fatigue tests revealed that hollow structures like the new implant are more fatigue resistant than solid implants because of better force redistribution. The tests also revealed that bacteria cannot penetrate the bone via tight screw while infection, like in cases with any other type of an implant, finds its way in outside the implant. Fortunately, the literature indicates this complication to occur in less than 5% of all implantation cases.

The new approach permits a closed sinus lifting procedure via the implant itself, drug delivery via the implant port, intraosseous feedback via the same port, augmentation procedures via the implant, and endoscopic control over the implant and the surrounding bone during the entire period of the usage of the implant, which are all advantages of the DIVA implant system.

Conclusion

The new dynamic implant valve approach simplified dental implantation procedure and postoperative treatment. The implant with an inner sealing screw could be considered for use in cases when elevation of the maxillary sinus membrane is needed, as well as in cases when bone augmentation procedures or future treatment might be suspected.

References

- Garg A. Concept review: managing complications associated with implant procedures. *Dent Implantol Update* 2011;22:37–40.
- Tilaveridis I, Lazaridou M, Dimitrakopoulos I, et al. Displacement of three dental implants into the maxillary sinus in two patients. Report of two cases. *Oral Maxillofac Surg* 2012;16:311–314.
- Prashanti E, Sajjan S, Reddy JM. Failures in implants. *Indian J Dent Res.* 2011;22:446–453.
- Kulkarni S, Kumar S, Kamath S, Thakur S. Accidental identification of accessory mental nerve and foramen during implant surgery. *J Indian Soc Periodontol* 2011;15:70–73.
- Doh RM, Pang NS, Kim KD, Park W. Implant displacement into the mandible: an unusual complication during implant surgery. *Implant Dent* 2011;20:345–348.
- Tasoulis G, Yao SG, Fine JB. The maxillary sinus: challenges and treatments for implant placement. *Compend Contin Educ Dent* 2011;32:10–14, 16, 18–19; quiz 20,34.
- Longhini AB, Branstetter BF, Ferguson BJ. Radiology quiz case 1. Acute maxillary sinusitis secondary to a migrated dental implant obstructing the ostiomeatal complex. *Arch Otolaryngol Head Neck Surg* 2011;137:823, 826.
- Tatum H Jr. Maxillary and sinus implant reconstructions. *Dent Clin North Am* 1986;30:207–229.
- Tatum H Jr. Endosteal implants. *J Calif Dent Assoc* 1988;16:71–76.
- Masters DH, Tatum H Jr. Dental implants. *J Am Dent Assoc* 1995;126:1210.
- Meffert RM. What causes peri-implantitis? *J Calif Dent Assoc* 1991;19:53–54, 56–57.
- Alcoforado GA, Rams TE, Feik D, Slots J. Microbial aspects of failing osseointegrated dental implants in humans. *J Parodontol* 1991;10:11–18.
- Aljateeli M, Fu JH, Wang HL. Managing peri-implant bone loss: current understanding. *Clin Implant Dent Relat Res* 2012;14 Suppl 1:e109–118.
- D’Ovidio C, Carnevale A, Pantaleone G, et al. First report of an acute purulent maxillary sinusitis caused by *Pseudomonas aeruginosa* secondary to dental implant placement in an immunocompetent patient. *Br Dent J* 2011;211:205–207.
- Chow J, Wat P, Hui E, et al. A new method to eliminate the risk of maxillary sinusitis with zygomatic implants. *Int J Oral Maxillofac Implants* 2010;25:1233–1240.
- Nahlieli O, Casap N, Moshonov J, et al. A novel dental implant system with an internal port for endoscopic closed sinus augmentation: a feasibility study in pigs. *Int J Oral Maxillofac Implants* 2013;28:e556–561.
- Park HS, Lee YJ, Jeong SH, et al. Density of the alveolar and basal bones of the maxilla and the mandible. *Am J Orthod Dentofacial Orthop* 2008;133:30–37.
- Si MS, Zhuang LF, Gu YX, et al. Osteotome sinus floor elevation with or without grafting: a 3-year randomized controlled clinical trial. *J Clin Periodontol* 2013;40:396–403.
- Santagata M, Guariniello L, D’amato S, et al. Augmentation of atrophic posterior maxilla by short implants and osteotome technique. *Stomatologija* 2012;14:85–88.
- Al-Almaie S, Kavarodi AM, Al Faidhi A. Maxillary sinus functions and complications with lateral window and osteotome sinus floor elevation procedures followed by dental implants placement: a retrospective study in 60 patients. *J Contemp Dent Pract* 2013;14:405–413.
- Devlin H, Horner K, Ledgerton D. A comparison of maxillary and mandibular bone mineral densities. *J Prosthet Dent* 1998;79:323–327.
- Si MS, Mo JJ, Zhuang LF, et al. Osteotome sinus floor elevation with and without grafting: an animal study in Labrador dogs [epub ahead of print 20 Dec 2013]. *Clin Oral Implants Res* doi:10.1111/clr.12313.