

Variation in Mesiodistal Root Angulation of Panoramic Images Generated from Cone-beam Computed Tomography

Si Qi LIU¹, Fu Jia WEN¹, Hua CHEN², Yi LIU¹

Objective: To compare the mesiodistal root angulation of panoramic images generated from traditional panoramic tomography or cone-beam computed tomography (CBCT).

Methods: CBCT scans and panoramic radiographs of 20 patients were collected. The Invivo-Dental 5.0 was separately applied for maxillary or mandibular panoramic image generation. The generation method was assorted by two head positions, the Frankfort plane horizontal position (P1) and the occlusal plane horizontal position (P2), and three central plane settings (root apical plane, tooth centre plane and crown marginal plane). The amount of mesiodistal root angulation on panoramic images generated from CBCT (GPIs) deviated from that on the traditional panoramic images was calculated by paired sample test. The variation trends were explored with different head rotation and incisors' buccolingual root inclination.

Results: By selecting the tooth centre plane, the GPIs were suggested to be generated by the Frankfort plane horizontal position for maxilla; while the occlusal plane horizontal position was advised for mandibular GPIs' generation. Moreover, the mesiodistal root angulations were demonstrated to regularly change along with variations of head rotation and the incisors' buccolingual root inclination.

Conclusion: Panoramic images can be generated from CBCT by the standard operating procedures with proper head position and central plane setting. But cautions should be taken during the generation, bearing the variability of mesiodistal root angulation in mind.

Key words: cone-beam computed tomography, generated panoramic images, mesiodistal root angulation, head rotation, incisors' buccolingual inclination

Originally designed for the imaging of hard tissues in the maxillofacial region, cone-beam computed tomography (CBCT) technology has gained widespread use in clinical dental practice over the past two decades. CBCT is capable of providing a 3-dimensional (3D) representation of the maxillofacial skeleton with minimal

distortion. As such, it provides orthodontists with an easy way to visualize maxillofacial structures that are closely connected to orthodontic treatment, such as the bony components of the TMJ, ectopic canines, impacted third molars, or alveolar bone condition^{1,2}. Furthermore, with advanced software programs, 3D representation can be cut or cropped at any angle to produce desired 2-dimensional images³. This technology can have tremendous clinical implications for orthodontists, as it provides opportunities for orthodontists to generate cephalograms, frontal radiographs or panoramic images from 3D data with proper operative procedures³⁻⁵.

Panoramic radiographs have been used as a diagnostic aid before, during and after orthodontic treatment to assess root position. This procedure was once required by the American Board of Orthodontics in the clinical examination portion of its certification, for documentation of root parallelism after treatment⁶. Adequate

1 Department of Orthodontics, Peking University School and Hospital of Stomatology, Beijing, P.R. China.

2 Department of Orthodontics, Peking University School of Stomatology 2nd Dental Centre, Beijing, P.R. China.

Corresponding author: Dr Yi LIU, Department of Orthodontics, Peking University School and Hospital of Stomatology, #22 Zhongguancun Nandajie, Haidian District, Beijing 100081, P.R. China. Tel: 86-10-82195336/7; E-mail: pkussliuyi@gmail.com

This research is supported by the National High Technology Research and Development Programme of China (863 Programme) 2013AA040803.



Table 1 Maxillary grouping based on U1-FH and OP-FH values

Groups	U1-FH ° range	OP-FH ° range	Number of samples
UG 1-A	100–105	5~10	2
UG 1-B		11~15	1
UG 2-A	110–115	5~10	3
UG 2-B		11~15	6
UG 3-B	116–120	11~15	5
UG 4-A	125–130	5~10	3

Table 2 Mandibular grouping based on L1-FH and OP-FH values

Groups	L1-FH ° range	OP-FH ° range	Number of samples
LG 1-A	≤60	11~15	1
LG 2-A	61~65	5~10	2
LG 2-B		11~15	1
LG 3-B	66~70	11~15	5
LG 4-A	71~75	5~10	4
LG 4-B		11~15	2
LG 5-B	76~80	11~15	3
LG 6-A	81~85	5~10	2

mesiodistal root angulation is indispensable for ideal occlusion and proper articulation, which are regarded as among the primary objectives in orthodontic treatment⁷. However, researchers have demonstrated that the panoramic radiograph, with consideration of variable magnification and geometric distortion that are inherent in image generation, has limits when used for the assessment of mesiodistal root angulation. Angular distortion in panoramic radiographs can be attributed to variances in the focal trough and projection angle or other patient-related factors, including the buccolingual root inclination, the geometry of the patient, head positioning and the cant of the occlusal plane⁸⁻¹⁴.

Generated panoramic images from CBCT (GPIs) can serve as an effective solution because CBCT generation does not exhibit the distortion inherent in 2-dimensional (2D) panoramic radiograph acquisitions¹⁵. As demonstrated in previous studies, compared with values measured by a coordinate-measuring machine, mesiodistal root angulation values measured from GPIs were more accurate than those measured from panoramic radiographs^{3,16}. On the other hand, even if the use of CBCT is widespread, orthodontists have not yet been used to looking and navigating the 3D data in clinics. The temporary absence of a valid 3D coordinate sys-

tem prevents orthodontists from directly measuring the mesiodistal root angulation with 3D data. Therefore, the generated panoramic images are still clinically significant for orthodontists in regular clinics.

The purpose of this study was to establish an operative procedure for generating panoramic images from CBCT, and to explore the variations in mesiodistal root angulation due to different head rotation, and incisors' buccolingual root inclination as panoramic images were generated from CBCT.

Material and methods

Sample selecting and grouping

The data of 20 patients (5 male, 15 female; mean age = 18.8 years) of a previous study¹⁷ were collected for this study. The subjects' inclusion criteria were: no anterior teeth missing and no more than 1 degree crowding dentition. The subjects had both panoramic radiography and cone beam computed tomography scans taken for further analysis. As measured by a cephalogram, the buccolingual inclination of the maxillary central incisors (U1-FH values) ranged from 100 to 130 degrees,




Fig 1 After 3D superimposition, the rendered 3D volumes were rotated to set the Frankfort plane (P1, left) or anatomic occlusal plane (P2, right) parallel to the horizontal plane.

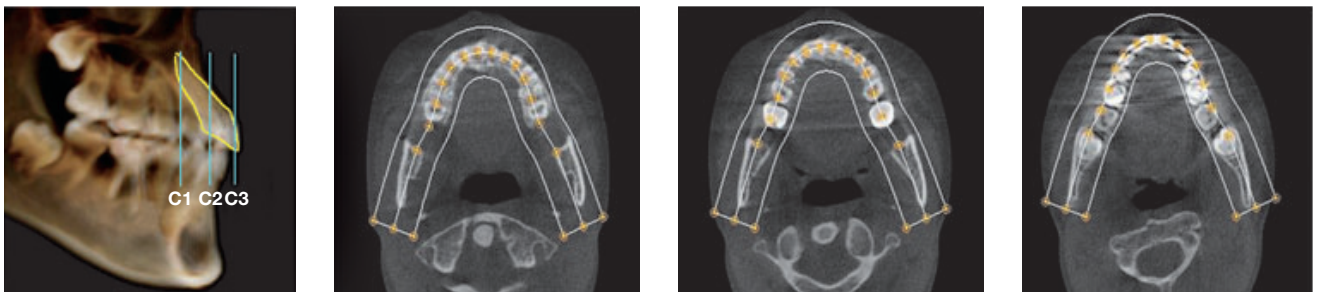


Fig 2 The focal trough shape was designed to coordinate with the arch shape, while the thickness was set to the smallest possible value that still included all crowns and roots of both maxillary and mandibular canines and incisors. This procedure was performed as the tooth centre plane was moved from above the level of the tooth apices to below the apices. Three centre planes, the root apical plane (C1), tooth center plane (C2) and crown marginal plane (C3) based on the central incisors, were then separately set for the maxilla and mandible.

the buccolingual inclination of the mandibular central incisors (L1-FH values) ranged from 52 to 83 degrees, and the inclination of the occlusal plane (OP-FH values) ranged from 5 to 15 degrees. With 5-degree intervals, the sample was divided into four groups based on U1-FH values from the maxilla. The same grouping method was used for the mandible based on L1-FH values, resulting in six groups. Within both the maxilla group and mandible group, the samples were divided once again using OP-FH into A (OP-FH value: 5 to 10 degrees) or B groups (OP-FH value: 10 to 15 degrees). All grouping results are shown in Tables 1 and 2.

Scan settings for panoramic radiography and CBCT

Panoramic radiography was acquired by positioning the patient along the Frankfort plane, parallel to the floor and without any head tilting (Orthopantomograph OP100,

Instrumentarium). All radiographs were taken using the following settings: 66 kVp, 10 mA, and 17.6s. Images were saved in JPEG format. CBCT scans were obtained with DCT Pro (VATECH) using a 20 × 19 cm field of view (FOV) and the following settings: 90 kVp, 7 mA, and 15s. The images were saved in DICOM (Digital Imaging and Communications in Medicine) 3.0 format and imported into InvivoDental 5.0 (Anatomage) for subsequent generations.

Generation procedures for panoramic images from CBCT

According to the 3-dimensional superimposition method¹⁷, the rendered 3D volumes were first adjusted to the position in which bilateral craniofacial anatomic structures were maximally superimposed. Then, they were oriented in either the Frankfort plane horizontal

position (P1) or the occlusal plane horizontal position (P2) (Fig 1). In each position, the focal trough and its three central planes, the root apical plane (C1), tooth centre plane (C2) and crown marginal plane (C3) based on the central incisors, were set separately for the maxilla and mandible (Fig 2). Six generation methods were generated using two head positions and three central planes setting for each patient. As such, 12 GPIs per patient, equally divided between the maxilla and mandible, were ultimately generated and saved in JPEG format.

Measurement of mesiodistal root angulation

All GPIs and panoramic images were imported into GetData Graph Digitizer V2.23 (GetData Pty) to locate the points used to define the long axes of teeth, and then all point coordinate values were exported in Microsoft Excel format. Acute intersection angles between contiguous teeth for all teeth between the canines were then calculated (Fig 3).

Statistical analysis

Two separate measurements were made by two examiners using the same protocols, with a week long separation between measurements. The intraclass correlation coefficient (ICC) was applied to test intraexaminer reliability and interexaminer consistency.

Paired sample *t* tests were used to explore the amount of GPIs deviating from panoramic images in mesiodis-

tal root angulation when the GPIs were generated with different methods.

Results

The ICC results showed very strong intraexaminer reliability ($r = 0.97$, 95% CI: 0.95–0.98) and acceptable interexaminer consistency ($r = 0.70$, 95% CI: 0.65–0.74).

Variations in different central planes and head position settings

The amounts of GPIs deviating from panoramic images in mesiodistal root angulation were calculated by paired sample *t* tests in the unit of intersection angle (Tables 3 and 4). Such variation values between different central planes settings in each head position was first compared separately for the maxilla and mandible (Fig 4a). The variation values between the two kinds of head position with the tooth central plane setting were compared separately for the maxilla and mandible (Fig 4b).

Variations in different incisors' buccolingual inclination and head rotation settings

The mesiodistal root angulation of the GPIs varied with the change of central incisors' buccolingual inclination and the head rotation. The variation trends were explored separately for the maxilla and mandible (Figs 4c, 4d, and 4e).

Discussion

With proper generation methods, GPIs not only provide a qualified display of all anatomic structures as shown in panoramic radiographs, but can also eliminate certain unwanted artefacts (e.g. cervical vertebrae) associated with panoramic radiographs (Fig 5).

The method of generating panoramic images from CBCT scans that was employed in this study is convenient and effective, as demonstrated by the very strong intraexaminer reliability and acceptable interexaminer consistency.

The generation procedure should be separately implemented for the maxilla and the mandible because CBCT does not share the same patient position as does panoramic radiography during the screening. As revealed in the results, the generated panoramic images from the CBCT and panoramic radiographs did not share a similar variation trend in mesiodistal root angulation between the maxilla and mandible. So, the suggestion of separately generating panoramic images for the maxilla and mandible appears to be well founded.

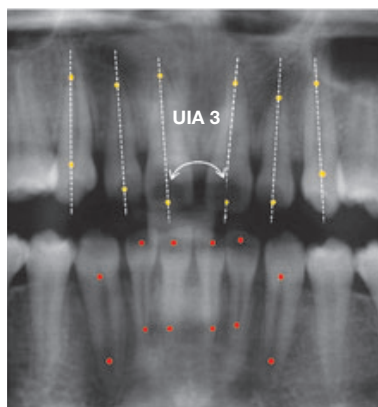


Fig 3 To measure mesiodistal root angulation in GPIs and panoramic images, the long axis of the tooth was assessed using a line connecting the crown midpoint of incisors or the crown apex of canines and their root apices of the pulp cavity. The acute intersection angles of the long axes of contiguous teeth for all teeth between the canines in the maxilla (marked as UA1-5) or mandible (marked as LA1-5) were then calculated.

Table 3 Paired sample test for maxillary root inclination between panoramic radiographs and GPIs

Intersection Angle	Methods	N	Mean Difference	Std Deviation	95% Confidence Interval of the Difference		t	Sig
					Upper	Lower		
UA 1	P1-C1	20	0.00	1.53	-0.72	0.71	-0.01	0.99
	P1-C2*	20	0.94	1.72	0.13	1.75	2.44	0.03
	P1-C3*	20	1.72	2.71	0.45	2.99	2.83	0.01
	P2-C1*	20	1.32	1.88	0.44	2.20	3.13	0.01
	P2-C2*	20	2.05	2.36	0.95	3.16	3.89	0.00
	P2-C3*	20	2.70	4.06	0.80	4.60	2.98	0.01
UA 2	P1-C1	20	0.12	1.01	-0.35	0.60	0.54	0.59
	P1-C2	20	0.44	1.73	-0.37	1.25	1.13	0.27
	P1-C3	20	1.05	3.36	-0.52	2.62	1.40	0.18
	P2-C1	20	0.13	1.66	-0.65	0.91	0.34	0.74
	P2-C2*	20	1.02	2.30	-0.05	2.10	1.99	0.06
	P2-C3*	20	4.95	5.18	2.53	7.37	4.28	0.00
UA 3	P1-C1	20	-0.18	1.30	-0.79	0.42	-0.64	0.53
	P1-C2*	20	0.54	1.14	0.01	1.08	2.13	0.05
	P1-C3*	20	5.53	5.84	2.80	8.27	4.24	0.00
	P2-C1	20	0.92	2.04	-0.03	1.87	2.02	0.06
	P2-C2*	20	2.35	2.07	1.38	3.33	5.08	0.00
	P2-C3*	20	11.91	9.83	7.31	16.51	5.42	0.00
UA 4	P1-C1*	20	-0.61	0.88	-1.03	-0.20	-3.13	0.01
	P1-C2*	20	-0.65	1.19	-1.20	-0.09	-2.43	0.03
	P1-C3	20	0.38	2.33	-0.71	1.48	0.74	0.47
	P2-C1	20	-0.46	1.09	-0.97	0.05	-1.89	0.07
	P2-C2	20	-0.09	1.69	-0.88	0.70	-0.24	0.82
	P2-C3*	20	3.09	4.00	1.21	4.96	3.45	0.00
UA 5	P1-C1*	20	-0.82	1.40	-1.48	-0.17	-2.63	0.02
	P1-C2	20	-0.28	2.12	-1.27	0.71	-0.59	0.56
	P1-C3	20	0.68	3.04	-0.75	2.10	1.00	0.33
	P2-C1	20	0.77	1.82	-0.08	1.62	1.90	0.07
	P2-C2	20	0.49	2.10	-0.49	1.48	1.05	0.31
	P2-C3	20	1.75	3.80	-0.03	3.53	2.06	0.05

* $P < 0.05$. A positive mean value indicates that the intersection angle of a GPI was larger than that of panoramic radiograph, whereas a negative mean value indicates that it was smaller.




Table 4 Paired sample test for mandibular root inclination between panoramic radiographs and GPIs

Intersection Angle	Methods	N	Mean Difference	Std. Deviation	95% Confidence Interval of the Difference		t	Sig
					Upper	Lower		
LA1	P1-C1	20	0.50	1.98	-0.43	1.42	1.12	0.28
	P1-C2*	20	1.93	1.97	1.01	2.86	4.40	0.00
	P1-C3*	20	4.52	5.23	2.07	6.96	3.87	0.00
	P2-C1*	20	-0.77	1.74	-1.58	0.05	-1.97	0.06
	P2-C2	20	-0.39	1.96	-1.31	0.52	-0.90	0.38
	P2-C3	20	0.52	2.86	-0.82	1.86	0.81	0.43
LA 2	P1-C1*	20	-0.71	1.25	-1.29	-0.12	-2.52	0.02
	P1-C2	20	-0.29	1.14	-0.82	0.25	-1.12	0.28
	P1-C3	20	0.97	3.26	-0.55	2.50	1.33	0.20
	P2-C1*	20	-0.57	1.27	-1.16	0.02	-2.01	0.06
	P2-C2	20	-0.23	1.08	-0.73	0.28	-0.94	0.36
	P2-C3	20	0.04	1.52	-0.67	0.76	0.13	0.90
LA 3	P1-C1	20	-0.32	1.33	-0.95	0.30	-1.09	0.29
	P1-C2	20	0.04	1.02	-0.43	0.52	0.19	0.85
	P1-C3*	20	1.82	2.84	0.49	3.16	2.87	0.01
	P2-C1*	20	-0.79	1.83	-1.65	0.06	-1.94	0.07
	P2-C2*	20	-0.64	1.49	-1.34	0.05	-1.93	0.07
	P2-C3	20	-0.17	1.62	-0.93	0.59	-0.48	0.64
LA 4	P1-C1	20	-0.56	1.50	-1.26	0.15	-1.65	0.12
	P1-C2	20	-0.10	2.04	-1.06	0.85	-0.22	0.83
	P1-C3	20	1.01	2.70	-0.25	2.27	1.67	0.11
	P2-C1	20	-0.60	1.26	-1.19	-0.01	-2.14	0.05
	P2-C2	20	-0.42	1.46	-1.11	0.26	-1.30	0.21
	P2-C3	20	-0.01	1.94	-0.92	0.90	-0.02	0.98
LA 5	P1-C1	20	-1.08	2.25	-2.14	-0.03	-2.15	0.05
	P1-C2	20	0.21	2.75	-1.08	1.49	0.34	0.74
	P1-C3	20	2.39	5.36	-0.12	4.90	1.99	0.06
	P2-C1*	20	-1.95	2.63	-3.18	-0.72	-3.33	0.00
	P2-C2*	20	-1.36	2.30	-2.43	-0.28	-2.65	0.02
	P2-C3	20	-0.72	2.30	-1.79	0.36	-1.40	0.18

* $P < 0.05$. A positive mean value indicates that the intersection angle of a GPI was larger than that of panoramic radiograph, whereas a negative mean value indicates that it was smaller.

Fig 4a For both the maxilla and mandible, the amount of GPIs deviating from panoramic images in mesiodistal root angulation increased from C1 to C3 in P1, with slight deviation between C1 and C2. In P2, the same trend was observed in the maxilla, while the opposite finding was observed for the mandible.

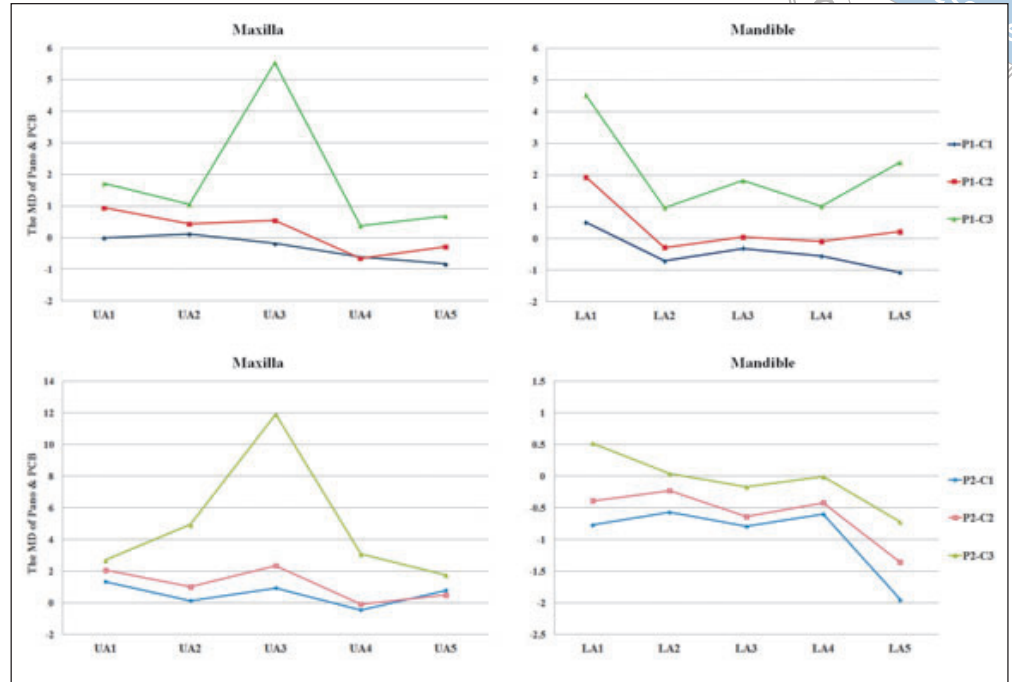
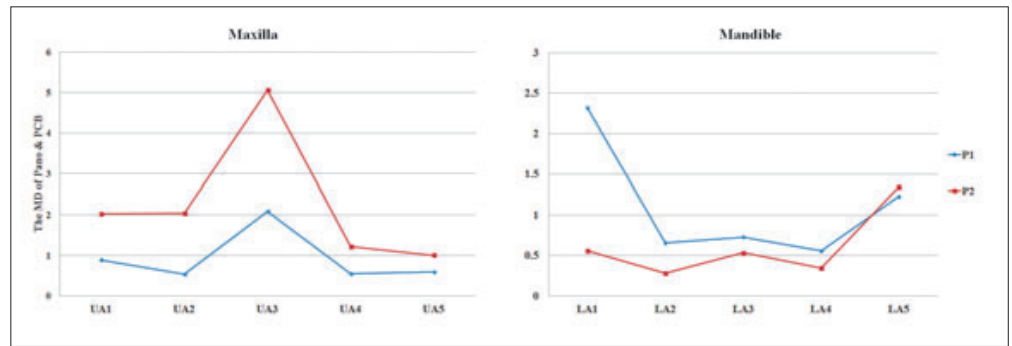


Fig 4b The amount of GPIs deviating from panoramic images in mesiodistal root angulation in the P1 position was smaller than that in the P2 position in the maxilla, while the opposite finding was observed for the mandible.



The primary step in the generation procedure is the adjustment of the head position. Previous studies have focused on variations in the mesiodistal root angulation on panoramic radiograph due to head rotation in the coronal or sagittal direction^{10,18}. Sagittal head rotation was shown to have more of an impact on mesiodistal root angulation than coronal rotation¹⁰. The position of the jaws in relation to the rotation centres, as well as the path of the X-ray beam, may explain such findings¹⁹. As such, two types of sagittal head positions that are generally applicable in orthodontic practice – the Frankfort plane horizontal position and the occlusal plane horizontal position – were applied in this study.

Another important step in the generation procedure is designating the focal trough and its central plane. Panoramic radiograph may be distorted, with the object

shape, size, or position failing to coincide with that of the focal trough. Such distortions apply to patients with abnormal jaws or dental abnormalities, as well as patients who were inaccurately positioned during scans²⁰. Fortunately, CBCT and its generated panoramic images can serve as an effective solution. As Ludlow et al claimed, CBCT, whether it utilises 3D or 2D measurement techniques, is not significantly influenced by variations in skull orientation during image acquisition¹⁵. As such, the negative effect associated with panoramic radiographs resulting from abnormal jaw size or shape, as well as position inaccuracies, can be eliminated by using the individual focal trough in generated panoramic images from CBCT. Moreover, the quality of the panoramic images is influenced by the position of the central plane. “The central plane of focal trough cor-

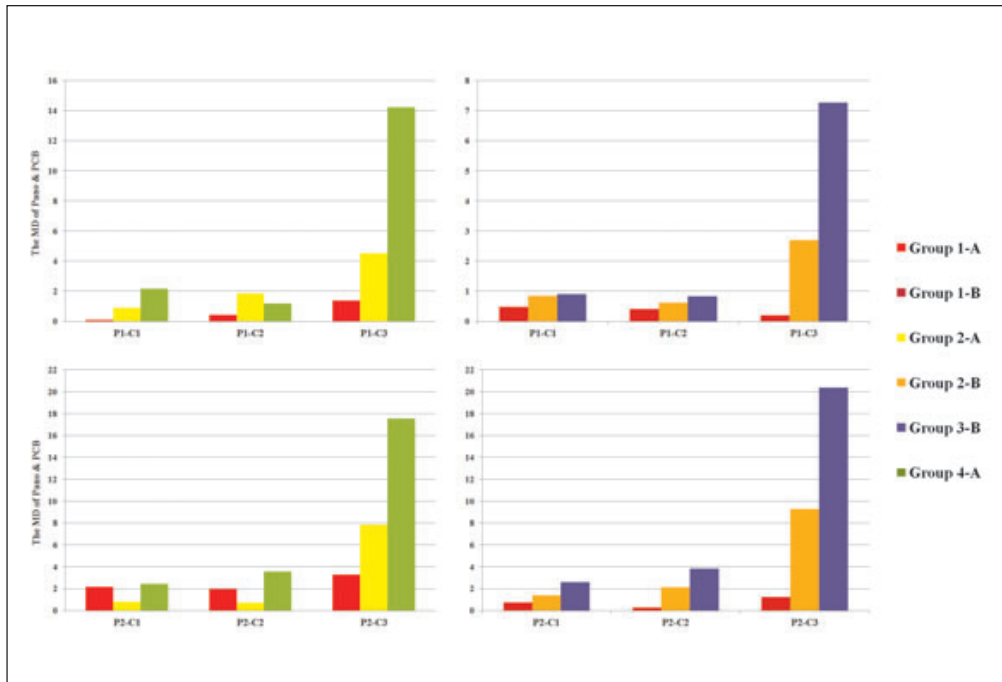


Fig 4c For the maxilla, increasing lingual root inclination of the central incisors correlated with the incremental amount of GPIs deviating from panoramic images in mesiodistal root angulation, indicating a more distal angulation of the bilateral central incisors.

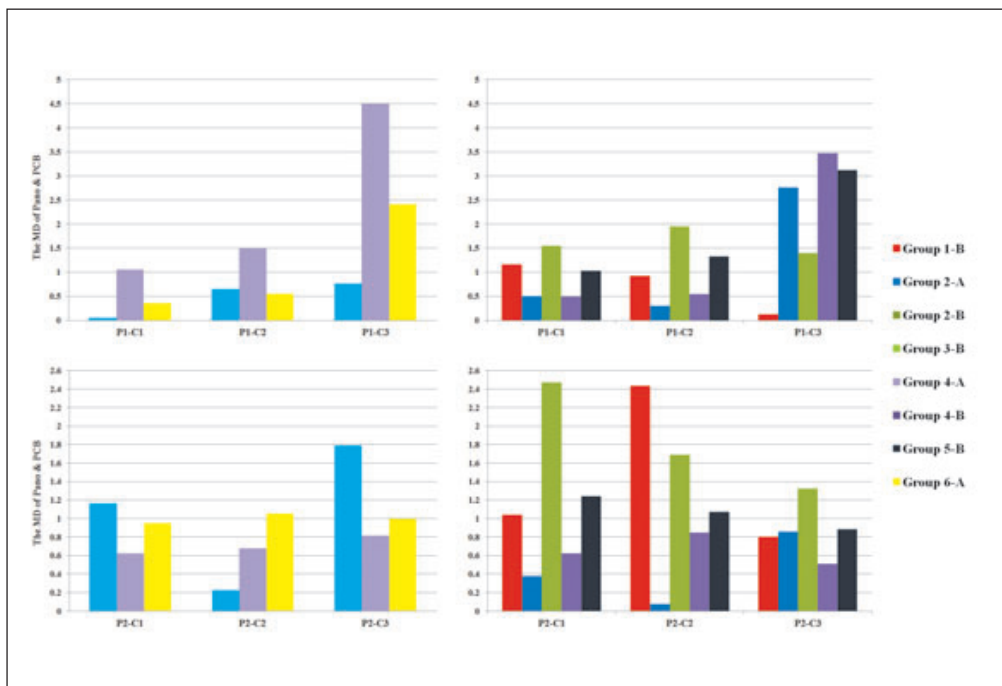


Fig 4d For the mandible, increasing buccal inclination for the central incisors was not obviously correlated with the incremental amount of GPIs deviating from panoramic images in mesiodistal root angulation.

responds to the location within the focal trough where vertical and horizontal magnification factors are equal and where motion ‘unsharpness’ is minimal.”²¹ Paiboon et al reported that any buccolingual errors in object placement related to the central plane would show greater loss of sharpness for lingual errors than for buccal errors²².

The variation between different central planes settings in each head position was compared separately for the maxilla and mandible in this study. In the maxilla, the variation increased as the central plane changed from C1 to C3. This finding is similar to that of Paiboon et al²². In addition to angle deviation, tooth shape distortion can be

Fig 4e In the maxilla's and the mandible's GPIs, the difference between the intersection angles of two head positions were measured. The positive value indicates the intersection angle of P1 was larger than that of P2, whereas a negative mean value indicates the opposite trend. When the A group was compared with the B group, an incremental distal angulation of the anterior tooth can be captured along with the counter clockwise head rotation. However, there was no clear trend in the mandible with such a range of head rotation.

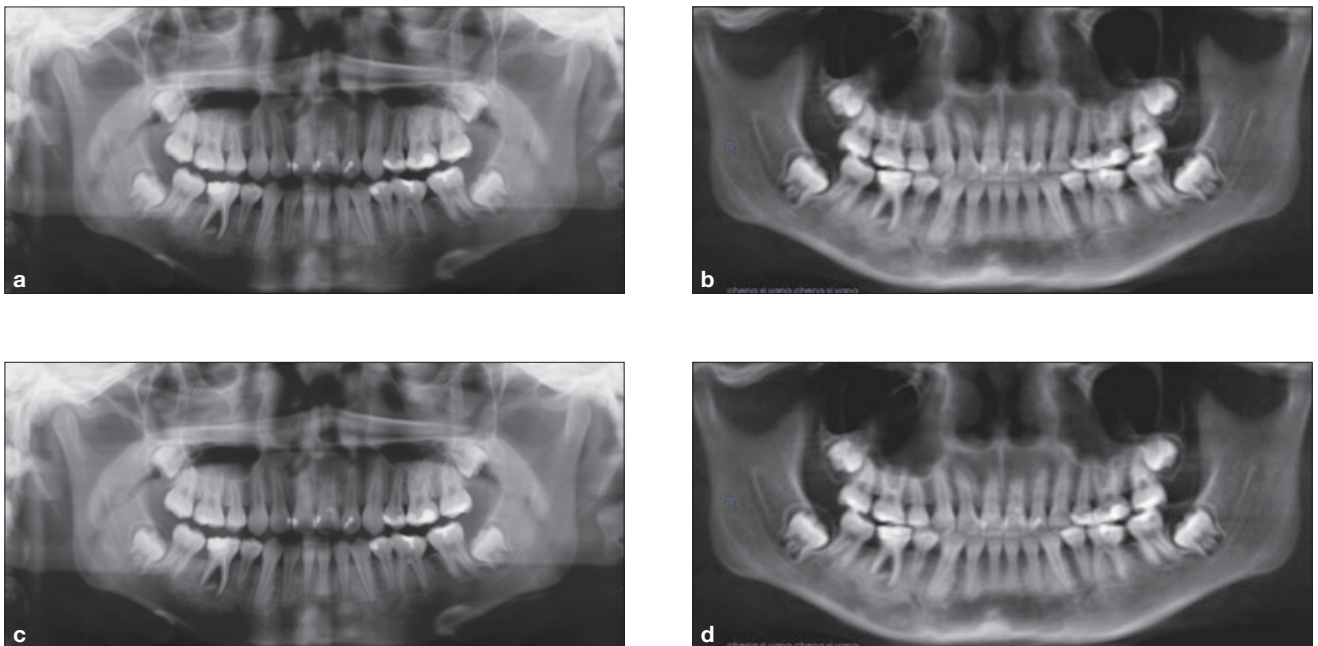
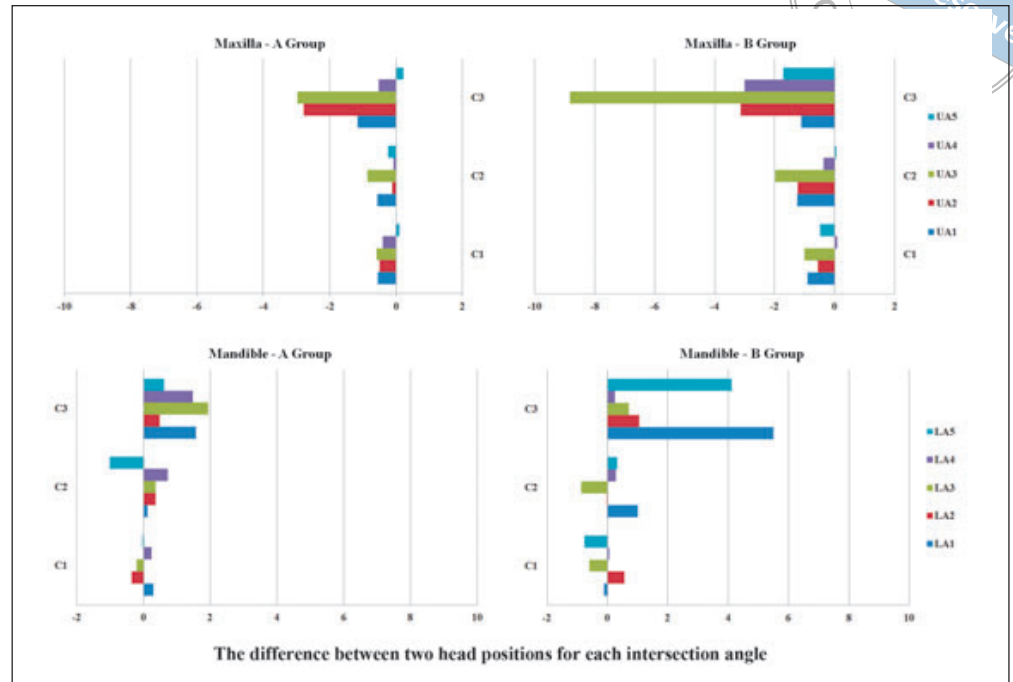



Fig 5 The panoramic radiograph and GPIs generated by various methods. **a** Panoramic radiograph. **b** GPI by P1-C2 method. **c** GPI by P1-C1 method **d** GPI by P1-C3 method.

observed in panoramic images generated under different positions for the central planes. Tooth shape in generated panoramic images using the tooth centre plane is similar to that of the panoramic radiograph. The tooth shape became narrower in panoramic images generated using the root apical plane but broader in panoramic images

generated using the crown marginal plane. Therefore, the tooth centre plane is proposed as the best option during the generation procedure.

When the head was rotated in the counterclockwise direction along the sagittal plane, distal root angulation increased in the maxilla but decreased in the mandi-



ble. The same trends have been reported in previous studies that used a typodont to detect the impact of head rotation on mesiodistal root angulation in panoramic radiograph^{11,18}. Mckee et al reported the same root angulation trends in the maxilla using a 5 degree rotation in both the clockwise and counterclockwise directions along the sagittal plane. In the mandible, however, mesiodistal root angulation variation was not observed in conjunction with this degree of head rotation¹⁸. The study by Harady et al¹¹ utilized more head rotation settings, including 1, 2, 5, 7 and 10 degrees, in which, when the typodont was rotated by 2 degrees, the maxillary teeth revealed a distal angulation. The mandibular teeth, however, failed to show a mesial angulation until the typodont was rotated by 7 degrees. Therefore, the maxillary and mandibular teeth displayed opposite trends, while the maxilla was more sensitive to sagittal head rotation than the mandible. This discrepancy may have resulted from differential buccolingual root inclination between the maxilla and mandible, especially involving anterior teeth. Distal root angulation has been reported to be associated with increasing lingual root inclination¹⁴. The same situation was displayed in this study, especially for the maxilla. Then, is it true that root angulation must have been modified when we assess its variation after orthodontic treatment? The answer should be no. For example, the retraction of proclined incisors may lead to variations in buccolingual root inclination, thereby resulting in variations in mesiodistal root angulation on panoramic radiograph. In such cases, the posttreatment mesiodistal root angulation may actually be the same as the pre-treatment value.

Conclusions

Based on standard operating procedures with proper head position and central plane settings, as introduced in this study, panoramic images from CBCT should be separately generated for the maxilla and the mandible. Furthermore, in the process of generating panoramic images from CBCT, it is suggested to take calibration to both head rotation and incisors' buccolingual root inclination, thereby improving the efficacy of GPIs in the evaluation of mesiodistal root angulation.

References

1. Macleod I, Heath N. Cone-beam computed tomography (CBCT) in dental practice. *Dent Update* 2008;35:590–592, 594–598.
2. Scarfe WC, Farman AG and Sukovic P. Clinical applications of cone-beam computed tomography in dental practice. *J Can Dent Assoc* 2006;72:75–80.
3. Van Elslande D, Heo G, Flores-Mir C et al. Accuracy of mesiodistal root angulation projected by cone-beam computed tomographic panoramic-like images. *Am J Orthod Dentofacial Orthop* 2010;137:S94–99.
4. Kumar V, Ludlow J, Soares Cevidanes LH, et al. In vivo comparison of conventional and cone beam CT synthesized cephalograms. *Angle Orthod* 2008;78:873–879.
5. Nur M, Kayipmaz S, Bayram M, et al. Conventional frontal radiographs compared with frontal radiographs obtained from cone beam computed tomography. *Angle Orthod* 2012;82:579–584.
6. Casco JS, Vaden JL, Kokich VG, et al. Objective grading system for dental casts and panoramic radiographs. *American Board of Orthodontics. Am J Orthod Dentofacial Orthop* 1998;114:589–599.
7. Andrews LF. The six keys to normal occlusion. *Am J Orthod* 1972;62:296–309.
8. Schiff T, D'Ambrosio J, Glass BJ, et al. Common positioning and technical errors in panoramic radiography. *J Am Dent Assoc* 1986;113:422–426.
9. Scarfe WC, Nummikoski P, McDavid WD, et al. Radiographic interproximal angulations: implications for rotational panoramic radiography. *Oral Surg Oral Med Oral Pathol* 1993;76:664–672.
10. Stramotas S, Geenty JP, Petocz P, et al. Accuracy of linear and angular measurements on panoramic radiographs taken at various positions in vitro. *Eur J Orthod* 2002;24:43–52.
11. Hardy TC, Suri L, Stark P. Influence of patient head positioning on measured axial tooth inclination in panoramic radiography. *J Orthod* 2009;36:103–110.
12. Philipp RG, Hurst RV. The cant of the occlusal plane and distortion in the panoramic radiograph. *Angle Orthod* 1978;48:317–323.
13. Garcia-Figueroa MA, Raboud DW, Lam EW, et al. Effect of buccolingual root angulation on the mesiodistal angulation shown on panoramic radiographs. *Am J Orthod Dentofacial Orthop* 2008;134:93–99.
14. Chen H, Xu TM. The analysis of factors affecting the canine angulation in panoramic radiograph [in Chinese]. *Chinese Journal of Orthodontics* 2010;17:17–21.
15. Ludlow JB, Laster WS, See M, et al. Accuracy of measurements of mandibular anatomy in cone beam computed tomography images. *Oral Surg Oral Med Oral Pathol Oral Radiol Endod* 2007;103:534–542.
16. Peck JL, Sameshima GT, Miller A, et al. Mesiodistal root angulation using panoramic and cone beam CT. *Angle Orthod* 2007;77:206–213.
17. Liu Y, Zhao JH, Ding Y, Xu TM. Precision of cephalometric landmark identification from cone-beam computed tomography [in Chinese]. *Chinese Journal of Orthodontics* 2010;17:61–65.
18. Mckee IW, Glover KE, Williamson PC, et al. The effect of vertical and horizontal head positioning in panoramic radiography on mesiodistal tooth angulations. *Angle Orthod* 2001;71:442–451.
19. Sanderink GC, Visser WN, Kramers EW. The origin of a case of severe image distortion in rotational panoramic radiography. *Dentomaxillofac Radiol* 1991;20:169–171.
20. Liang H, Frederiksen NL. Focal trough and patient positioning. *Dentomaxillofac Radiol* 2004;33:128–129.
21. Lannucci JM and Howerton LJ. *Dental Radiography, Principles and Techniques*, ed 4. St Louis: Elsevier Saunders, 2011.
22. Paiboon C, Manson-Hing LR. Effect of border sharpness on the size and position of the focal trough of panoramic x-ray machines. *Oral Surg Oral Med Oral Pathol* 1985;60:670–676.