

# Oral Squamous Cell Carcinoma – Progresses from Risk Assessment to Treatment

Li MAO<sup>1</sup>

*Oral squamous cell carcinoma (OSCC) is the most common cancer type in head and neck with approximately 500,000 new cases diagnosed each year worldwide. Advances have been made from cancer risk assessment to treatment. However, the clinical impact of these advances has been modest so far. With an increased understanding of genetic and epigenetic features in oral tumorigenesis, novel biomarkers have emerged and been tested for their potential use in assessing oral cancer risk and OSCC classification. New therapeutic strategies targeting molecules critical for OSCC maintenance and progression have shown promise. This article provides a general picture of the current status in the field of OSCC clinical and translational research for the oral health community.*

**Key words:** oral squamous cell carcinoma, risk assessment, treatment

Oral squamous cell carcinoma (OSCC) is one of the most common cancer types in the world, with an estimated incidence of more than 500,000 cases worldwide. In the United States alone, it is estimated that 40,250 people, including 28,540 men and 11,710 women will be diagnosed with OSCC in 2012, representing 2.5% of all newly diagnosed cancers and 1.4% of cancer-related deaths<sup>1</sup>. In addition to death, OSCC is associated with tremendous disease- and treatment-related morbidity and has a 5-year survival rate of approximately 50%, a rate almost unchanged in the past decades<sup>2</sup>.

OSCC is a complex disease arising in various anatomic locations, including the oral cavity and pharynx. Tumours from these different sites have distinct clinical presentations and clinical outcomes, and are treated with different strategies, with either single treatments or a combination of surgery, radiotherapy, and chemotherapy. With increased understanding of molecular

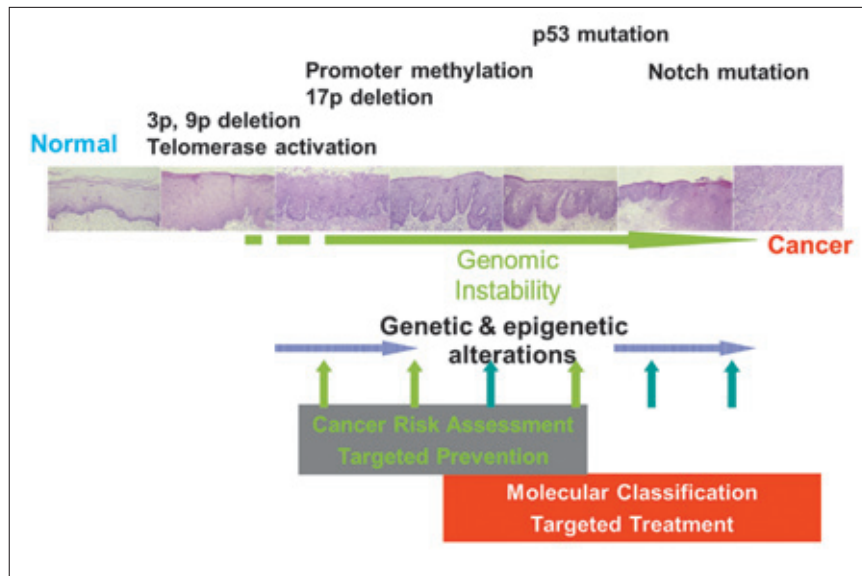
mechanisms in oral tumorigenesis, novel strategies have been developed for early detection, classification, prevention, and treatment of OSCC.

Tobacco consumption and alcohol drinking are two of the key risk factors for development of OSCC<sup>3</sup>. However, the exact mechanisms by which tobacco carcinogens and alcohol induce transformation and malignant progression of epithelial cells in the oral cavity are not fully understood because most of the tobacco and alcohol users do not develop OSCC in their lifetimes. Additionally, approximately 20% of OSCC patients, particularly females and those with younger ages have no tobacco use and alcohol drinking history. These observations underscore the complexity of oral tumorigenesis and the importance of gene-environment interactions in OSCC development.

Like other epithelial cancers, OSCC is a result of the accumulation of multiple genetic and epigenetic alterations, which takes years or decades (Fig 1). These alterations include deletion of tumour suppressor genes, inactivation mutations of tumour suppressor genes, de novo promoter methylation of tumour suppressor genes, and amplification or overexpression of oncogenes. Many of these alterations occur in the early process and can be detected in so-called oral premalignant lesions (OPLs) and even in histologically normal airway epithelium chronically exposed to tobacco carcinogens<sup>4-6</sup>.

<sup>1</sup> Department of Oncology and Diagnostic Sciences, School of Dentistry and Greenebaum Cancer Center, University of Maryland, Baltimore, Maryland, USA.

**Corresponding author:** Dr Li MAO, Department of Oncology and Diagnostic Sciences, School of Dentistry and Greenebaum Cancer Center, University of Maryland, Baltimore, 650 West Baltimore Street, Baltimore, Maryland 21201, USA. E-mail: lmao@umaryland.edu



**Fig 1** Multistep process of oral tumorigenesis. Multiple genetic and epigenetic alterations accumulate in oral epithelial cells leading to malignant transformation and progression. Identifying and characterising these alterations can accelerate biomarker development to assess cancer risk and classify tumours. It can also provide molecular targets for personalised prevention and treatment.

Further characterisation of the molecular processes underlining OSCC development will be essential for the development of novel strategies from cancer risk assessment to targeted treatment.

### Aetiology

Epidemiological studies build a strong link between the use of tobacco and development of OSCC. Alcohol is another independent risk factor of OSCC and plays a synergistic role when used together with tobacco. The risk of developing OSCC increases up to ninefold in heavy smokers and may increase as much as 100-fold in heavy smokers who also drink heavily, compared to those who neither smoke nor drink<sup>7</sup>. Mutations of p53 have been found more frequently in OSCC of smokers and drinkers than in those of other patients<sup>8</sup>, suggesting that inactivation of the p53 tumour suppressor gene is important in tobacco and alcohol related OSCC. However, such association is not always strong in large prospective clinical studies<sup>9</sup>, in part probably due to quality of data collected from the participants.

Human papillomavirus (HPV) has become a key aetiology factor of OSCC, particularly for tumours located at the oropharynx; almost half of the oropharyngeal cancers may be the result of HPV infection<sup>10,11</sup>. The prevalence of HPV infection in the oral cavity is almost 7% in the US population between the ages of 14 and 69 years based on a recent study<sup>12</sup>. It is estimated that if the current trend continues, the number of HPV-induced OSCC cases might surpass the annual number of cervi-

cal cancer cases by 2020<sup>13</sup>. Mechanistically, because the E6 protein produced by the oncogenic high-risk types of HPV, such as HPV-16 and HPV-18, can bind to p53 protein to accelerate its degradation, thereby limiting the protein's ability to inhibit cell proliferation, it can induce apoptosis, and prevent accumulation of substantial genetic damage. Thus, HPV-induced OSCC rarely carries p53 mutations due to the mechanism of the E6-protein<sup>11,14</sup>, which supports the role of HPV in the development of a subset of OSCC.

Other risk factors for OSCC include: poor hygiene in the oral cavity; environmental contaminants such as paint fumes, plastic by-products, and gasoline fumes; gastro-oesophageal reflux; certain diets; and use of marijuana. In patients with OSCC who lack clear exposure to the common aetiological factors, the identification of hidden factors will be critical for developing strategies to prevent and treat the disease.

### Histological and clinical classification

OSCC is graded histologically as well, moderately, or poorly differentiated carcinoma. Well-differentiated tumours contain orderly stratification and heavy keratinisation in a pear formation. Moderately differentiated tumours have prickle cells, some stratification, and less keratinisation. Poorly differentiated tumours are still recognisable as squamous cell carcinomas but manifest prominent nuclear pleomorphisms and atypical mitosis. Although the histologic differentiation status is required in pathology reports of OSCC, it provides limited infor-

mation to surgeons and oncologists to guide their treatment decisions because such differentiation status does not relate to treatment responses and clinical outcomes.

The anatomic location of OSCC is, however, an important factor in treatment decision consideration because tumours arising from different locations often have distinct clinical outcomes and responses to treatment regimens. For example, tumours in the hypopharynx have a higher probability to metastasize compared to tumours in the oral cavity. Tumours at the oropharyngeal site, particularly with HPV positivity, are sensitive to chemoradiotherapy with very high cure rates<sup>15</sup>.

The TNM staging system can provide clinically useful information to clinicians to guide treatment selection. The survival rates of patients with OSCC are strongly associated with TNM stages. The system is based on tumour size and invasion features (T stage), regional lymph node spread (N stage), and the presence of distant metastasis (M stage). However, patients classified in the same stage may have very different responses to the same treatment and different clinical outcomes, indicating the limitation for the clinical staging system and calling for better, probably molecularly based classification systems in the future.

### Molecular basis of OSCC

Deletion in one of the two alleles at chromosomes 3p (multiple regions) and 9p21 is the most frequent genetic alterations in oral premalignant lesions with only mild histologic changes, such as hyperplasia and mild dysplasia, and even in some normal appearing epithelial cells<sup>4</sup>. Because these chromosomal regions harbor tumor suppressor genes, such as FHIT at 3p14 and p16<sup>INK4a</sup> at 9p21, such deletions might promote malignant transformation. This theory is supported by the observation that the lesions of oral leukoplakia with deletions at 3p14 and 9p21 carry a higher risk for transformation into invasive OSCC<sup>4,16,17</sup>. Oral leukoplakia is the most common head and neck premalignant lesion and has malignant transformation rates at 23% to 24% consistently observed in prospective studies<sup>18,19</sup>.

However, our ability to predict the malignant potential of these lesions based on pathologic findings is very limited. Because a number of molecular alterations exist in these lesions, it is plausible that these alterations, if they can be consistently measured, may serve as parameters (biomarkers) to better predict the cancer risk of these lesions.

A critical, probably essential, event that occurred in the early oral tumorigenic process is the reactivation of telomerase<sup>20,21</sup>. More than 90% of OSCCs have activat-

ed telomerase activity and such activation can be traced to epithelial cells with dysplastic changes. Because telomerase can elongate telomeres that shorten after each cell division, the reactivation will allow the cells to divide indefinitely providing time for the cells to accumulate multiple genetic/epigenetic abnormalities.

Califano et al analysed head and neck lesions at various stages of tumorigenesis and developed a progression model based on DNA deletions at multiple chromosomal regions<sup>22</sup>. The most common mutations found in OSCC are in p53 tumour suppressor genes with a frequency of about 50%<sup>8,23</sup>. Inactivation of p53 makes OSCC more resistant to radiotherapy and oral premalignancies less sensitive to retinoid-based chemopreventive strategies<sup>24,25</sup>. Recently, using the next generation sequencing methods, two research groups simultaneously reported the identification of Notch1 mutations in almost 20% of head and neck squamous cell carcinomas<sup>26,27</sup>. Based on the types of mutations, investigators suggest that Notch may be inactivated in these cancers and play a role as a tumour suppressor<sup>26</sup>.

Gene amplification and protein overexpression can be detected in OSCC. Cyclin D1, for example, is frequently amplified and overexpressed in early stage oral tumorigenesis<sup>28</sup>. Overexpression of epidermal growth factor receptor (EGFR) is another example and has been the basis for targeting as therapeutic and preventive strategies<sup>29-31</sup>. p63, a p53 homolog with oncogenic property, is also frequently amplified and overexpressed in OSCC<sup>32</sup>.

Gene expression silencing by promoter hypermethylation is another common mechanism to inactivate tumour suppressor genes in OSCC development<sup>33,34</sup>. Aberrant pre-mRNA splicing is another epigenetic mechanism that may inactivate tumour suppressor genes and generate oncogenes<sup>35</sup>.

Many of these molecular abnormalities, particularly DNA deletions and amplifications, are the consequence of genomic instability. Understanding the mechanism for genomic instability may lead to novel preventive or therapeutic strategies, preventing or minimizing genomic instability.

### Field cancerisation and multiple tumours

The concept of field cancerisation was introduced to explain why multiple primary tumours can develop in the upper aerodigestive tract<sup>36</sup>. There are recent debates regarding the concept because some clinically diagnosed second primary tumours distant from the original (index) tumours carry clonal genetic traces of the index lesions<sup>37</sup>. We further analysed a large cohort with mul-

multiple oral premalignant lesions (OPLs) or OSCC and found that clonal genetic changes occurred in both invasive and noninvasive lesions, although the probability of clonal changes increased with tumor progression. However, some multiple oral lesions developed independently, which supports the role of field cancerisation in multiple OPLs and OSCC<sup>38</sup>.

### Cancer risk assessment and prevention

The development of OSCC requires accumulation of multiple genetic and epigenetic alterations. Therefore, many of these alterations may serve as biomarkers in cancer risk assessment and/or targets for cancer prevention.

Biomarkers show a great promise in improving cancer risk assessment and early diagnosis. We have shown that loss of heterozygosity can be used as a predictive marker for oral cancer risk<sup>4</sup>, which has been recently validated in a large-scale prospective clinical trial<sup>17</sup>. Various other methods have also been used to develop predictive biomarkers. Using these methods, we have developed a panel of biomarkers from single protein biomarker to genetic and epigenetic marker panels to assess individuals' oral cancer risk<sup>39–43</sup>.

Previously, high-dose retinoids have shown efficacy in the reversal of early OPLs, but are associated with considerable toxicities<sup>44</sup>. The efficacy of retinoids on moderately and severely dysplastic lesions were addressed with a combination of interferon- $\alpha$ ,  $\alpha$ -tocopherol, and 13-cis-retinoic acid<sup>45</sup>. However, the activity of this combination in reversing histology OPLs did not result in an elimination of clones with genetic abnormalities leading to a high relapse<sup>46</sup>, which highlights the potential role of genetic markers in assessing treatment responses. The possibility of preventing second primary tumours has also been suggested based on a randomised, double-blinded, placebo-controlled trial of high-dose 13-cis-retinoic acid clinical trial for patients with head and neck squamous cell carcinoma<sup>47</sup>. However, these results were not confirmed by studies with low-dose 13-cis-retinoic acid<sup>48</sup> or with different retinoids<sup>49</sup>. Some new strategies have also been tested, such as targeting p53 abnormalities, selective cyclooxygenase-2 inhibitors, EGFR kinase inhibitors, and the extracts of green tea.

### Treatment strategies

The major treatments for OSCC have always been surgery, radiotherapy, and chemotherapy. In surgery, the focus has been in organ conservation and more effective reconstruction. In radiotherapy, high-dose fraction approaches and intensity-modulated radiation therapy

(IMRT) have been introduced to increase treatment efficacy and reduce toxicities<sup>50,51</sup>. Increasingly, treatment strategies have incorporated chemotherapy as an integral component of potentially curative therapy aimed at organ preservation, optimal disease control, quality of life, and survival improvement. Induction chemotherapy followed by radiotherapy and the concurrent chemotherapy and radiotherapy have been actively investigated. The rationale for these approaches lie in its potential to overcome radiation resistance within the irradiated field and to eliminate metastatic cancer cells. A meta-analysis that included 63 randomised studies conducted between 1965 and 1993 showed an absolute survival benefit of 4% at 5 years with the addition of chemotherapy to locoregional treatment. The survival benefit was confined to trials that compared concomitant chemoradiotherapy with radiotherapy alone (absolute survival benefit for chemoradiotherapy, 8% at 5 years)<sup>52</sup>. Results from several phase III studies uniformly support the superiority of concurrent chemoradiotherapy over radiation alone in the setting of unresectable head and neck cancer<sup>2</sup>. The potential use of multiagent chemoradiotherapy has been investigated with satisfactory results<sup>53,54</sup>.

In the setting of recurrent and metastatic disease, single agents with activity in the range of 15% to 30% include methotrexate, cisplatin, carboplatin, 5-fluorouracil, paclitaxel, and docetaxel. Combination chemotherapy has been shown to result in significantly higher response rates than those achieved by single-agent chemotherapy. The combination of cisplatin and 5-fluorouracil given by continuous intravenous infusion is the most frequently used regimen<sup>2</sup>, although it has resulted in no improvement in the median duration of survival of 6 months or in the overall survival rates. Similarly, randomised trials directly comparing newer regimens, such as paclitaxel or docetaxel plus cisplatin or carboplatin, with the standard cisplatin and 5-fluorouracil regimen have not shown superiority in terms of survival rate.

New treatment strategies for OSCC have centred on patients with recurrent and metastatic disease. These new drugs, designed to target specific molecular defects unique to the cancer cells, such as tyrosine kinase inhibitors (TKIs) and mammalian target of rapamycin (mTOR) inhibitors.

EGFR is overexpressed more than 80% OPLs and the overexpression is generally associated with an adverse outcome<sup>55</sup>. EGFR is a member of the ErbB receptor tyrosine kinase family; its ligands EGF and TGF- $\alpha$  may cause receptor dimerisation leading to activation of signal transduction pathways through phosphorylation of the receptor tyrosine kinases and their substrates, which can result in cell proliferation, tumour growth, and inva-

sion and metastasis<sup>56</sup>. Several strategies to inhibit the EGFR pathway have been developed, including the use of TKIs, antibodies, ligand-linked toxins, and antisense oligonucleotides<sup>57</sup>. Cetuximab, a monoclonal antibody, has been shown to cause response in 10% to 14% of platinum-resistant patients with head and neck cancer when the antibody was added to a regimen of cisplatin or carboplatin after documented progression of the disease<sup>57</sup>. In a phase III clinical trial, adding cetuximab to radiotherapy improved locoregional control and the overall survival in patients with head and neck squamous cell carcinoma<sup>58</sup> leading to a regulatory approval of using this regimen for patients with locally advanced head and neck squamous cell carcinoma. It appears that patients with above moderate cetuximab-induced skin rash had a better treatment outcome than those with mild skin reactions<sup>59</sup>. Reversible and irreversible TKIs have also been tested in clinical trials – alone and in combination with chemotherapy. Gefitinib and erlotinib are reversible TKIs that have been approved to use in patients with advanced non-small cell lung cancer. Phase II studies of both compounds have been completed in patients with recurrent and metastatic head and neck squamous cell carcinoma and have found that the drugs are tolerable<sup>60,61</sup>. Additionally, trials will be needed to determine whether such regimens may improve clinical outcomes. Some additional targets currently in clinical development for patients with OSCC include mTOR inhibitors, insulin-like growth factor-signalling blockers, histone deacetylase inhibitors, and heat shock protein 90 inhibitors.

## Summary

Progress in treatment of OSCC has been slow and challenging. However, a number of studies have established the feasibility and efficacy of combining treatment modalities to enable organ preservation and have laid the framework for circumvention of the treatment plateau encountered with conventional cytotoxic agents through the integration of molecularly targeted agents. Development of molecular markers to predict high-risk individuals for developing OSCC and the use of these markers in clinical prevention trials has made considerable progress. The challenges that lie ahead include building large prospective cohorts for biomarker validation trials, the development of effective chemoprevention and therapeutic agents/regimens, the choice of the appropriate setting for using biologically active agents targeting actions different pathways of tumour growth, and, most important, the timely integration of laboratory-based studies and molecular imaging into the development of new treatments.

## References

1. Siegel R, Naishadham D, Jemal A. Cancer Statistics, 2012. *CA Cancer J Clin* 2012;62:10–29.
2. Forastiere A, Koch W, Trotti, Sidransky D. Head and neck cancer. *N Engl J Med* 2001;345:1890–1900.
3. Decker J, Goldstein JC. Risk factors in head and neck cancer. *N Engl J Med* 1982;306:1151–1155.
4. Mao L, Lee JS, Fan YH, Ro JY, Batsakis JG, Lippman S et al. Frequent microsatellite alterations at chromosomes 9p21 and 3p14 in oral premalignant lesions and their value in cancer risk assessment. *Nat Med* 1996;2:682–685.
5. Mao L, Lee JS, Kurie JM et al. Clonal genetic alterations in the lungs of current and former smokers. *J Natl Cancer Inst* 1997;89:857–862.
6. Wistuba II, Lam S, Behrens C, Virmani AK, Fong KM, LeRiche J et al. Molecular damage in the bronchial epithelium of current and former smokers. *J Natl Cancer Inst* 1997;89:1366–1373.
7. Neville BW, Day TA. Oral cancer and precancerous lesions. *CA Cancer J Clin* 2002;52:195–215.
8. Brennan JA, Boyle JO, Koch WM, Goodman SN, Hruban RH, Eby YJ et al. Association between cigarette smoking and mutation of the p53 gene in squamous-cell carcinoma of the head and neck. *N Engl J Med* 1995;332:712–717.
9. Poeta ML, Manola J, Goldwasser MA, Forastiere A, Benoit N, Califano JA et al. TP53 mutations and survival in squamous-cell carcinoma of the head and neck. *N Engl J Med* 2007;357:2552–2561.
10. Gillison ML, Koch WM, Capone RB, Spafford M, Westra WH, Wu L et al. Evidence for a causal association between human papillomavirus and a subset of head and neck cancers. *J Natl Cancer Inst* 2000;92:709–720.
11. Gillison ML, D'Souza G, Westra W et al. Distinct risk factor profiles for human papillomavirus type 16-positive and human papillomavirus type 16-negative head and neck cancers. *J Natl Cancer Inst* 2008;100:407–420.
12. Gillison ML, Broutian T, Pickard RK et al. Prevalence of oral HPV infection in the United States, 2009–2010. *JAMA* 2012;307:693–703.
13. Chaturvedi AK, Engels EA, Pfeiffer RM et al. Human papillomavirus and rising oropharyngeal cancer incidence in the United States. *J Clin Oncol* 2011;29:4294–4301.
14. Mork J, Lie AK, Glatte E et al. Human papillomavirus infection as a risk factor for squamous-cell carcinoma of the head and neck. *N Engl J Med* 2001;344:1125–1131.
15. Ang KK, Harris J, Wheeler R et al. Human papillomavirus and survival of patients with oropharyngeal cancer. *N Engl J Med* 2010;363:24–35.
16. Rosin MP, Cheng X, Poh C et al. Use of allelic loss to predict malignant risk for low-grade oral epithelial dysplasia. *Clin Cancer Res* 2000;6:357–362.
17. Zhang L, Poh CF, Williams M et al. Loss of heterozygosity (LOH) profiles – validated risk predictors for progression to oral cancer. *Cancer Preven Res (Phila)* 2012;5:1081–1089.
18. Papadimitrakopoulou VA, Hong WK, Lee JS et al. Low-dose isotretinoin versus beta-carotene to prevent oral carcinogenesis: long-term follow-up. *J Natl Cancer Inst* 1997;89:257–258.
19. Papadimitrakopoulou VA, Lee JJ, William WN et al. Randomized trial of 13-cis retinoic acid compared with retinyl palmitate with or without beta-carotene in oral premalignancy. *J Clin Oncol* 2009;27:599–604.
20. Mao L, El-Naggas AK, Fan YH et al. Telomerase activity in head and neck squamous cell carcinoma and adjacent tissues. *Cancer Res* 1996;56:5600–5604.
21. Mutirangura A, Supiyaphun P, Trirekanan S et al. Telomerase activity in oral leukoplakia and head and neck squamous cell carcinoma. *Cancer Res* 1996;56:3530–3533.
22. Califano J, van der Riet P, Westra W et al. Genetic progression model for head and neck cancer: implications for field cancerization. *Cancer Res* 1996;56:2488–2492.

23. Poeta ML, Manola J, Goldwasser MA et al. TP53 mutations and survival in squamous-cell carcinoma of the head and neck. *N Engl J Med* 2007;357:2552-2561.
24. Koch WM, Brennan JA, Zahurak M et al. p53 mutation and locoregional treatment failure in head and neck squamous cell carcinoma. *J Natl Cancer Inst* 1996;88:1580-1586.
25. Shin DM, Mao L, Papadimitrakopoulou VM et al. Biochemopreventive therapy for patients with premalignant lesions of the head and neck and p53 gene expression. *J Natl Cancer Inst* 2000;92:69-73.
26. Agrawal N, Frederick MJ, Pickering CR et al. Exome sequencing of head and neck squamous cell carcinoma reveals inactivating mutations in NOTCH1. *Science* 2011;333:1154-1157.
27. Stransky N, Egloff AM, Tward AD et al. The mutational landscape of head and neck squamous cell carcinoma. *Science* 2011;333:1157-1160.
28. Izzo JG, Papadimitrakopoulou VA, Liu DD et al. Cyclin D1 genotype, response to biochemoprevention, and progression rate to upper aerodigestive tract cancer. *J Natl Cancer Inst* 2003;95:198-205.
29. Pomerantz RG, Grandis JR. The role of epidermal growth factor receptor in head and neck squamous cell carcinoma. *Curr Oncol Rep* 2003;5:140-146.
30. Mao L, William WN Jr, Lee JJ et al. Genetic markers for selecting high-risk population with oral premalignancy for the erlotinib prevention of oral cancer (EPOC) trial. National Cancer Institute Translational Science Meeting, 2008.
31. William WN Jr, Heymach JV, Kim ES et al. Molecular targets for cancer chemoprevention. *Nat Rev Drug Discov* 2009;8:213-225.
32. Patturajan M, Nomoto S, Sommer M et al. DeltaNp63 induces beta-catenin nuclear accumulation and signaling. *Cancer Cell* 2002;1:369-379.
33. Herman JG, Baylin SB. Gene silencing in cancer in association with promoter hypermethylation. *N Engl J Med* 2003;349:2042-2054.
34. Hasegawa M, Nelson HH, Peters E et al. Patterns of gene promoter methylation in squamous cell cancer of the head and neck. *Oncogene* 2002;21:4231-4236.
35. Mao L, Fan YH, Lotan R et al. Frequent abnormalities of FHIT, a candidate tumor suppressor gene, in head and neck cancer cell lines. *Cancer Res* 1996;56:5128-5131.
36. Slaughter DP, Southwick HW, Smejkal W. Field cancerization in oral stratified squamous epithelium: Clinical implications of multicentric origin. *Cancer* 1953;6:963-968.
37. Bedi G, Westra W, Gabrielson E et al. Multiple head and neck tumors: evidence for a common clonal origin. *Cancer Res* 1996;56:2484-2487.
38. Jang SJ, Chiba I, Hirai A et al. Multiple oral squamous epithelial lesions: are they genetically related? *Oncogene* 2001;20:2235-2242.
39. Sidransky D, Irizarry R, Califano JA et al. Serum protein MALDI profiling to distinguish upper aerodigestive tract cancer patients from control subjects. *J Natl Cancer Inst* 2003;95:1711-1717.
40. Kawaguchi H, El-Naggar AK, Papadimitrakopoulou V et al. Podoplanin: a novel marker for oral cancer risk in patients with oral premalignancy. *J Clin Oncol* 2008;26:354-360.
41. Saintigny P, El-Naggar A, Papadimitrakopoulou V et al. DeltaNp63 overexpression, alone and in combination with other biomarkers, predicts the development of oral cancer in patients with leukoplakia. *Clin Cancer Res* 2009;15:6284-6291.
42. Taoudi Benchekroun M, Saintigny P, Thomas SM et al. Epidermal growth factor receptor expression and gene copy number in the risk of oral cancer. *Cancer Prev Res (Phila)* 2010;3:800-809.
43. Saintigny P, Zhang L, Fan YH et al. Gene expression profiling predicts the development of oral cancer. *Cancer Prev Res (Phila)* 2011;4:218-229.
44. Hong WK, Endicott J, Itri LM et al. 13-cis-retinoic acid in the treatment of oral leukoplakia. *N Engl J Med* 1986;315:1501-1505.
45. Papadimitrakopoulou VA, Clayman GL, Shin DM et al. Biochemoprevention for dysplastic lesions of the upper aerodigestive tract. *Arch Otolaryngol. Arch Otolaryngol Head Neck Surg* 1999;125:1083-1089.
46. Mao L, El-Naggar A.K, Papadimitrakopoulou V et al. Phenotype and genotype of advanced premalignant head and neck lesions after chemopreventive therapy. *J Natl Cancer Inst* 1998;90:1545-1551.
47. Hong WK, Lippman SM, Itri LM et al. Prevention of second primary tumors with isotretinoin in squamous-cell carcinoma of the head and neck. *N Engl J Med* 1992;323:795-801.
48. Khuri FR, Lee JJ, Lippman SM et al. Randomized phase III trial of low-dose isotretinoin for prevention of second primary tumors in stage I and II head and neck cancer patients. *J Natl Cancer Inst* 2006;98:441-450.
49. van Zandwijk N, Dalesio O, Pastorino U et al. EUROSCAN, a randomized trial of vitamin A and N-acetylcysteine in patients with head and neck cancer or lung cancer. For the European Organization for Research and Treatment of Cancer Head and Neck and Lung Cancer Cooperative Groups. *J Natl Cancer Inst* 2000;92:977-986.
50. Fu KK, Pajak TF, Trotti A et al. A Radiation Therapy Oncology Group (RTOG) phase III randomized study to compare hyperfractionation and two variants of accelerated fractionation to standard fractionation radiotherapy for head and neck squamous cell carcinomas: first report of RTOG 9003. *Int J Radiat Oncol Biol Phys* 2000;48:7-16.
51. Bourhis J, Sire C, Graff P et al. Concomitant chemoradiotherapy versus acceleration of radiotherapy with or without concomitant chemotherapy in locally advanced head and neck carcinoma (GORTEC 99-02): an open-label phase 3 randomised trial. *Lancet Oncol* 2012;13:145-153.
52. Pignon JP, Bourhis J, Domenge C et al. Chemotherapy added to locoregional treatment for head and neck squamous-cell carcinoma: three meta-analyses of updated individual data. MACH-NC Collaborative Group. Meta-Analysis of Chemotherapy on Head and Neck Cancer. *Lancet* 2000;355:949-955.
53. Kies MS, Haraf DJ, Rosen F et al. Concomitant infusional paclitaxel and fluorouracil, oral hydroxyurea, and hyperfractionated radiation for locally advanced squamous head and neck cancer. *J Clin Oncol* 2001;19:1961-1969.
54. Salama JK, Haraf DJ, Stenson KM et al. A randomized phase II study of 5-fluorouracil, hydroxyurea, and twice-daily radiotherapy compared with bevacizumab plus 5-fluorouracil, hydroxyurea, and twice-daily radiotherapy for intermediate-stage and T4N0-1 head and neck cancers. *Ann Oncol* 2011;22:2304-2309.
55. Rubin Grandis J, Melhem MF, Gooding WE et al. Levels of TGF-alpha and EGFR protein in head and neck squamous cell carcinoma and patient survival. *J Natl Cancer Inst* 1998;90:824-832.
56. Salomon DS, Brandt R, Ciardiello F et al. Epidermal growth factor-related peptides and their receptors in human malignancies. *Crit Rev Oncol Hematol* 1995;19:183-232.
57. Mendelsohn J, Baselga J. Status of epidermal growth factor receptor antagonists in the biology and treatment of cancer. *J Clin Oncol* 2003;21:2787-2799.
58. Bonner JA, Harari PM, Giralt J et al. Radiotherapy plus cetuximab for squamous-cell carcinoma of the head and neck. *N Engl J Med* 2006;354:567-578.
59. Bonner JA, Harari PM, Giralt J et al. Radiotherapy plus cetuximab for locoregionally advanced head and neck cancer: 5-year survival data from a phase 3 randomised trial, and relation between cetuximab-induced rash and survival. *Lancet Oncol* 2010;11:21-28.
60. Siu LL, Soulieres D, Chen EX et al. Phase I/II trial of erlotinib and cisplatin in patients with recurrent or metastatic squamous cell carcinoma of the head and neck: a Princess Margaret Hospital phase II consortium and National Cancer Institute of Canada Clinical Trials Group Study. *J Clin Oncol* 2007;25:2178-2183.
61. Saarialhti K, Bono P, Kajanti M et al. Phase II prospective trial of gefitinib given concurrently with cisplatin and radiotherapy in patients with locally advanced head and neck cancer. *J Otolaryngol Head Neck Surg* 2010;39:269-276.