

Diverse Growth Patterns in an Intraosseous Ameloblastoma: A Case Report

Swetha ACHARYA¹, Anila KONERU¹, Niranjan Kochli CHANNAPPA¹,
Rekha KRISHNAPILLAI¹

Desmoplastic ameloblastoma (DA) is a benign but locally invasive variant of the solid/multicystic ameloblastoma (SMA). In the recent World Health Organization classification of odontogenic tumours, DA has been characterised as a variant, with specific clinical, radiographic and histopathological features. A possible 'transitional' form of DA, showing microscopic features of the desmoplastic variant together with areas typical of classic follicular or plexiform ameloblastoma, has been described as a 'hybrid' lesion of ameloblastoma (HLA). A unique case with synchronous emergence of desmoplastic and unicystic ameloblastoma (different growth patterns) in the mandible of a 50-year-old male is reported.

Key words: desmoplastic ameloblastoma, growth pattern, mandible, unicystic ameloblastoma

The first detailed report on the desmoplastic variant of ameloblastoma (DA) in the English literature was given by Eversole et al, who called it an 'ameloblastoma with pronounced desmoplasia'^{1,2}. Earlier, Takigawa et al and Uji et al had drawn attention to this unusual variant^{3,4}. DAs are located in the anterior or premolar area of the jaws with their radiographic appearance more typical of a fibro-osseous lesion than an ameloblastoma. Histologically, DA consists of a collagenised (desmoplasia) stroma, in which irregular islands of odontogenic epithelium are scattered⁵.

An unusual variant of ameloblastoma exhibiting follicular or plexiform areas together with the microscopic features of desmoplastic ameloblastoma, the so-called 'hybrid' lesion of ameloblastoma (HLA) was first described by Waldron and El-Mofty in 1987⁶. To date, 14 cases of HLA have been reported in the literature⁷⁻¹¹.

In this article, a case of coexisting types of (desmoplastic and unicystic) ameloblastoma with concomitant radiographic features affecting the mandible is reported. The presentation of the case posed the question whether to consider it as a kind of collision or a hybrid variant, or as a desmoplastic ameloblastoma with a prominent cystic component. To the best of the authors' knowledge, it is the first case of such a form to be reported.

Case report

A 50-year-old male suffered with a hard, painless, expansile swelling of the mandible for 2 years. It was initially peanut sized and gradually progressed, along with sensory changes, pus discharge and teeth mobility. Extraoral examination revealed a diffuse facial swelling in the symphysis region measuring approximately 7 cm × 4 cm. The swelling was oval and had a smooth surface. The skin over the swelling appeared normal. On palpation, the swelling was non-tender.

Two swellings were noticed intraorally (Fig 1). The first swelling extended from the regions of tooth 35 to 44. It measured approximately 3 cm × 3 cm in size, was well defined, oval in shape and had a smooth surface. On palpation, swelling was non-tender, hard in consist-

¹ Department of Oral Pathology and Microbiology, S.D.M College of Dental Sciences and Hospital, Dharwad, Karnataka, India.

Corresponding author: Dr Swetha Acharya, Department of Oral Pathology and Microbiology, S.D.M College of Dental Sciences and Hospital, Dharwad-580 009, Karnataka, India; Tel: 91-836-2468142; Fax: 91-836-2467612; E-mail: sbacharya@gmail.com

ency, non-fluctuant, non-reducible and non-pulsatile. The mucosa over the swelling was intact but stretched, and the vestibule was obliterated. Teeth 31 and 32 were missing and 33 and 41 were displaced, mobile and non-vital. The second swelling was in the right mandibular body extending from tooth 45 to 47. The lesion measured approximately 3 cm × 2 cm, oval in shape, with well-defined margins and had a smooth surface. On palpation, the swelling was non-tender. The mucosa was intact and the vestibule was obliterated.

Radiography disclosed an expansile lesion from the region of tooth 35 to 47, with a well-circumscribed mixed radiopaque appearance in the region of teeth 35 to 45 combined with a well-defined radiolucency of the region of teeth 44 to 47 (Fig 2). The two lesions were unified in the region of tooth 44. Root resorption of teeth 45 and 46 could be appreciated. The continuity of the lower border of the mandible was intact. Expansion of the buccal cortical plate was evident. Orthopantomograph and occlusal radiographs (Fig 3) of the anterior mandible showed a mixed appearance mimicking a fibro-osseous lesion. Differential diagnoses included fibrous dysplasia, ossifying fibroma and odontogenic tumours; ameloblastoma and odontogenic keratocyst for the posterior segment.

An incisional biopsy demonstrated microscopic features of DA (Fig 4) anteriorly and unicystic ameloblastoma (Fig 5) posteriorly. After 7 months, several teeth (the left first premolar to the right second molar of the mandible) were extracted, and surgical enucleation of the posterior segment and resection of the anterior segment was performed. A 2.5 mm-thick reconstruction plate was adapted over the inferior border of mandible. Care was taken to identify and preserve the right and left mental nerve and right inferior alveolar nerve. The patient's postoperative course was uneventful. The gross specimen showed a well-circumscribed solitary cystic lesion from the posterior segment and a solid lesion with ill-defined margins from the anterior segment (Fig 6). Histology of the excised lesions was similar to the incisional biopsy.

Discussion

DA accounts for 4 to 13% of all SMAs¹². At present, 150 cases of DA have been reported in Japanese, Chinese, Malaysian, Western, African and Indian populations¹¹. DA can develop at any age; however, people in their forties and fifties are more likely to be affected. No gender predilection of DA has been reported¹². Usually DAs are mixed radiolucent and radiopaque lesions with ill-defined borders¹². Takata et al attributed this to its

infiltrative nature¹⁰, which was illustrated in the anterior segment of the mandible in this particular case.

Histopathology of DA is composed of marked desmoplastic stroma and atypical epithelial morphology; both prominent in this case. The pronounced stromal reaction of DAs can be viewed as a defensive response of the host to the aggressive tumour¹². However, desmoplasia appear to compress the epithelial islands (consequently, they are small and discrete) and suppress tumour cell growth. Many epithelial islands lacked the obvious ameloblastic polarity and resembled a squamous odontogenic tumour¹³. Takata et al found that the transforming growth factor-beta (TGF-β) produced by tumour cells of DA played a role in desmoplastic matrix formation. Desmoplasia of the stromal connective tissue in DA may be due to the maturation of SMA, as similar dense collagenisation is seen during maturation of long-standing tumours¹⁰.

In this case, the posterior segment of the mandible demonstrated features of unicystic ameloblastoma, with an epithelial lining representing early ameloblastoma-like changes.

Pathological interpretation of the coexistence of DA and non-DA in the 'hybrid' lesion is a matter of speculation⁷. The significance of concomitant occurrence of unicystic and desmoplastic ameloblastoma is unknown. The potential ability of the enamel organ type tissue or odontogenic epithelium to form different types of ameloblastomas together in a single topographical site should be appreciated. Recognition of the growth pattern is important, because it is well accepted that the unicystic type has a considerably better overall prognosis and a much-reduced incidence of recurrence compared with SMA.

It is well documented that the overall growth pattern of the neoplasm is important, as it has a significant implication in treatment decisions and the incidence of recurrence¹⁴. The biologic behaviour of DA, including recurrence rate, cannot be completely appreciated due to the relatively few reported cases with sufficiently long follow-up periods. The radiologic and histologic findings of poor encapsulation or total lack of a capsule require long-term follow-up, and the findings indicate the likelihood that DA has a potential for recurrence similar to SMAs¹⁵. Resection and enucleation are the main treatment modalities of DAs. The recurrence rate of DAs after enucleation is significantly higher than after resection¹². In the present case, DA occurred in the mandible and involved the anterior alveolar region, sparing to some extent the lower border of mandible. Consequently, resection was performed (instead of segmental removal), surgically preserving the lower border

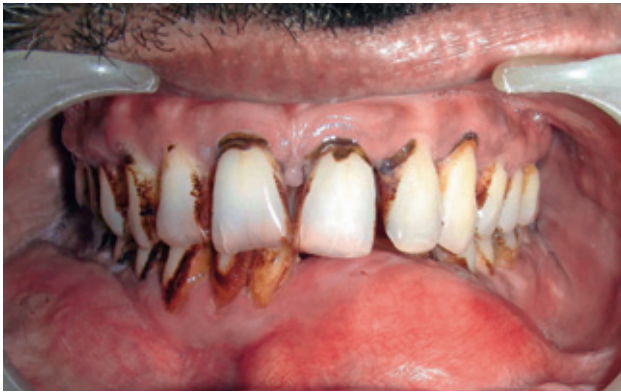

Fig 1 Intraoral view showing expansile lesion, presenting as separate swelling.

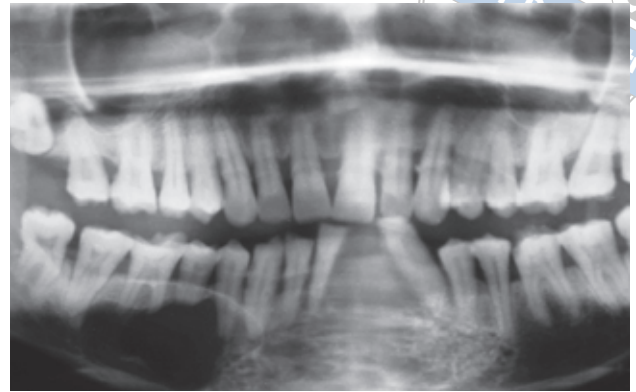


Fig 2 Panoramic radiographs showing a mixed radiolucent – radiopaque expansile lesion in the anterior segment and a well-defined radiolucent lesion in the posterior segment of mandible.

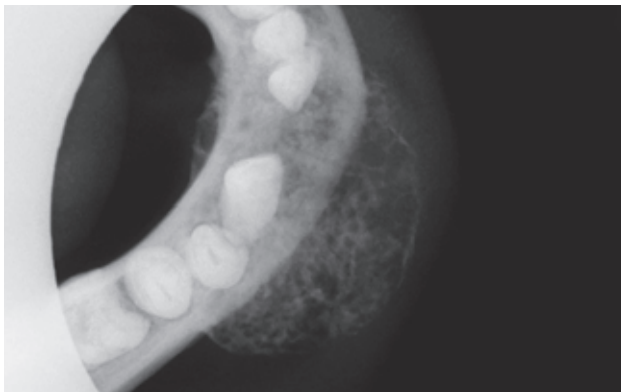


Fig 3 Occlusal radiograph of a desmoplastic ameloblastoma showing a mixed radiopaque lesion in the anterior segment of mandible.

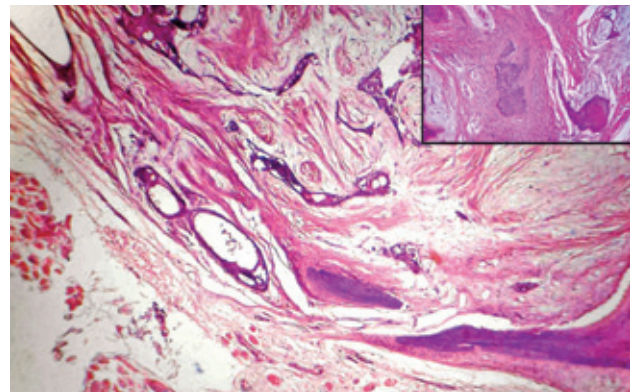


Fig 4 Coarsely collagenous stroma containing scattered islands and nests of atypical odontogenic epithelium. (H&E, Scanner) INSET showing remnants of resorbed bone/metaplastic bone in the desmoplastic stroma.

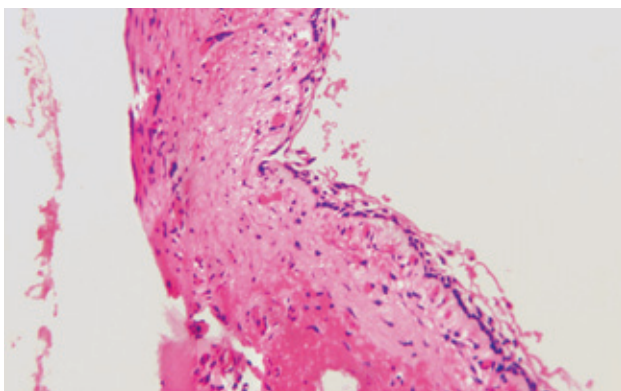
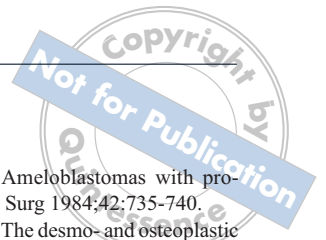


Fig 5 Cystic architecture with the typical ameloblastic changes confined to the cystic-lining epithelium. Ameloblastic epithelium with hyperchromatic palisaded basal cell layer, and thin layer of stellate reticulum-like cells (H&E, ×10).

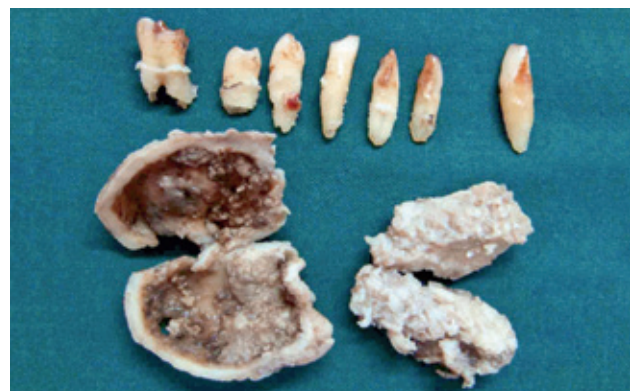

Fig 6 Gross specimens showing a solitary cystic lesion (right) and a solid lesion with an ill-defined margin (left).



of the mandible with the intent of maintaining the continuity of the mandible. Healthy bone margins could be achieved during excision and the lesion was separable from the inferior border of the mandible in the anterior segment. A reconstruction plate was adapted over the inferior border of the mandible to maintain stability.

This case may possibly be a DA with a prominent cystic component, as cyst formation is relatively common in ameloblastomas and it is usual to have a mixture of histologic patterns. However clinical, radiological, gross and histologic features of the present case were suggestive of varied growth patterns (desmoplastic and unicystic) in an ameloblastoma. Based on growth patterns the lesion was successfully treated with resection and surgical enucleation.

Acknowledgements

The authors would like to thank the faculty of the Department of Oral Pathology, Oral Medicine and Oral and Maxillofacial Surgery, S.D.M College of Dental Sciences and Hospital, Dharwad-580009, Karnataka, India.

References

1. Eversole LR, Leider AS, Hansen LS. Ameloblastomas with pronounced desmoplasia. *J Oral Maxillofac Surg* 1984;42:735-740.
2. Philipsen HP, Ormiston IW, Reichart PA. The desmo- and osteoplastic ameloblastoma. Histologic variant or clinicopathologic entity? Case reports. *Int J Oral Maxillofac Surg* 1992; 21:352-357.
3. Takigawa T, Matsumoto M, Sekine Y. A case report of ameloblastoma proliferated like epulis of maxilla. *Nihon Univ Dent J* 1981;55:920-924 [in Japanese].
4. Uji Y, Kodama K, Sakamoto A, Taen A. An ameloblastoma with interesting findings. *Jpn J Oral Maxillofac Surg* 1983;29:1512-1519 [in Japanese].
5. Shashikanth MC, Neetha MC, Ali IM, Shambulingappa P. Desmoplastic ameloblastoma in the maxilla: A case report and review of literature. *Indian J Dent Res* 2007;18:214-217.
6. Waldron CA, El-Mofty SK. A histopathologic study of 116 ameloblastomas with special reference to desmoplastic variant. *Oral Surg Oral Med Oral Pathol* 1987;63:441-451.
7. Takata T, Miyauchi M, Ogawa I et al. So-called 'hybrid' lesion of desmoplastic and conventional ameloblastoma: report of a case and review of the literature. *Pathol Int* 1999;49:1014-1018.
8. Wakoh M, Harada T, Inoue T. Follicular/desmoplastic hybrid ameloblastoma with radiographic features of concomitant fibro-osseous and solitary cystic lesion. *Oral Surg Oral Med Oral Pathol Oral Radiol Endod.* 2002;94:774-780.
9. Dos Santos JN, De Souza VF, Azevêdo RA, Sarmiento VA, Souza LB. "Hybrid" lesion of desmoplastic and conventional ameloblastoma: immunohistochemical aspects. *Braz J Otorhinolaryngol* 2006;72:709-713.
10. Sivapathasundaram B, Einstein A, Syed RI. Desmoplastic ameloblastoma in Indians: Report of five cases and review of literature. *Indian J Dent Res* 2007;18:218-221.
11. Yazdi I, Seyedmajidi M, Foroughi R. Desmoplastic ameloblastoma (a hybrid variant): report of a case and review of the literature. *Arch Iran Med* 2009;12:304-308.
12. Sun ZJ, Wu YR, Cheng N, Zwahlen RA, Zhao YF. Desmoplastic ameloblastoma-A review. *Oral Oncol* 2009;45:752-759.
13. Higuchi Y, Nakamura N, Ohishi M, Tashiro H. Unusual ameloblastoma with extensive stromal desmoplasia. *J Craniomaxillofac Surg* 1991;19:323-327.
14. Kessler HP. Intraosseous ameloblastoma. *Oral Maxillofac Surg Clin North Am* 2004;16:309-322.
15. Reichart PA, Philipsen HP. *Odontogenic tumors and allied lesions.* London; Quintessence Publishing, 2004:69-74.