



Clinical Evaluation of a Gingiva-coloured Material, Comp Natur: A 3-Year Longitudinal Study

Dilek TAĞTEKİN¹, Funda YANIKOĞLU¹, Gürol ÖZYÖNEY¹, Nuran NOYAN¹, Osman HAYRAN²

Objective: To report on a three-year clinical evaluation of the gingiva-coloured compomer (Comp Natur, Voco, Germany).

Methods: Twelve patients with cervical lesions as a result of either gingival recession or worn root dentine were included in this study. In total, 106 restorations were evaluated by two examiners at baseline, 6-month and 3-year recalls.

Results: Ninety-nine restorations (99/106, 93.4%) were reported with having a good retention in the oral cavity at the 3-year recall. Ninety-two of the 99 restorations were evaluated as excellent for colour match. Marginal discoloration was slightly higher at the 3-year recall, while surface texture and anatomic form were significant. Marginal adaptation was not statistically important at the 3-year recall. There was no problem related to caries and postoperative sensitivity.

Conclusion: Comp Natur is an acceptable treatment choice for cervical defects with recessed gingiva.

Key words: cervical defect, class 5, Comp Natur, compomer, gingival recession

The results of defective gingiva are exposed root surfaces, difficulty of plaque control, gingivitis, periodontitis, sensitivity at the cervical areas, and the addition of extrinsic, intrinsic, and mechanical factors with V-shaped defects and root caries. The clinical appearance of these cases – with a longer clinical crown on a different level from neighbouring gingival lines in the anterior region¹⁻³ – is not aesthetic at all.

Restorative treatment of a cervical defect may prevent further plaque accumulation, toothbrush trauma, and caries. Possible restorative treatments for those abrasions are composite fillings or prosthodontics. Composite resins or compomers are preferred for being less expensive, are conservative, and require only one appointment^{1,3,4}.

Although crowns may achieve superior aesthetic correction when full coverage is needed, recent developments in adhesive technology make the direct restorations stronger and more aesthetic. However, application of a tooth-coloured composite on a recessive gingival area, on both coronal and root surfaces, may result with an unacceptable appearance. Coronal length will appear longer than the biological crown, and the level of gingival lines will differ from the adjacent teeth, leading to an unaesthetic look. Those extensive lesions, including both tissue surfaces at cervical areas, should be restored clinically to recreate the natural strength and colour, and to be long lasting.

There are few reported studies on the clinical longevity of gingiva-coloured compomer materials. Günay and Lührs⁵ explored the application of a compomer named Comp Natur clinically in detail and demonstrated some cases with 5- or 6-month recalls and other cases, with 2- and 6-year recalls. They also published another case report with a 1-year recall⁶.

This paper aims to evaluate the clinical effectiveness of Comp Natur as a combination sandwich restoration with a composite resin, Grandio, on root surface with

1 Department of Operative Dentistry, Faculty of Dentistry, Marmara University, Nişantaşı, Istanbul, Turkey

2 University of Yeditepe, Faculty of Medicine, Istanbul, Turkey

Corresponding author: Dr Dilek Tağtekin, Department of Operative, Faculty of Dentistry, Marmara University, Büyükciftlik Sk. No.6 34365, Nişantaşı, Istanbul, Turkey. Tel: 90-212-2319120/522; Fax: 90-212-2465247; E-mail: dtagtekin@marmara.edu.tr

extensive cervical defects in a three-year clinical longitudinal observation.

Materials and methods

Comp Natur (VOCO, Germany) is a gingiva-shade compomer restorative system and contains BIS-GMA, diurethane dimethacrylate, TEGDMA and BHT an opaquer with dimethacrylate as well as BHT, a combination of a glass ionomers, and higher amount of inorganic fillers of light-cured composite materials. Since this is a promising material, the study aimed to evaluate its clinical effectiveness in a longitudinal observation with 106 restorations in 12 patients. The inclusion criteria for the patients included recessed gingiva with exposed and approximately one-third abraded root dentine. Two patients showed a habit of aggressive brushing in a horizontal direction with a highly abrasive polishing powder. They were complaining of an unaesthetic appearance and disturbing feelings of hypersensitivity. Three patients demonstrated old restorations for retreatment of unaesthetic teeth. Three different patients had exposed, discoloured, and worn root surfaces with hypersensitivity following periodontal surgery.

Restorative procedures

Preparation: Teeth were cleaned with pumice and a polishing brush. Gingiva was healthy and adapted well on the roots' surfaces, which was good for proper marginal adaptation and aesthetics.

Cavity preparation: Carious and infected dentine were removed with a small stainless steel round bur. Non-carious and sclerotic dentinal surfaces were prepared with minimal invasion by a diamond #3 round bur (1.2 mm diameter) (Midwest Dental Products and Brasseler, USA) to remove a superficial sclerotic layer for retention purposes. A diamond #7406 (1.8 mm diameter) lobut-type bur (Midwest Dental Products and Brasseler, USA) was used for the modelling of the occluso-cervical margins for bevelling to increase the adhesion area. Caries-free cervical defects were cleaned with a fluoride-free paste or pumice with a rubber cup or rotating brush.

Cleaning: All residues from the cavity were removed using a water jet. Excess water was removed gently with an air jet and dentine protected from over drying. Retraction cords (Ultrapak, Ultradent, Utah, USA) were used to provide a clear area for the restoration and were applied on each cavity subgingivally.

Shade design: Dark or strong yellow cervical areas affect the shade of the filling. These cervical areas should be covered with the included opaquer system before appli-

cation of the compomer material. The opaquer system consists of the following light-cured materials: light gingiva, dark gingiva, white as opaque, and filling material.

Application of Futurabond NR (VOCO, Germany): Shallow cavities need only one application of the dentine adhesive. In the presence of any enamel, a 1 to 1.5 mm bevel was prepared. In this way the preparation area was extended and a transient pass to the incisal was obtained. In cavities with a depth of more than 0.5 mm into the dentine, a liner with a glass ionomer cement had to be applied on the dentinal surface closest to the pulp. The rest of the dentine was left intact for adhesion.

The enamel surface was etched with a 35% orthophosphoric acid gel (Vocacid, VOCO, Germany) for 30 seconds, washed, and then dried. The mixed Futurabond NR was applied to dentine and enamel, then massaged into the tooth substance for 30 seconds, then light-cured for 20 seconds.

Application of the opaquer: The opaquer was applied on the enamel surface as a thin layer, then light-cured for 40 seconds. If there was insufficient coverage, a second layer of opaquer was applied and cured for another 40 seconds.

Application of Comp Natur: The compomer should be applied in layers of a maximum of 2 mm thick and light-cured. Each layer was light-cured for 40 seconds with a halogen light (Bluephase C5, Ivoclar Vivadent, Liechtenstein) using transparent cervical matrices (Hawe Transparent Cervical Matrices, KerrHawe, Biggio, Switzerland) and light-wedges (Adapt Luciwedge, KerrHawe, Biggio, Switzerland).

The final colour is obtained by a combination of opaquer and the chosen gingival colour, but it is the opaquer which is the important agent for achieving the colour of the restoration. Therefore, the lighter opaquer was selected according to the colour of the gingiva.

Patient 1

A 47-year-old female patient showed worn root surfaces on the maxillary right central, lateral, canine, and left central and lateral teeth, with periodontal problems (Fig 1). Her main complaints were unaesthetic appearance and hypersensitivity. Following the periodontal surgery, long clinical crowns and worn root surfaces were exposed. The clinical examination revealed a hypersensitivity to probe, airspray, and water.

Retraction floss was applied subgingivally. All defects were treated with the compomer at corresponding gingival areas of each root and the rest of the cavities were filled with a nano-hybrid tooth-coloured

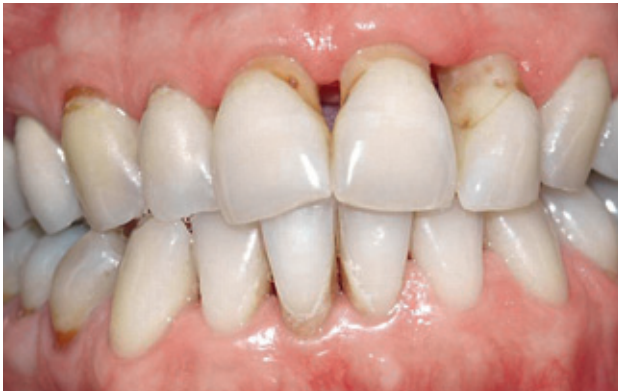

Fig 1 Buccal view of worn root on maxillary right central, lateral, canine and left central, lateral (patient 1).

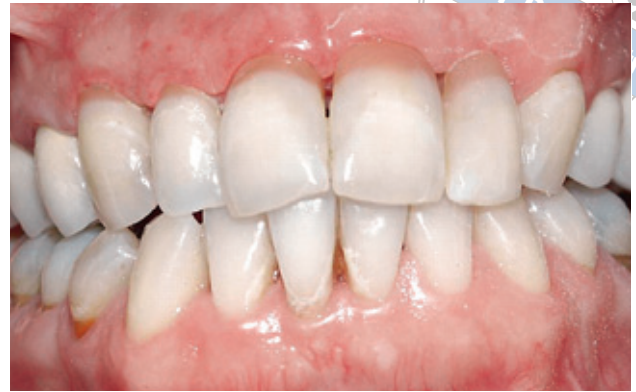

Fig 2 Buccal view of the restorations at baseline (patient 1).

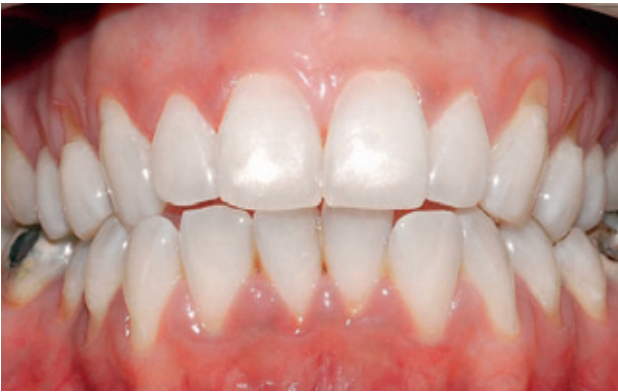

Fig 3 Buccal view of worn root on maxillary right first, second premolars and left canine, first and second premolars (patient 2).

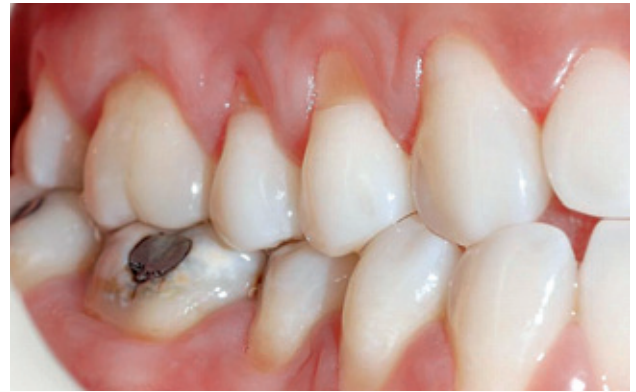

Fig 4 Right side view of gingival recession and worn root (patient 2).


composite (Grandio, Voco, Germany). Figure 2 shows the buccal view of the restorations of Patient 1 at baseline. Periodontally operated interdental papillas were missing on the baselines.

Patient 2

A 25-year-old female patient with gingival recession and worn roots on the maxillary right first and second premolars, left canine, and first and second premolars (Figures 3 and 4) came to the clinic's department of Operative Dentistry at Marmara University. Maxillary

right and left first premolars and right second premolar were treated with the compomer at corresponding gingival areas, and the rest of the cavities were filled with the composite.

The restorations were rated independently by two experienced dentists who were not involved with the insertion. The baseline ratings were done one week following the insertion. The restorations were evaluated by USPHS criteria^{7,8} at 6-month, 1-year, 2-year and 3-year recalls following insertion (Table 1). Photographic records of each case were obtained at intervals allowing further comparison. Any disagreement was resolved

**Table 1** The USPHS criteria by Anusavice⁷, and Randall and Wilson⁸ used in the study

Retention	Criteria
Alfa	Restoration is present.
Charlie	Restoration is partially or totally missing.
Colour match	
Alfa	The restoration matches the adjacent tooth structure in colour, shade or translucency.
Bravo	There is a light mismatch in colour, shade or translucency but within the normal range of adjacent tooth structure.
Charlie	There is a light mismatch in colour, shade or translucency but outside of the normal range of adjacent tooth structure.
Marginal discolouration	
Alfa	There is no discolouration anywhere along the margin between the restoration and the adjacent tooth structure.
Bravo	Discolouration is present but has not penetrated along the margin in a pulpal direction.
Charlie	Discolouration has penetrated along the margin in a pulpal direction.
Anatomic form	
Alfa	The restoration is continuous with the existing anatomic form.
Bravo	The restoration is discontinuous with existing anatomic form, but missing material is not sufficient to expose the dentine or base.
Charlie	Sufficient restorative material is missing to expose the dentine or base.
Marginal adaptation	
Alfa	There is no visible evidence of the crevice along the margin into which the explorer will penetrate.
Bravo	There is visible evidence of the crevice along the margin, into which the explorer will penetrate or catch.
Charlie	The explorer will penetrate the crevice and dentine or base is exposed.
Delta	The restoration is mobile, fractured or missing either in part or total.
Surface texture	
Alfa	The restoration surface is as smooth as surrounding enamel.
Bravo	The restoration surface is rougher than the surrounding enamel.
Charlie	There is a crevice and fracture on the surface of the restoration.
Secondary caries	
Alfa	No caries is present at margin of the restoration, as evidenced by softness, opacity or etching at the margin.
Charlie	There is evidence of caries at margin of the restoration.
Postoperative sensitivity	
Alfa	There is no postoperative sensitivity.
Delta	Postoperative sensitivity is experienced. No need to change.
Charlie	Need to change immediately.

**Table 2** Distribution frequency of the scores for the evaluated USPHS criteria of restorations

	Cervical restorations (n = 106)												Wilcoxon signed-rank test P				
	Baseline			12-month follow-up			24-month follow-up			36-month follow-up			Baseline -12 months	Baseline -24 months	12-24 months	Baseline -36 months	24-36 months
	Alpha	Bravo	Charlie	Alpha	Bravo	Charlie	Alpha	Bravo	Charlie	Alpha	Bravo	Charlie					
Retention	106	-	-	103	-	3	99	-	7	99	-	7	Z = -1.732 P = 0.083	Z = -2.646 P = 0.008*	Z = -2.000 P = 0.046*	Z = -2.646 P = 0.008*	Z = 0.000 P = 1.000
Colour match	106	-	-	103	3	-	97	9	-	92	14	-	Z = -1.732 P = 0.083	Z = -2.810 P = 0.005*	Z = -2.271 P = 0.023*	Z = -3.391 P = 0.001*	Z = -2.236 P = 0.025*
Marginal discoloration	106	-	-	98	8	-	92	14	-	86	20	-	Z = -2.598 P = 0.009*	Z = -3.391 P = 0.001*	Z = -2.640 P = 0.008*	Z = -4.038 P = 0.000*	Z = -3.000 P = 0.003*
Marginal adaptation	106	-	-	103	3	-	97	9	-	94	12	-	Z = -1.732 P = 0.083	Z = -2.810 P = 0.005*	Z = -2.271 P = 0.023*	Z = -3.153 P = 0.002*	Z = -1.732 P = 0.083
Surface texture	106	*	-	103	3	-	99	7	-	99	7	-	Z = -1.732 P = 0.083	Z = -2.646 P = 0.008*	Z = -2.000 P = 0.046*	Z = -2.646 P = 0.008*	Z = 0.000 P = 1.000
Caries	106	-	-	106	-	-	106	-	-	106	-	-	Z = 0.000 P = 1.000	Z = 0.000 P = 1.000	Z = 0.000 P = 1.000	Z = 0.000 P = 1.000	Z = 0.000 P = 1.000
Anatomic form	106	-	-	103	3	-	98	8	-	97	9	-	Z = -1.732 P = 0.083	Z = -2.714 P = 0.007*	Z = -2.121 P = 0.034*	Z = -2.810 P = 0.005*	Z = -1.000 P = 0.317
Postoperative sensitivity	103	-	-	103	-	-	99	-	-	99	-	-	Z = 0.000 P = 1.000	Z = 0.000 P = 1.000	Z = 0.000 P = 1.000	Z = 0.000 P = 1.000	Z = 0.000 P = 1.000

*Statistically significant ($P < 0.05$)

by consensus. The criterion for postoperative sensitivity was determined by direct questioning. Periodontal variables such as plaque and gingival index were also recorded^{9,10}.

The patients answered questionnaires on their satisfaction of the colour match, surface texture, chewing ability, sensitivity, and pain during chewing. All patients were able to participate in each recall.

The variables evaluated according to USPHS criteria at baseline and at the 6-month, 1-, 2- and 3-year recalls are as follows: colour stability, marginal discoloration, marginal adaptation, caries, anatomic form, surface texture, sensitivity, and retention.

SPSS software (Version 11. SPSS, Chicago, Illinois) was used to perform the statistical analyses. The baseline scores and recalls were assessed by Wilcoxon signed rank test. Significance level was at $P = 0.05$.

Results

Table 2 shows the evaluation scores of the gingiva-coloured compomer restorations at the 3-year recall. Ninety-nine of 106 restorations were still retained in the oral cavity at the 3-year recall (93.4%). Three restorations in the same patient were lost at 8 months and scored as 'Charlie' at the end of the study. Four aesthetic sand-

wich (compomer and composite) restorations in another patient were lost at 20 months and scored as 'Charlie' at the end of the study. Restorations were retreated for both patients and still showed good retention at the 3-year recall. Retention rate was slightly low at the 2- and 3-year recalls ($P = 0.046$). Marginal discoloration was a little higher at the 3-year recall ($P = 0.000$). Surface texture was meaningful at the 3-year recall ($P = 0.008$). Anatomic form was slightly lost at the 3-year recall ($P = 0.005$).

Ninety-two restorations were classified as excellent for colour match at the 3-year recall. Colour match seemed to be a little difficult, but was not a significant problem for the compomer used. Again, 'Bravo' degrees of colour differences were obtained at the 2- and 3-year recalls ($n = 9$; $n = 14$) ($P = 0.005$; $P = 0.001$). Corresponding to the results of marginal discoloration, there were eight 'Bravos' at 1-year, 14 at 2-year, and 20 at 3-year evaluations. Although the results were statistically significant ($P = 0.009$; $P = 0.001$; $P = 0.000$; $P = 0.003$), clinical evaluation was not exaggerated.

None of the patients complained of an aesthetic disorder, sensitivity, or caries. Figure 5 demonstrates the restorations of Patient 1 at the 2-year recall. Regeneration of dental papillas clearly observed of the patient at the 3-year recall (Fig 6). Figure 7 shows the restorations of Patient 2 at the 2-year recall. Figures 8 and 9 demonstrate the restorations of the patient at the 3-year recall.

Discussion

One of the studies done by Demirci et al¹¹ evaluated a polyacid modified resin composite in Class 5 carious lesions at a 3-year recall and found a 92.4% retention rate. Van Dijken¹² stated that it was important to do some clinical evaluations on new dental materials before any marketing. This way a nearly equal evaluation will be processed for the evaluated restorations. The present study not only evaluated the compomer material Comp Natur, at *in vivo* clinical conditions using USPHS criteria, but also the composite on the coronal sides of Class 5 cavities, with a retention rate of 93.4%.

Seven restorations were lost in two patients at the 8- and 20-month durations. The compomer might not be successful on those prepared cavities or the technique used may not be properly carried out. Those patients having the compomer might have bruxism or clenching habits, which had not been mentioned at the initial examination. Therefore it would be better to have less restorations with more patient population.

Günay and Lührs⁵ suggested Comp Natur be used for patients with dental fear, who are older in age, under

general or local risk factors for surgical contraindications, or who have Class 3 and Class 4 recessions with a questionable prognosis of the outcome of surgery. According to Miller¹³ Class 3 extensive recessions will reach mobile mucosa passing through mucogingival line.

Recessions and missing teeth may affect the papilla in advance level. In Class 4, hard and soft tissue loss surrounding teeth mostly observed repeated gingivoperiodontitis ulcerosa, and after gingival recession, periodontitis and resective periodontal surgery. Patients reported successful results at 5 months, 2 years and 6 years for other patients. A chamber-style cavity designed for the retention was prepared. In the study extra design or retention aid was not used on the cavities. The aim was to evaluate the compomer itself for retention and duration of the restoration under clinical conditions. Unfortunately, there were three missing restorations in the same patient, which may be due to non-retentive cavities. Although the same cavity preparation was used for all cases, the authors' suggestion on this matter is that cavity preparation should be selectively modified depending on the patient and the cavity. Compomers shrink 2.6% during the polymerisation process by light curing. A layering technique should be used during placement of the compomers in order to reduce the amount of shrinkage.

Vitremer (3M ESPE) showed 98% retention at 24 months in Özgünaltay and Önen's clinical study¹⁴. On the other hand, failure of the restoration as an 'aesthetic sandwich method' in the present study was three 'Charlies' at the 1-year recall, seven at the 2-year recall, and seven at the 3-year recall. It was interesting that when the failure occurred, both composite and compomer restorations were missing together. This may be the result of good adhesion between composite and compomer materials, or because the missing of either one caused the loss of support against occlusal forces. Retention loss was statistically important between baseline, 1-year, 2-year and 3-year recalls. In clinical use, it was observed there was a need for some experience in opaquer usage to achieve a good colour match. Marginal discoloration of Comp Natur were 20 'Bravos' at the 3-year recall in our study, while Vitremer showed increased discoloration compared to resin composite in Özgünaltay and Önen's study¹⁴. However, the authors suggested that there was a need for longer clinical results to indicate the suitability of the materials.

Marginal adaptation of the materials resulted in 12 'Bravos' at the 3-year recall, which was not a bad result among 106 restorations. It was interesting that surface texture is constant at the 2- and 3-year recalls. No caries

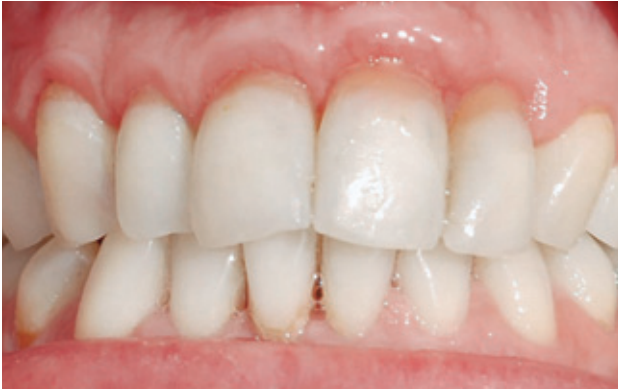

Fig 5 Buccal view of the restorations at 2-year recall (patient 1).

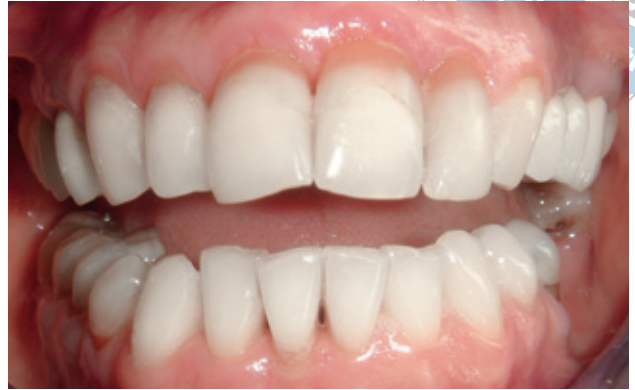

Fig 6 Extraoral general view of restorations with marginal discoloration at 3-year recall (patient 1).

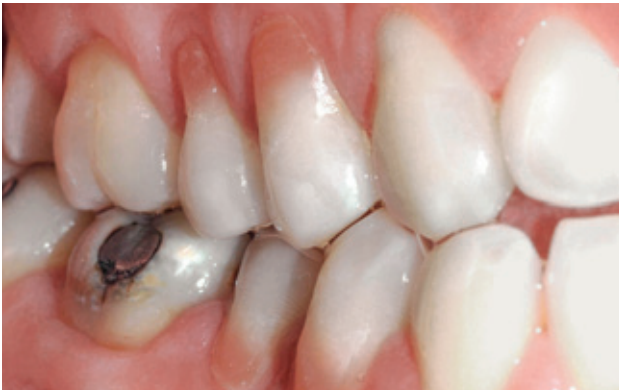

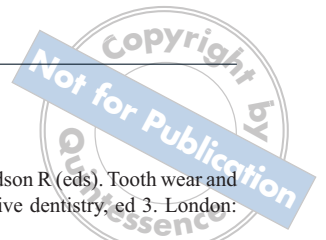
Fig 7 Right side view of the restorations at 2-year recall (patient 2).

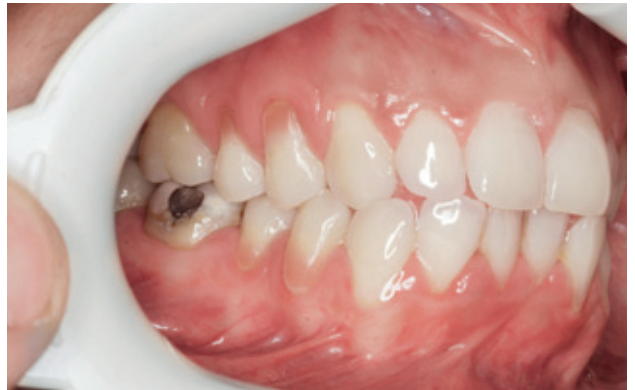

Fig 8 Right side view of the restorations at 3-year recall (patient 2).

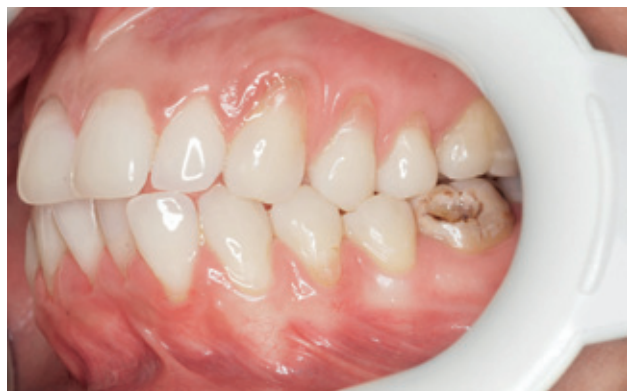

Fig 9 Left side view of the restorations at 3-year recall (patient 2).



was observed at the restorations. This is a very promising result since those patients with large restorations were prone to caries. As surface texture did not change, this may be very positive benefit for prevention from plaque process. Since dentinal sensitivity was the main complaint from the patients at the beginning of this clinical study, it could be concluded that this material seems to have a desensitising effect. This may be due to a very good seal of the cavities by the compomer.

This clinical study used the combination of an aesthetic Class 5 sandwich restoration method. The coronal surface of these cervical cavities had to have a tooth colour and the cervical region needed the gingival appearance, so the composite and compomer were combined in a Class 5 cavity preparation. It was so-called 'the aesthetic sandwich method'.

Conclusion

Under the conditions of this 3-year clinical trial, it seems Comp Natur as a compomer material is an acceptable treatment choice for cervical defects that extend onto root dentine with recessed gingiva. The combination of a gingiva-coloured compomer and a composite at the border of the cemento-enamel junction of a tooth, served as an appropriate aesthetic restoration.

Acknowledgements

This study was supported by the Marmara University Scientific Research Committee (Project no: SAG-D-250608-0169). The authors would like to thank VOCO Company for providing Comp Natur restorative material for clinical use.

Conflict of interest

The authors have no financial relationship with the organisation that sponsored the research.

References

1. Addy M, Embery G, Edgar WM, Orchardson R (eds). *Tooth wear and sensitivity: clinical advances in restorative dentistry*, ed 3. London: Martin Dunitz Ltd, 2000.
2. Sturdevant CM, Roberson TM, Heyman HO, Sturdevant JR. *The art and science of operative dentistry*, ed 3. St. Louis: Mosby, 1995.
3. Newman MG, Takei HH, Carranza FA. *Clinical periodontology*, ed 9. St. Louis: Saunders, 2002.
4. Zalkind M, Hochman N. Alternative method of conservative aesthetic treatment for gingival recession. *J Prosthet Dent* 1997;77:561–563.
5. Günay H, Lührs AK. Parodontale rezessionen mit klasse V-defekten – konservative therapie mit zahnfleischfarbenen kompomeren. *Zahnarzt Mitt* 2007;97:2910–2919.
6. Günay H, Lührs AK. Konservative therapie parodontaler rezessionen mit zahnsubstanzdefekten mittels zahnfleischfarbener kompomere-klinisches vorgehen. *Dtsch Zahnarztl Z* 2006;61:586–593.
7. Anusavice KJ. *Quality evaluation of dental restorations. Criteria of placement and replacement*. Chicago: Quintessence, 1989.
8. Randall RC, Wilson NH. Clinical testing of restorative materials: some historical landmarks. *J Dent* 1999;27:543–550.
9. Loe H, Silness J. Periodontal disease in pregnancy. I. Prevalence and severity. *Acta Odontol Scand* 1963;21:533–551.
10. Silness J, Loe H. Periodontal disease in pregnancy. II. Correlation between oral hygiene and periodontal condition. *Acta Odontol Scand* 1964;22:121–135.
11. Demirci M, Ersev H, Topçubaşı M, Uçok M. Clinical evaluation of a polyacid-modified resin composite in class V carious lesions: three-year results. *Dent Mater J* 2005;24:321–327.
12. van Dijken JW. Clinical evaluation of three adhesive systems in class V non-carious lesions. *Dent Mater* 2000;16:285–291.
13. Miller PD Jr. A classification of marginal tissue recession. *Int J Periodontics Restorative Dent* 1985;5:8–13.
14. Özgünlaltay G, Onen A. Three-year clinical evaluation of a resin modified glass-ionomer cement and a composite resin in non-carious class V lesions. *J Oral Rehabil* 2002;29:1037–1041.