

Eagle's Syndrome Treated with Dissection of the Styloid Process via an Extraoral Approach Combined with Antidepressants

Guo Guang PENG¹, Wei Liang CHEN², Jun Wei WU¹, Ji Yang PAN³

Objective: To evaluate the outcome of dissecting the styloid process via an extraoral approach combined with antidepressants for treating Eagle's syndrome.

Methods: Twenty-two patients with Eagle's syndrome underwent resection of the elongated styloid processes under general anaesthesia via an extraoral approach. All patients completed a self-rating depression scale preoperatively, and a score over 49 was defined as depression. The patients with depression were treated with fluoxetine 20 mg/day for 3 weeks postoperatively. In all patients, the abnormal length of the styloid process was resected.

Results: No surgical complications were observed. Eighteen (81.8%) patients had depression, and all 22 patients were followed for 7 to 26 months: 19 were symptom-free (86.4%), two patients with mild or moderate depression obtained almost complete remission of their symptoms, and one patient with severe depression obtained partial remission. No complications of medication occurred in any patient with depression, and all patients had a satisfactory cosmetic result and no paraesthesia.

Conclusion: Dissection of the styloid process via an extraoral approach is simple and reliable; dissection of the styloid process combined with antidepressants (fluoxetine) is preferred for treating Eagle's syndrome.

Key words: antidepressants, depression, Eagle's syndrome, fluoxetine, Styloid-stylohyoid syndrome

Eagle's syndrome constitutes a group of symptoms that includes recurrent throat pain, globus pharyngeus, dysphagia, referred otalgia, and neck pain possibly caused by elongation of the styloid process or ossification of the stylohyoid or stylomandibular ligaments. The etiology and pathogenesis of this syndrome are controversial. A previous surgical trauma, such as ton-

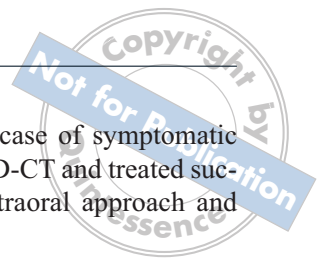sillectomy or chronic irritation of the stylomandibular ligament, could cause osteitis, tendonitis, or periostitis, which could lead to reactive ossifying hyperplasia of the styloid process¹. Hypotheses involving osseous metaplasia of the Reichert cartilage residues, persistence of mesenchymal elements capable of producing bone tissue in adults, and ossification of the stylohyoid ligament related to endocrine disorders have also been proposed². However, the abnormal length of the styloid process by itself is not sufficient to explain the pathogenesis of Eagle's syndrome. This investigation proposed that not only a long stylohyoid process, but also depression, are necessary to give rise to Eagle's syndrome. It had been previously reported that seven out of eight patients with styloid syndrome had a depressive disorder³. In this study, the outcome of dissecting the styloid process via an extraoral approach, combined with antidepressants for treating Eagle's syndrome, was evaluated.

1 Department of Oral and Maxillofacial Surgery, Foshan Hospital of Traditional Chinese Medicine, Foshan City, Guangdong province, P.R.China.

2 Department of Oral and Maxillofacial Surgery, The Second Affiliated Hospital of Sun Yat-sen University, Guangzhou, P.R.China.

3 Department of Psychiatry, the First Affiliated Hospital of Jinan University, Guangzhou, P.R.China.

Corresponding author: Dr Wei Liang CHEN, Department of Oral and Maxillofacial Surgery, The Second Affiliated Hospital of Sun Yat-sen University, 107 Yan-jiang Road, 510120 Guangzhou, P.R.China. Tel: 86-20-81332429; Fax: 86-20-81332853; E-mail: drchen@vip.163.com



Materials and methods

Twenty-two patients (3 men, 19 women; mean age 48.5 years, range 32–64 years) with Eagle's syndrome were treated with dissection of the styloid process via an extraoral approach combined with antidepressants (fluoxetine hydrochloride, Prozac[®]; Fourth Pharmaceutical Company, Changzhou, China) between September 2003 and May 2008 at the Department of Oral and Maxillofacial Surgery, Foshan Hospital of Traditional Chinese Medicine, Foshan, Guangdong Province, and the Department of Oral and Maxillofacial Surgery, the Second Affiliated Hospital of Sun Yat-sen University, Guangzhou, China. The diagnostic criteria included a styloid process of more than 25 mm long or calcification of the stylomandibular ligament on computed tomography with three-dimensional reconstruction (3D-CT) and pharyngeal and cervical pain on swallowing, speaking, opening the mouth, or during movement of the cervical region, sensation of a foreign body in the oropharynx, or pain radiating to the ear. All of the patients underwent total resection of the abnormal length of the styloid process under general anaesthesia via an extraoral approach. Each patient completed a self-rating depression scale preoperatively. The scales were distributed and assessed by the same physician. Scores over 49, 59, and 69 were defined as mild, moderate, and severe depression, respectively. The patients with depression were treated with fluoxetine 20 mg/day for 3 weeks postoperatively.

Case report

A 46-year-old man complained of dyspnea, syncope, extreme numbness, and blurring of vision when eating and swallowing. He had no history of coronary vascular, respiratory, or optical disease. He also had no history of neurological disease, psychosis, endocrinosis, or drug dependence. On clinical examination, he had referred pain on left palpation of the oropharynx. 3D-CT showed an elongated left styloid process (Fig 1) that extended to the middle neck and might have compressed the carotid artery and vagus nerve (Fig 2). He was defined as having severe depression, as his scores on the self-rating depression scale were over 69. The elongated styloid process was resected under general anaesthesia via an extraoral approach through a 3.5 cm incision (Fig 3). An osteotome was used to resect the abnormally long styloid process, which measured 8.5 cm (Fig 4). No surgical complications occurred. Postoperatively, the patient was treated with fluoxetine tablets 20 mg/day for 3 weeks, without complications. He had a satisfactory cosmetic result with no paresthesias and has been symptom-free

for 24 months. This is a typical case of symptomatic Eagle's syndrome diagnosed by 3D-CT and treated successfully with surgery via an extraoral approach and antidepressants.

Results

The entire abnormal length of the styloid process was resected in all patients. No surgical complications were observed. In this series, 18 (81.8%) patients had depression, including mild, moderate, and severe depression in 8 (36.4%), 6 (27.3%), and 4 (18.2%), respectively. All 22 patients were followed for 7 to 26 months (average 16.8 months): 19 were completely free of symptoms (86.4%), two patients with mild or moderate depression obtained essentially complete remission of their symptoms (9.1%), and one patient with severe depression obtained partial remission (4.5%). No complications of intervention occurred in any patient with depression. All patients had a satisfactory cosmetic result and no paresthesias.

Discussion

The diagnosis of Eagle's syndrome is not difficult. The medical history and physical and radiological examinations are the main guides to a precise diagnosis. The radiologic diagnostic modality of choice is 3D-CT⁴, which better defines the length, angulation, and anatomical relationships of the stylohyoid process and is important for the differential diagnosis. Eagle's syndrome can be treated medically or surgically. Medical treatment consists of the infiltration of corticosteroid or local anaesthetics in the area of the styloid process, or giving carbamazepine^{2,5–7}. The outcome of the nonsurgical treatment of Eagle's syndrome is clearly temporary^{8,9} because the cause underlying the syndrome is not removed.

Styloidectomy is the reported treatment of choice for Eagle's syndrome. It can be performed transorally or via an extraoral approach. The disadvantage of the transoral approach is the poor visibility, which leads to potential risks of major iatrogenic injury to the main neurovascular structures. The advantages of the extraoral approach are demonstrated in this small retrospective study by the absence of perioperative complications and the minimal blood loss, surgical morbidity, and hospital stay¹⁰. The extraoral approach is advocated¹⁰. In this investigation, all patients underwent total resection of the abnormal length of the styloid process through an extraoral approach via 2.5 cm incisions, which result in very small neck scars. All patients had a satisfactory cosmetic result and no paraesthesias.

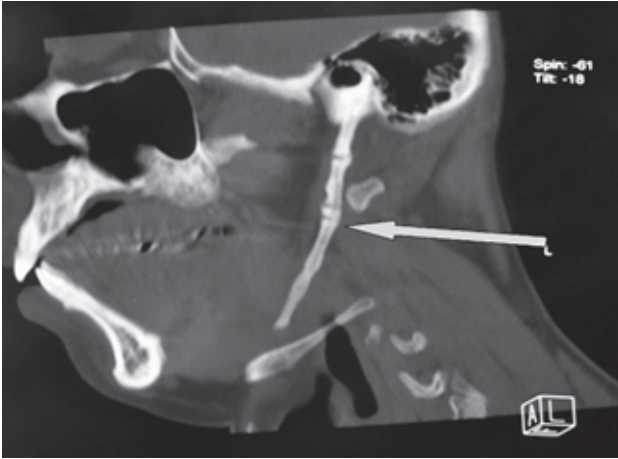
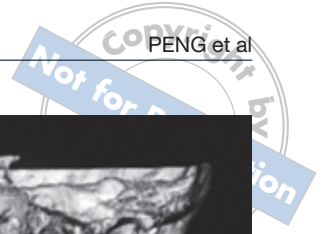


Fig 1 3D-CT showed an elongated left styloid process measuring 8.5 cm.

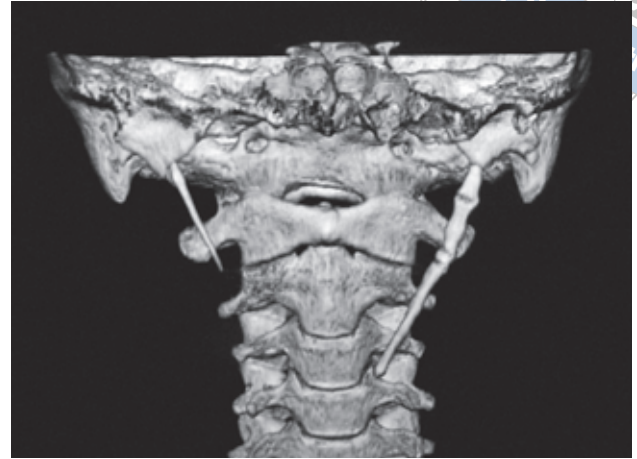


Fig 2 3D-CT showed the elongated left styloid processes extending to the middle neck, which might have compressed the carotid artery and vagus nerve.

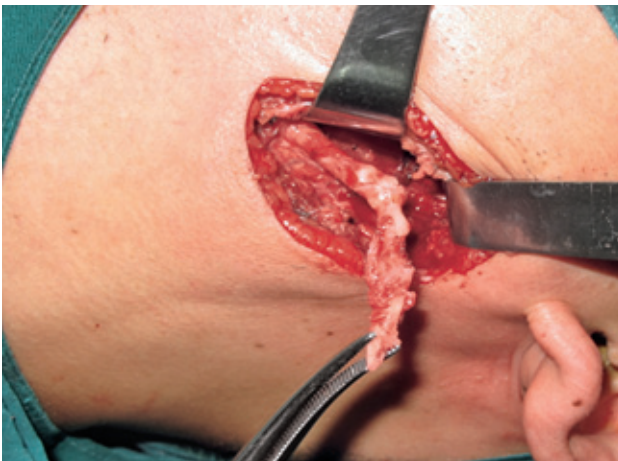


Fig 3 The elongated styloid process was resected under general anaesthesia via an extraoral approach.

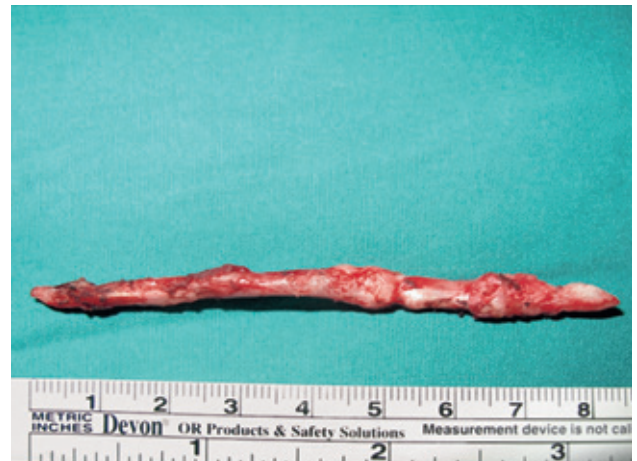

Fig 4 The abnormally long styloid process measured 8.5 cm.

Diamond et al⁸ used a slightly modified extraoral approach to remove the symptomatic elongated styloid process. Three out of five procedures resulted in more than an 80% reduction in pain and improvement in function. Fini et al¹¹ treated 11 patients with Eagle's syndrome using a transoral styloidectomy, preceded in four cases by tonsillectomy. Ten patients were followed-up: complete remission of symptoms was achieved in five cases, while the other five patients obtained partial remission; the organisation of scar tissue and greater fibrotic organisation that occurred following styloidectomy was believed to have resulted in partial remission¹¹.

The investigation concluded that not only a long stylohyoid process, but also other factors, are necessary

to give rise to Eagle's syndrome. In this investigation, 81.8% of the patients had depression, including mild, moderate, and severe depression in 36.4%, 27.3%, and 18.2%, respectively. The investigation proposed that the aetiology of this syndrome could be related to the depression. Consequently, patients were treated with fluoxetine postoperatively. Complete remission of symptoms was obtained in 86.4%.

Depression is common in primary care and the treatment is predominantly pharmaceutical or psychological¹². Fluoxetine is effective, safe and readily available for treating depression. However, while it is the first known selective serotonin reuptake inhibitor for treating patients with depression, fluoxetine is no more effective than a placebo for the relief of pain^{13,14}. In this

series, no complications of medication were observed. Two patients with mild or moderate depression obtained complete remission of symptoms and another two patients with severe depression obtained partial remission. As the course of fluoxetine treatment was short and the total dose small, the outcomes of these patients will be likely to improve with further medication.

Dissection of the styloid process via an extraoral approach is simple and reliable. In addition, as depression is one of main findings in patients with Eagle's syndrome, dissection of the styloid process combined with antidepressants (fluoxetine) is preferred for the treatment of Eagle's syndrome.

Conclusion

Dissection of the styloid process via an extraoral approach and combination with antidepressants (fluoxetine) is preferred for treating Eagle's syndrome.

References

1. Eagle WW. Elongated styloid process: symptoms and treatment. *AMA Arch Otolaryngol* 1958;67:172–176.
2. Prasad KC, Kamath MP, Reddy KJ, Raju K, Agarwal S. Elongated styloid process (Eagle's syndrome): a clinical study. *J Oral Maxillofac Surg* 2002;60:171–175.
3. Chen WL, Ren CN. Styloid syndrome and pterygo-uniforme syndrome. *Shiyong Kou Qiang Yi Xue Za Zhi* 1996;3:193–195 (in Chinese).
4. Beder E, Ozgursoy OB, Karatayli Ozgursoy S, Anadolou Y. Three-dimensional computed tomography and surgical treatment for Eagle's syndrome. *Ear Nose Throat J* 2006;85:443–445.
5. Sivers JE, Johnson GK. Diagnosis of Eagle's syndrome. *Oral Surg Oral Med Oral Pathol* 1985;59:575–577.
6. Evans JT, Clairmont AA. The nonsurgical treatment of Eagle's syndrome. *Eye Ear Nose Throat Mon* 1976;55:94–95.
7. Palesy P, Murray GM, De Boever J, Klineberg I. The involvement of the styloid process in head and neck pain – a preliminary study. *J Oral Rehabil* 2000;27:275–287.
8. Diamond LH, Cottrell DA, Hunter MJ, Papageorge M. Eagle's syndrome: a report of 4 patients treated using a modified extraoral approach. *J Oral Maxillofac Surg* 2001;59:1420–1426.
9. Mortellaro C, Biancucci P, Picciolo G, Vercellino V. Eagle's syndrome: importance of a corrected diagnosis and adequate surgical treatment. *J Craniofac Surg* 2002;13:755–758.
10. Chase DC, Zarmen A, Bigelow WC, McCoy JM. Eagle's syndrome: a comparison of intraoral versus extraoral surgical approaches. *Oral Surg Oral Med Oral Pathol* 1986;62:625–629.
11. Fini G, Gasparini G, Filippini F et al. The long styloid process syndrome or Eagle's syndrome. *J Craniomaxillofac Surg* 2000;28:123–127.
12. Cipriani A, Brambilla P, Furukawa T et al. Fluoxetine versus other types of pharmacotherapy for depression. *Cochrane Database Syst Rev* 2005;19:CD004185.
13. Max MB, Lynch SA, Muir J, Shoaf SE, Smoller B, Dubner R. Effects of desipramine, amitriptyline, and fluoxetine on pain in diabetic neuropathy. *N Engl J Med* 1992;326:1250–1256.
14. Tsapakis EM, Soldani F, Tondo L, Baldessarini RJ. Efficacy of antidepressants in juvenile depression: meta-analysis. *Br J Psychiatry* 2008;193:10–17.

