

Craniofacial Morphology of Chinese Patients with Bilateral Temporomandibular Joint Osteoarthritis

Zhi Peng SUN^{1,2}, Bing Shuang ZOU³, Yan Ping ZHAO^{1,2}, Xu Chen MA^{1,2}

Objective: To evaluate the morphological features of craniofacial structures in young patients affected by bilateral temporomandibular joint osteoarthritis (TMJOA).

Methods: Forty-three males and 189 females aged 15 to 25 years who had lateral cephalograms and temporomandibular joint (TMJ) radiological examinations were included. They were classified into a TMJOA group and a control group, according to TMJ bony status. Thirty-two variables from lateral cephalogram were analysed by *t* test to evaluate the cranial and dentofacial differences between the two groups.

Results: TMJOA group showed a shorter posterior ramus height and shorter condyles, smaller SNB angle and larger ANB angle, smaller facial plane angle and larger angle of convexity, steeper mandibular plane angle and more vertical y-axis.

Conclusion: Bilateral TMJOA is associated with dentofacial alterations characterised by a tendency toward retrognathism and shorter mandibles. However, the cause-and-effect relationship is yet to be clarified.

Key words: cephalometrics, osteoarthritis, temporomandibular joint

Temporomandibular disorders (TMD) refer to a variety of dysfunctional conditions affecting the temporomandibular joint (TMJ) and masticatory muscles. Temporomandibular joint osteoarthritis (TMJOA) is a non-inflammatory degenerative disease characterised by deterioration and abrasion of articular cartilage and underlying bone¹, which is generally considered as a subtype of TMD according to the Research Diagnostic Criteria of TMD (RDC-TMD)². It is not unusual to find teenagers or young adults to be affected³⁻⁶. TMJOA of teenagers or young adults stands a good chance to be

an isolated clinical entity in contrast with TMJOA in an aged population because of its special manifestations, due to potential harm on mandibular growth and development.

Contradictory findings and controversies exist in the theory of TMD aetiology and the interrelationship between TMD, malocclusion and orthodontic treatment. Both TMD and malocclusion are prevalent in teenagers or young adults, however, through after decades of endeavour, dentists still could not find convincing evidence to confirm the etiological role of malocclusion in the development of TMD, or vice versa. And orthodontic treatment performed during adolescence does not generally increase or decrease the risk of developing TMD in later life, according to longitudinal studies^{7,8}.

Even though, more and more evidence still indicates the significant correlation between TMD and certain kinds of mandibular deformity and subsequent malocclusion⁹⁻¹². Disc displacement with or without reduction, the most common subtype of TMD, was reported to be associated with decreased growth of the mandible^{10,13-16}. Characteristic features included decreased ramus height and mandibular length, a steep mandibular

1 Center for Temporomandibular Disorders and Orofacial Pain, Peking University School and Hospital of Stomatology, Beijing, P.R. China.

2 Department of Oral and Maxillofacial Radiology, Peking University School and Hospital of Stomatology, Beijing, P.R. China.

3 Department of Orthodontics, Peking University School and Hospital of Stomatology, Beijing, P.R. China.

Corresponding author: Dr Xu Chen MA, Department of Oral and Maxillofacial Radiology and Center for Temporomandibular Disorders and Orofacial Pain, Peking University School and Hospital of Stomatology, #22 Zhongguancun Nandajie, Haidian District, Beijing 100081, P.R. China. Tel: 86-10-62179977 ext 5345; Fax: 86-10-62173402; E-mail: kqxcma@bjmu.edu.cn

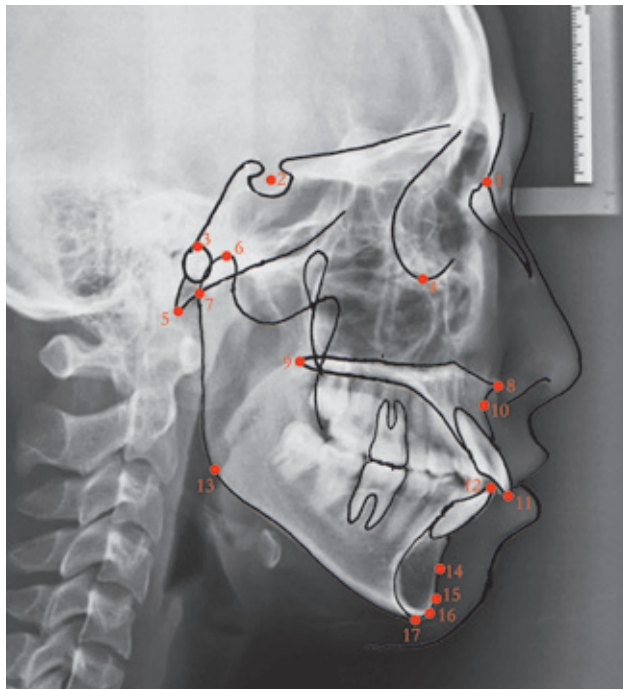
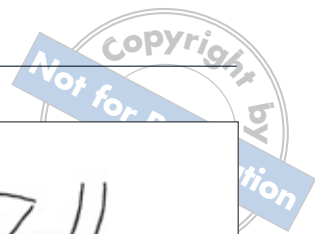


Fig 1 Cephalometric landmarks used in present study: 1) nasion (N); 2) sella (S); 3) porion (P); 4) orbitale (O); 5) basion (Ba); 6) condylion (Co); 7) articulare (Ar); 8) anterior nasal spine (ANS); 9) posterior nasal spine (PNS); 10) point A; 11) maxillary incisor; 12) mandibular incisor; 13) gonion (Go); 14) point B; 15) pogonion (Po); 16) gnathion (Gn); 17) menton (Me).

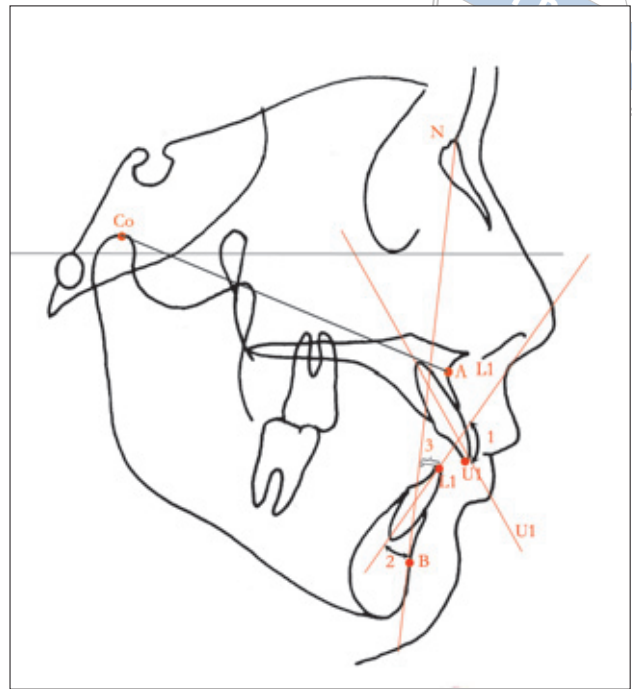


Fig 2 Significant measurements of maxillary position and denture pattern: 1) the angle U1 to L1; 2) the angle L1 to NB; 3) distance L1 point perpendicular to NB.

plane angle, and an increased profile convexity and retrognathism, which finally result in malocclusion. Facial asymmetry was also found to be associated with unilateral internal derangement or bilateral internal derangement of greater severity on the unilateral side¹⁷⁻¹⁹.

Similar findings have been reported in small sample studies^{3,20,21} on TMJOA patients, in which the effect of a selection bias may be prominent. It is rational to speculate that TMJOA in teenagers or young adults may potentially lead to similar or even more prominent alterations of craniofacial morphology. Gaining an insight into this issue will improve our understanding in the aetiology of both TMD and malocclusion, deepen our knowledge of their interaction and thus provide a basis for diagnosis, prognosis and prediction for treatment outcome in growing individuals.

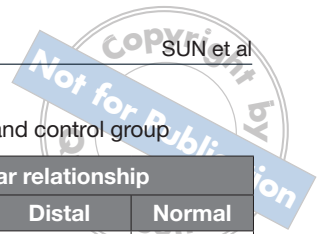
The purpose of the present study is to determine whether any association exists between TMJOA and abnormalities of the dentofacial morphology in a large series of Chinese patients and to further discuss the possible mechanism working behind.

Materials and methods

Sample

The subjects consisted of 232 patients aged 15 to 25 years seeking orthodontic treatment in the unit. All subjects underwent systemic clinical and radiological TMJ examinations. Imaging procedures of the TMJ included panoramic radiography, transcranial and transpharyngeal radiography. Three experienced radiologists interpreted all the images to make the diagnosis. Subjects with one or more of the following radiological findings were diagnosed as TMJOA: erosion of normal cortical delineation, sclerosis of the condyle and articular eminence, flattening of joint surfaces, and osteophyte formation.

The subjects were classified into two groups according to the TMJ bony status. The study group consisted of 113 patients affected by bilaterally TMJOA and the other 119 subjects unaffected by TMJOA were

**Table 1** Comparisons of mean ages and constituent ratios of gender and molar relationship in TMJOA and control group

Groups	Total number	Age (mean \pm SD)	Gender		Molar relationship		
			Males	Females	Medial	Distal	Normal
TMJOA group	113	20.0 \pm 6.9	24	89	13	67	33
Control group	119	20.4 \pm 6.9	19	100	13	68	38

Table 2 Comparisons of cephalometric variables of subjects of TMJOA group and control group

Variables	TMJOA group (n = 113)		Control group (n = 119)		t value	P Value
	Mean	SD	Mean	SD		
Cranial base relationship						
Posterior cranial base length [Ba-S] (mm)	48.09	3.56	46.90	3.57	2.548	0.011†
Anterior cranial base length [S-N] (mm)	68.84	3.17	68.92	3.28	-0.206	0.837
Full cranial base length [Ba-N](mm)	107.05	5.71	106.63	4.97	0.601	0.549
Saddle angle [Ba-S-N] (degrees)	133.18	5.22	133.67	5.79	-0.672	0.502
Morphology and sagittal position of maxilla						
Maxillary length [ANS-PNS] (mm)	50.61	5.16	49.40	5.06	1.813	0.071
Effective maxillary length [Co-A] (mm)	85.12	5.02	86.53	4.65	-2.207	0.028†
SNA (degrees)	79.27	4.16	78.94	3.50	0.644	0.520
Denture pattern relationship						
U1 to SN (degrees)	105.81	8.62	107.16	8.42	-1.202	0.231
U1 to NA (degrees)	26.37	8.06	28.15	7.40	-1.760	0.080
U1 to L1 (degrees)	114.78	12.32	118.78	11.97	-2.508	0.013†
L1 to MP (degrees)	96.67	7.44	95.72	8.54	0.891	0.374
L1 to NB (degrees)	32.99	7.61	28.64	7.72	3.007	0.003‡
U1 perpendicular to NA (mm)	6.41	3.96	7.06	3.46	-1.340	0.182
L1 perpendicular to NB (mm)	9.19	3.44	7.90	3.08	3.007	0.003‡
Overjet (parallel to FH) (mm)	5.50	2.93	5.43	3.31	0.167	0.867
Overbite (perpendicular to FH) (mm)	1.92	2.95	3.87	2.63	-5.303	0.000‡
Morphology and position of mandible						
Co-Go (mm)	55.84	5.91	62.46	5.99	-8.478	0.000‡
Ar-Go (mm)	45.26	5.25	48.45	5.59	-4.474	0.000‡
Go-Pog (mm)	75.60	4.85	76.78	5.54	-1.719	0.087
Co-Pog (mm)	112.29	6.07	116.46	7.02	-4.834	0.000‡
Height of condyle (mm)	18.93	4.03	23.07	3.32	-8.563	0.000‡
SNB (degrees)	73.97	4.10	75.05	4.29	-1.954	0.042†
ANB (degrees)	5.30	3.39	3.90	3.13	3.279	0.001‡
Gonial angle (degrees)	123.73	6.73	121.21	7.73	2.644	0.009†
Antegonial notch (degrees)	151.60	11.92	159.69	9.33	-5.773	0.000‡
Facial profile analysis						
Y axis (degrees)	65.76	4.55	63.04	4.15	4.753	0.000‡
NA to PA (degrees)	11.06	7.85	7.59	6.96	3.566	0.000‡
FH to NA (degrees)	89.51	3.70	90.11	3.50	-1.273	0.204
FH to NP (degrees)	84.45	4.81	86.60	3.97	-3.736	0.000‡
FH to MP (degrees)	32.58	7.63	26.73	6.72	6.201	0.000‡
N-Me (mm)	129.02	6.84	128.50	7.47	0.544	0.587
ANS-Me (mm)	73.38	6.16	71.82	6.05	1.947	0.053

†The mean difference is significant at the 0.05 level; ‡The mean difference is significant at the 0.01 level

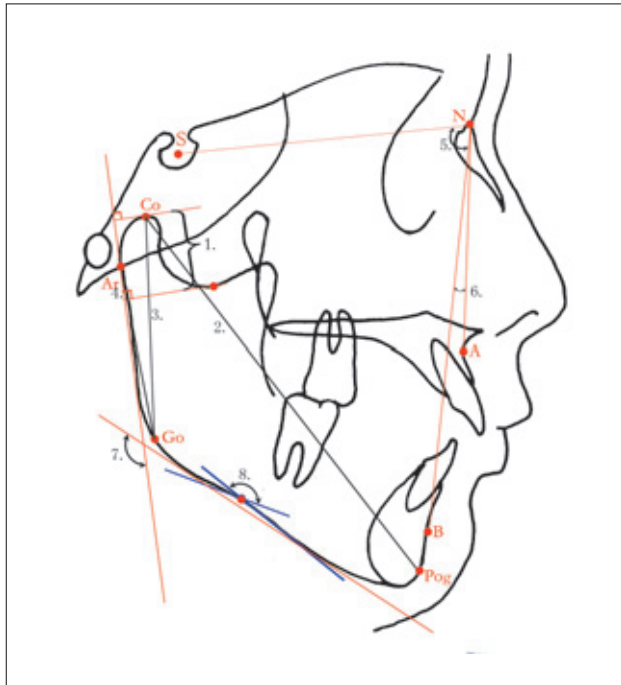


Fig 3 Significant measurements of the morphology and position of mandible: 1) the measurements of condylar height; 2–4) measurements of distances of Co-Pog, Co-Go, Ar-Go; 5 and 6) SNB and ANB angle; 7 and 8) The gonial angle and the angle of antegonial notch.

included as control group. Subjects of the control group all conformed to the following inclusion criteria: no subjective symptoms of joint pain, sound, locking or positive history of TMD; no TMD-related clinical signs such as clicking sounds, abnormal mandibular movement or TMJ and masticatory muscles tenderness; no osteoarthritis findings based on radiological examination. Patients with a history of previous orthodontic treatments, infection, tumour, rheumatoid disease, TMJ injuries or other pathology affecting the craniofacial region were also excluded in present study.

The subjects in two groups were matched in the distribution of age ($t = -0.388$, $P = 0.859$), gender ($\chi^2 = 1.971$, $P = 0.373$) and Angle classification ($\chi^2 = 1.847$, $P = 0.764$). Details of the subjects' information were listed in Table 1. t test and chi-square analysis were used in the statistics.

All participants read and signed informed consents before the study initiation. The study was approved by the Institutional Review Board of Peking University.

Cephalometric radiography and analysis

Lateral cephalograms were taken to all the subjects on the same radiographic machine with their teeth in centric occlusion and the Frankfort horizontal plane parallel to the floor. The cephalograms were manually traced on acetate papers and the cephalometric analysis was done by one of the authors (Sun). The cephalometric landmarks and the angular and linear measurements used in this study were listed in Figure 1 and Table 2. These variables were subdivided into five groups: cranial base relationship, denture pattern relationship, size and position of maxilla, size and position of mandible and facial profile. The error of the method was determined by retracing each cephalogram on two separate occasions, two weeks after the first tracing. The mean value of two measurements was used for statistical analysis.

Statistical analysis

Software of Statistical Package for Social Sciences (SPSS, Version 11.5) was used in the data analysis. The mean values and standard deviations (SD) were calculated for all variables. A Student t test was used to test the differences of means between two groups. The probability value (P value) was calculated in each of the tests and a level of significance was established at 0.05.

Results

The results of the measurements were summarised in Table 2. Eighteen out of the 32 cephalometric variables showed statistically significant differences between the two groups. The differences were generally attributed to the morphology of mandible and maxillomandibular positional relationship.

In the variables for cranial base relationship, only the variable of posterior cranial base (S-Ba) was statistically longer in TMJOA group than in control group. As for the morphology and position of maxilla, the variable describing the effective maxillary length (Co-A) was reduced in TMJOA group (Fig 2). The measurements of denture pattern relationship revealed that patients with TMJOA were statistically smaller in the angle of U1 to L1 and overbite, but larger in the angle of L1 to NB and the distance of L1 perpendicular to NB (Fig 2).

As for the analysis of morphology and position of mandible, patients with bilateral TMJOA were significantly smaller in the linear variables of Co-Go, Ar-Go, Co-Pog, in the height of condyle. The angle of antegonial notch was smaller and the gonial angle was

larger. The angle of SNB was smaller and the ANB angle was larger (Fig 3).

In the facial profile analysis, the angles of Y-axis, NA to PA, FH to MP were statistically larger and the angle of FH to NP was smaller in TMJOA group than in the control group (Fig 4).

Discussion

Signs and symptoms of TMD were quite prevalent in adolescents or young adults with malocclusions, before or during their orthodontic treatments. This constitutes an important and complex clinical problem. The relationship between malocclusion, TMD and orthodontic treatment has been a topic with great contention for decades and is still pending up to now. On one hand, there is not enough reliable evidence to confirm the etiological role of malocclusion in the development of TMD. And orthodontic treatment is contemporarily considered neither to cause nor to prevent TMD^{22,23}. And on the other hand, constantly emerging articles still keep stressing the mutual relationship between TMD, malocclusion and orthodontics.

An important confounding factor working behind in this topic, which could be easily overlooked is the craniofacial growth pattern, especially the growth pattern of the mandible. More and more studies have confirmed the association between mandibular retrognathism and TMD^{9-11,13}. Internal derangements (ID), the most common type of TMD, were closely correlated with the mandibular morphological deficiencies. TMJ disc abnormality was associated with reduced forward growth of the maxillary and mandibular bodies¹¹. Moreover, this trend becomes more severe as internal derangement progresses from disc displacement with reduction, to disc displacement without reduction. In animal experiments, surgically created disc displacement without reduction could impair mandibular growth and generate mandibular retrognathia²⁴⁻²⁸. From another point of view, cephalometric analysis is considered helpful in identifying and predicting potential patients with internal derangement of the TMJ¹⁰.

Osteoarthritis can begin or occur at a very young age and develops with prominent facial growth anomalies⁶. Studies in recent years reinforced the opinion that TMJ osteoarthritis was closely related to the shortening of the mandible. Based on a comparative study of 29 female patients, Gidarakou et al found out that patients with bilateral degenerative joint disease showed an overall retrusion of the maxilla and mandible with a clockwise mandibular rotation²¹. Ali et al compared 14 subjects with bilateral TMJ condylar changes with 14

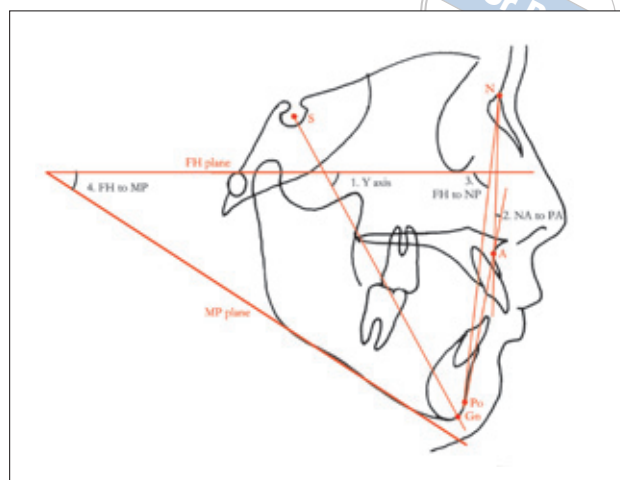


Fig 4 Significant measurements of profile analysis: 1) Y-axis; 2) the angle of NA to PA; 3) the angle of FH to NP; 4) the angle of FH to MP.

subjects without bone change and found that antegonial and ramus notch depths were significantly greater in the subjects with TMJ bone changes. At the same time, greater ANB angle, smaller SNB angle and shorter ramus height and mandibular body lengths were also found in the subject with TMJ bone changes²⁰. In a study of TMJ osteoarthritis patients, Yamada et al found that retrognathic mandibles were shown in 16 bilateral cases and lateral shifts of the mentons toward the affected sides were shown in 13 unilateral cases³.

Previous studies were usually based on small-sized samples, in which selection bias cannot be overlooked and could be significant. In consideration of the high prevalence of TMJOA in both the young and aged population, studies with large sample sizes should be designed to compensate for the inevitable sampling error. For this purpose, 113 subjects with TMJOA were included in present study and 119 subjects were included as a control group. The subjects of two groups in present study were matched in age, gender and Angle classification of malocclusion. The influence of factors

such as age and gender on craniofacial growth could be compensated so that the morphological changes could be more reliably ascribed to the joint status.

According to the results of present study, alterations of the craniofacial bones in the TMJOA group were mostly ascribed to the morphology and position of the mandible. Subjects of TMJOA group had a statistically shorter ramus height (Co-Go) and the effective mandibular length (Co-Pog). But no significant difference was observed in the mandibular body length (Go-Pog). These findings indicate that the ramus is most obviously affected by the joint status, while the decreased effective mandibular length may be secondary.

Angular measurements of the lateral facial profile also showed significant differences in the vertical relationship. The angles of Y axis, NA to PA, FH to MP were larger and FH to NP became smaller in the TMJOA group, indicating the steeper mandibular plane angle, backward rotation and retrusion of the mandible. These changes could be logically due to the degenerative changes of the condyle and subsequent shortening of the ramus. At the same time, the larger gonial angle and smaller antegonial notch observed in TMJOA group strongly suggest the close correlation between TMJOA development and mandibular morphogenesis.

As the mandible rotates backwards and becomes smaller, compensatory dental changes occur. A decreased angle between maxillary and mandibular incisors (U1 to L1) and prominent labial inclination of mandibular incisor was seen. The inclination of maxillary incisor showed no changes compared with normal controls. As for the alterations of the maxilla, Gidarakou et al found out that the measurements of SNA, FH to Na-A and ANS-PNS were smaller in bilateral TMJOA patients²¹, which indicates both morphological shrinkage and backward positioning in maxilla. However, according to the results of present study, no significant change was seen in the angular measurements of SNA and FH to NA. The linear measurements of ANS to PNS also showed little difference in two groups. Only slight change was seen in the linear measurement of effective maxillary length (Co to A). Although it sounds logical that maxillary changes may occur secondary to the mandibular retrusion, more strictly designed studies are still needed for further consolidation.

Although more and more evidence correlates various subtypes of TMD and mandible morphology, there is still not enough evidence to elucidate the cause-and-effect relationship in light of the rarity of longitudinal or prospective study. Most of previous studies in this topic were cross-sectional and little information is provided about the sequencing of the two observed phenomena.

Disc displacements or TMJOA may affect facial growth or occur as a consequence of biomechanics associated with altered facial pattern as well.

Therefore, several influences may be working between TMD, malocclusion and dentofacial deformities.

Firstly, TMD has a greater possibility to be the cause and the alterations in skeletal morphology are the sequela²⁹, especially in the adolescent population. TMJ represents important growth sites within the dentofacial skeleton and the TMJ biophysical environment is of utmost importance in mandibular growth. Many other diseases of the temporomandibular joint, such as inflammation or trauma, were unanimously regarded to be detrimental to the development. Animal experiments also found that disc displacement occurred during the developmental period induced impairment of mandibular growth^{27,28}.

Secondly, the acquired skeletal deformity and subsequent unstable malocclusion may contribute as a promoting factor for TMD development because the mastication system becomes much weaker and more susceptible to micro- or macro-trauma of the TMJ and subsequent functional disorder and degenerative changes¹. From the perspective of human evolution, the decreased size of the mandible, compared with prehistoric humans, contributes to the vulnerability of the mastication apparatus in modern people, which accounts for the high prevalence of TMD in various populations.

Last but not the least, mandible growth deficiency also results in Class II malocclusions such as deep overbite and overjet, reasonably correlating certain kinds of malocclusion with TMD. Thus, the mandible growth pattern is an important confounding factor influencing both the occlusal status and the temporomandibular function³⁰. The three prevalent problems including TMD, malocclusion and impaction of wisdom teeth could be logically conjectured to be serial phenomena, due to the evolution of the human mandible.

The normal physiological environment of TMJ provides biomechanical and functional response to the orthodontic or orthopaedic forces. The response of structurally damaged TMJ might be unfavourable because the adaptive capacity of the joints is altered. A previous study showed that patients with bilateral anterior disc displacement without reduction showed little skeletal changes during orthodontic treatment, compared to those with normal TMJ or with bilateral anterior disc displacement with reduction³¹. Although the orthodontic effect of patients with TMJOA is still to be explored, treatment should be carefully applied.

Bilateral osteoarthritis of TMJ in a young population associate positively with the craniofacial skeletal changes, which are mostly characterised by the shortening of the ramus and backward rotation of the mandible. However, longitudinal prospective studies should be carried out to further elucidate the cause-and-effect relationship.

Acknowledgments

This work was supported by the National Program for Key Science and Technology Projects of China (Grant number: 2004BA720A25).

References

1. Tanaka E, Detamore MS, Mercuri LG. Degenerative disorders of the temporomandibular joint: etiology, diagnosis, and treatment. *J Dent Res* 2008;87:296–307.
2. Dworkin SF, LeResche L. Research diagnostic criteria for temporomandibular disorders: review, criteria, examinations and specifications, critique. *J Craniomandib Disord* 1992;6:301–355.
3. Yamada K, Hiruma Y, Hanada K et al. Condylar bony change and craniofacial morphology in orthodontic patients with temporomandibular disorders (TMD) symptoms: a pilot study using helical computed tomography and magnetic resonance imaging. *Clin Orthod Res* 1999;2:133–142.
4. Yamada K, Hanada K, Hayashi T, Ito J. Condylar bony change, disk displacement, and signs and symptoms of TMJ disorders in orthognathic surgery patients. *Oral Surg Oral Med Oral Pathol Oral Radiol Endod* 2001;91:603–610.
5. Ogus H. Degenerative disease of the temporomandibular joint in young persons. *Br J Oral Surg* 1979;17:17–26.
6. Katzberg RW, Tallents RH, Hayakawa K et al. Internal derangements of the temporomandibular joint: findings in the pediatric age group. *Radiology* 1985;154:125–127.
7. Sadowsky C, Polson AM. Temporomandibular disorders and functional occlusion after orthodontic treatment: results of two long-term studies. *Am J Orthod* 1984;86:386–390.
8. Macfarlane TV, Kenealy P, Kingdon HA et al. Twenty-year cohort study of health gain from orthodontic treatment: temporomandibular disorders. *Am J Orthod Dentofacial Orthop* 2009;135:692–693.
9. Miller JR, Burgess JA, Critchlow CW. Association between mandibular retrognathia and TMJ disorders in adult females. *J Public Health Dent* 2004;64:157–163.
10. Ahn SJ, Baek SH, Kim TW, Nahm DS. Discrimination of internal derangement of temporomandibular joint by lateral cephalometric analysis. *Am J Orthod Dentofacial Orthop* 2006;130:331–339.
11. Flores-Mir C, Nebbe B, Heo G, Major PW. Longitudinal study of temporomandibular joint disc status and craniofacial growth. *Am J Orthod Dentofacial Orthop* 2006;130:324–330.
12. Miller JR, Mancl L, Critchlow C. Severe retrognathia as a risk factor for recent onset painful TMJ disorders among adult females. *J Orthod* 2005;32:249–256.
13. Hwang CJ, Sung SJ, Kim SJ. Lateral cephalometric characteristics of malocclusion patients with temporomandibular joint disorder symptoms. *Am J Orthod Dentofacial Orthop* 2006;129:497–503.
14. Twilt M, Schulten AJ, Nicolaas P et al. Facioskeletal changes in children with juvenile idiopathic arthritis. *Ann Rheum Dis* 2006;65:823–825.
15. Sidiropoulou-Chatzigianni S, Papadopoulos MA, Kolokithas G. Dentoskeletal morphology in children with juvenile idiopathic arthritis compared with healthy children. *J Orthod* 2001;28:53–58.
16. Ahn SJ, Kim TW, Nahm DS. Cephalometric keys to internal derangement of temporomandibular joint in women with Class II malocclusions. *Am J Orthod Dentofacial Orthop* 2004;126:486–494, discussion 494–495.
17. Ahn SJ, Lee SP, Nahm DS. Relationship between temporomandibular joint internal derangement and facial asymmetry in women. *Am J Orthod Dentofacial Orthop* 2005;128:583–591.
18. Buranastidporn B, Hisano M, Soma K. Temporomandibular joint internal derangement in mandibular asymmetry. What is the relationship? *Eur J Orthod* 2006;28:83–88.
19. Trpkova B, Major P, Nebbe B, Prasad N. Craniofacial asymmetry and temporomandibular joint internal derangement in female adolescents: a posteroanterior cephalometric study. *Angle Orthod* 2000;70:81–88.
20. Ali IM, Yamada K, Hanada K. Mandibular antegonial and ramus notch depths and condylar bone change. *J Oral Rehabil* 2005;32:1–6.
21. Gidarakou IK, Tallents RH, Kyrkanides S et al. Comparison of skeletal and dental morphology in asymptomatic volunteers and symptomatic patients with bilateral degenerative joint disease. *Angle Orthod* 2003;73:71–78.
22. Ueki K, Nakagawa K, Marukawa K et al. The relationship between temporomandibular joint disc morphology and stress angulation in skeletal Class III patients. *Eur J Orthod* 2005;27:501–506.
23. Katzberg RW, Westesson PL, Tallents RH, Drake CM. Orthodontics and temporomandibular joint internal derangement. *Am J Orthod Dentofacial Orthop* 1996;109:515–520.
24. Legrell PE, Isberg A. Mandibular height asymmetry following experimentally induced temporomandibular joint disk displacement in rabbits. *Oral Surg Oral Med Oral Pathol Oral Radiol Endod* 1998;86:280–285.
25. Bryndahl F, Eriksson L, Legrell PE, Isberg A. Bilateral TMJ disk displacement induces mandibular retrognathia. *J Dent Res* 2006;85:1118–1123.
26. Hatala MP, Macher DJ, Tallents RH et al. Effect of a surgically created disk displacement on mandibular symmetry in the growing rabbit. *Oral Surg Oral Med Oral Pathol Oral Radiol Endod* 1996;82:625–633.
27. Legrell PE, Isberg A. Mandibular length and midline asymmetry after experimentally induced temporomandibular joint disk displacement in rabbits. *Am J Orthod Dentofacial Orthop* 1999;115:247–253.
28. Legrell PE, Reibel J, Nylander K et al. Temporomandibular joint condyle changes after surgically induced non-reducing disk displacement in rabbits: a macroscopic and microscopic study. *Acta Odontol Scand* 1999;57:290–300.
29. Schellhas KP, Pollei SR, Wilkes CH. Pediatric internal derangements of the temporomandibular joint: effect on facial development. *Am J Orthod Dentofacial Orthop* 1993;104:51–59.
30. Dibbets JM, van der Weele LT. Signs and symptoms of temporomandibular disorder (TMD) and craniofacial form. *Am J Orthod Dentofacial Orthop* 1996;110:73–78.
31. Ahn SJ, Lee SJ, Kim TW. Orthodontic effects on dentofacial morphology in women with bilateral TMJ disk displacement. *Angle Orthod* 2007;77:288–295.