

Non-syndromic Multiple Supernumerary Teeth: A Case Report and Review of Literature

Idris Faiq Qaradaghi¹

Multiple supernumerary teeth are rare anomalies of the maxillofacial complex and often occur with some congenital syndromes. This article reports a case of non-syndromic multiple supernumerary teeth with some impacted in both jaws.

Key words: non-syndromic, multiple supernumerary teeth, impacted teeth

A supernumerary tooth is an additional one to the normal tooth and can be found in almost any region of the dental arch¹. Supernumerary teeth were first reported between AD 23 and 79². Luten³ in 1967 reported the region of supernumerary tooth in a decreasing frequency as follows: upper lateral incisors (50%), mesiodens (36%), upper central incisors (11%), followed by premolars (3%). Supernumerary teeth can be classified based on the time of appearance, according to the position of the arch and their shape⁴. Supernumerary teeth may be single, multiple, unilateral or bilateral, erupted or unerupted and in one jaw or both. Among the supernumerary teeth, mesiodens is the most common type⁵. Multiple supernumerary teeth are reported to be associated with some syndromes such as cleft lip and palate, cleidocranial dysostosis, Gardner's syndrome, chondroectodermal dysplasia and so on. Multiple supernumerary teeth without any syndrome are very rare⁶.

Human dental eruption is known to be a dynamic interaction between heredity and environment. It is widely assumed that the development of supernumerary teeth or congenitally missing teeth may involve a genetic factor and, hence, may show a familial tendency⁷. The incidence of supernumerary teeth varies between 1.6 and 3.1% in the literature⁸. Studies have found the prevalence of supernumerary teeth in permanent dentition

ranges from 0.15 to 3.8%⁹. However, the prevalence has been reported as no more than 1% when 'multiple supernumerary teeth' is taken to mean five or more supernumerary teeth^{10,11}.

Supernumerary teeth can be found anywhere in the dentition; however, there is a predisposition for them to occur in the premaxillary region. Luten³ found that 97% of supernumerary teeth were located in the anterior region with only 3% representing the premolar region, while Bodin et al¹² found 10.9% of supernumerary teeth to be premolars. World-wide, many studies have reported the prevalence of supernumerary canines, which has been estimated as 0 to 15%¹¹. Clayton⁸ reported that supernumerary teeth occur about twice that in the permanent dentition, and Brook¹³ reported that supernumerary teeth were present in 0.8% of primary dentitions and 2.1% of permanent dentitions when 2000 school children were surveyed. Although there is no significant sex distribution in primary supernumerary teeth, males are affected approximately twice as frequently as females in the permanent dentition¹⁴.

Case Report

A 17-year-old female patient was referred to Peramerd Dental Specialty Center, Department of Oral and Maxillofacial Surgery, Sulaimany, Kurdistan, Iraq, in May 2009, with the chief complaint of non-eruption of a number of teeth. The family medical and dental histories were non-contributory. General examination and extra-oral examination did not show any abnormality.

Clinical examination showed the absence of two teeth in the lower arch, five teeth in the upper arch and

¹ Oral and Maxillofacial Surgery Department, Peramerd Dental Specialty Centre, Sulaimani, Kurdistan, Iraq

Corresponding author: Dr Idris Faiq Qaradaghi, Oral and Maxillofacial Surgery Department, Peramerd Dental Specialty Centre, Peramerd Street, Sulaimany, Kurdistan, Iraq. E-mail: dr_idris2008@yahoo.com

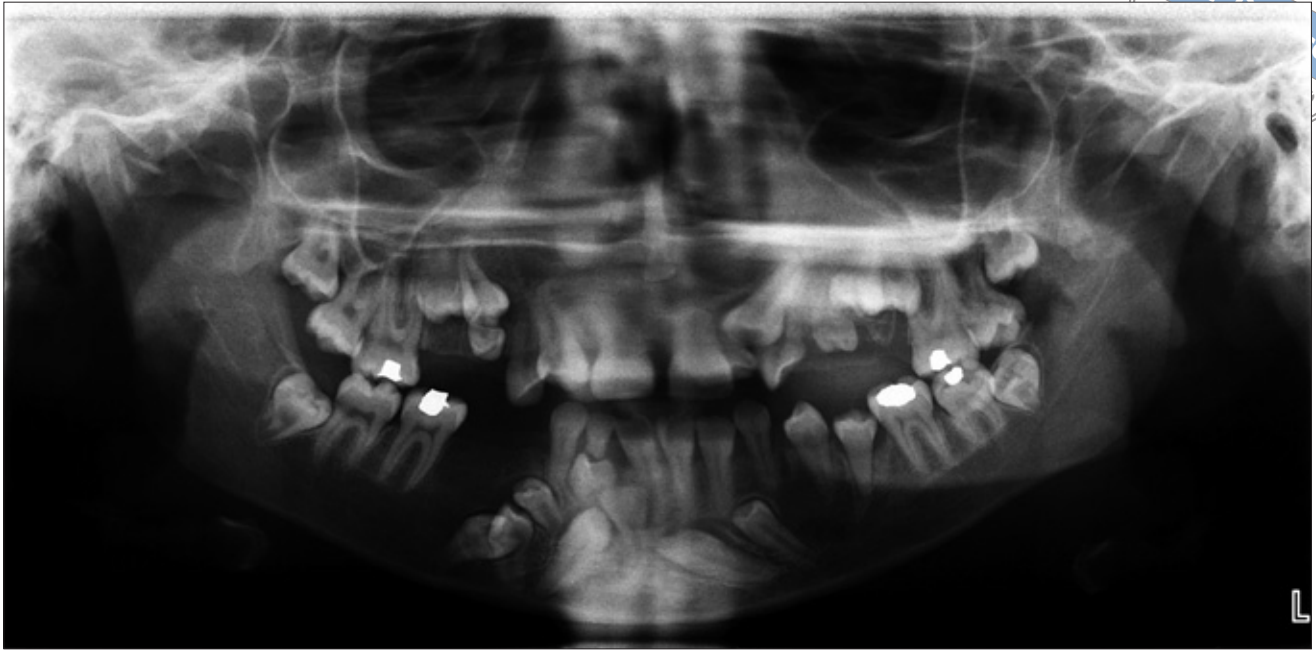

Fig 1 Panoramic radiograph showing the presence of impacted teeth, some of which are supernumerary teeth.

one partially erupted tooth in the region of lateral and canine teeth. The panoramic radiograph showed the presence of 16 impacted teeth in all four quadrants (Fig 1). In the maxilla, they were located bilaterally in the premolar regions. In the middle part of the mandible, eight impacted teeth were located as a group.

The upper right quadrant showed the presence of three impacted teeth. Impacted teeth exhibited the normal morphology of premolars, two of which were first and second premolars and the third one was a supernumerary premolar which was situated over the first premolar. The upper left quadrant showed the presence of five unerupted teeth and one semi-erupted tooth, of which one was premolar and another was canine in shape. The remaining four teeth had fully formed crowns that appeared to be conical in shape and smaller than that of a normal tooth, indicating that they were supernumerary teeth. In addition, congenital missing of a lateral incisor and one premolar were confirmed by exclusion of the history of extraction in the region.

As noted above, the middle part of the mandible showed the presence of eight impacted teeth. The lower right quadrant showed the presence of six impacted teeth, two of which exhibited the normal morphology of premolars; the others were unclear and not accurate. The lower left quadrant showed the presence of two impacted teeth, which were in the form of supernumerary canines. Of the two supernumerary canines, one

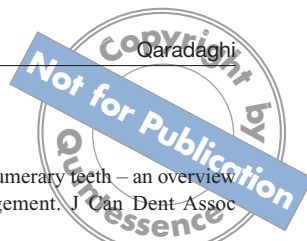
canine was impacted mesioangularly, crossed the midline and transmigrated to the right.

Since a general physician was consulted to confirm that there were no typical symptoms of any known syndromes, the girl was diagnosed with multiple supernumerary teeth without syndrome.

Discussion

Yusof¹⁵ reviewed most of the cases reported in the English literature from 1969 to 1990. He reported a predilection of non-syndrome multiple supernumerary teeth to occur in the mandible. When analysed according to specific sites for both jaws, there was a predominance of multiple supernumerary teeth in the premolar area. Bodin et al¹² also reported that supernumerary premolars have a predisposition for the mandible.

The aetiology of supernumerary teeth still remains unclear. Many hypotheses concerning the cause of supernumerary teeth have been suggested, but their occurrence has not yet been fully clarified. It has been suggested that supernumerary teeth result from atavism or reversion. Aberrations during embryological formation may cause supernumerary teeth formation and it is believed that supernumerary teeth arise from local, independently conditioned hyperactivity of dental lamina or remnants of dental lamina^{16,17}. It is also possible that supernumerary teeth may result from division of a



developing tooth bud (dichotomy). There are a number of factors that might split a normal tooth germ and give rise to the development of multiple individual teeth¹⁸.

Heredity is an important factor in the occurrence of supernumerary teeth. An autosomal dominant trait has been suggested by Sedano and Gorlin¹⁹. Supernumerary teeth have occasionally occurred in the same family²⁰.

Supernumerary teeth can have both normal and abnormal morphology. In abnormal morphology, supernumerary teeth are rudimentary in shape and smaller in size²¹. The case reported here possessed both types: four resembled normal tooth morphology and six appeared conical and small in size. Of the 10 teeth, five were located in the upper premolar regions, not in agreement with the report of Açıkgöz et al⁹; the remainder were in the mandible, in agreement with the reports of Bodin et al¹² and Yusof¹⁵

It was rare to find two canines (in the left quadrant) of the five mandibular supernumerary teeth in the present case. Most of the supernumerary canines were maxillary canines^{22,23}. An even rarer finding in the present case was the migration of the impacted canine to the contralateral hemiarch. This phenomenon is known as transmigration, and it occurs almost exclusively with mandibular canines^{24,25}.

Supernumerary teeth may cause various pathologies, although approximately 75% of supernumerary teeth are impacted and asymptomatic, and most of these teeth are diagnosed coincidentally during radiographic examination⁹. Supernumerary teeth might cause dental abnormalities, such as delayed eruption or impaction of permanent teeth, malposition of supernumerary teeth or displacement of adjacent teeth. Such eruption disturbances can be prevented by early diagnosis and appropriate treatment.

Early diagnosis is important to minimise the risk of complications resulting from supernumerary teeth. If they have caused delay or non-eruption of permanent teeth, displacement of permanent teeth, or root resorption of adjacent teeth due to pressure and cystic formations, then extraction is recommended⁶.

In the present case, the patient was informed about the presence of the additional number of teeth and was advised to have those disturbing the eruption of other teeth extracted and occlusion management. However, the patient did not take the advice.

References

1. Garvey MT, Barry HJ, Blake M. Supernumerary teeth – an overview of classification, diagnosis and management. *J Can Dent Assoc* 1999;65:612–616.
2. Weinberger BW. *An Introduction to the History of Dentistry*. St. Louis, MO: Mosby Co., 1948:514.
3. Luten JR Jr. The prevalence of supernumerary teeth in primary and mixed dentitions. *J Dent Child* 1967;34:346–353.
4. Shashikiran ND, Reddy VV, Mandrolu P. Molariform supernumerary tooth – a case report. *J Indian Soc Pedod Prev Dent* 2000;18:18–20.
5. Rajendran R, Sivapathasundaram B. *Shafer's Textbook of Oral Pathology*, ed 5. New Delhi, India: Elsevier, 2006.
6. Scheiner MA, Sampson WJ. Supernumerary teeth: a review of the literature and four case reports. *Aust Dent J* 1997;42:160–165.
7. Zhu JF, Marcusshamer M, King DL, Henry RJ. Supernumerary and congenitally absent teeth: a literature review. *J Clin Pediatr Dent* 1996;20:87–95.
8. Clayton JM. Congenital dental anomalies occurring in 3,557 children. *J Dent Child* 1956;23:206–208.
9. Açıkgöz A, Açıkgöz G, Tunga U, Otan F. Characteristics and prevalence of non-syndrome multiple supernumerary teeth: a retrospective study. *Dentomaxillofac Radiol* 2006;35:185–190.
10. Asaumi JI, Shibata Y, Yanagi Y, Hisatomi M, Matsuzaki H, Konouchi H, Kishi K. Radiographic examination of mesiodens and their associated complications. *Dentomaxillofac Radiol* 2004;33:125–127.
11. Rajab LD, Hamdan MA. Supernumerary teeth: a review of the literature and a survey of 152 cases. *Int Pediatr Dent* 2002;12:244–254.
12. Bodin I, Julin P, Thomsson M. Hyperdontia: I. Frequency and distribution of supernumerary teeth among 21,609 patients. *Dentomaxillofac Radiol* 1978;7:15–17.
13. Brook AH. Dental anomalies of number, form and size: their prevalence in British school children. *J Int Assoc Dent Child* 1974;5:37–53.
14. Kinirons MJ. Unerupted premaxillary supernumerary teeth. A study of their occurrence in males and females. *Br Dent J* 1982;153:110.
15. Yusof WZ. Non-syndrome multiple supernumerary teeth: literature review. *J Can Dent Assoc* 1990;56:147–149.
16. Liu JF. Characteristics of premaxillary supernumerary teeth: a survey of 112 cases. *ASDC J Dent Child* 1995;62:262–265.
17. Gallas MM, Garcia A. Retention of permanent incisors by mesiodense: a family affair. *Br Dent J* 2000;188:63–64.
18. Hattab FN, Yassin OM, Rawashdeh MA. Supernumerary teeth: report of three cases and review of literature. *J Dent Child* 1994;61:382–393.
19. Sedano HO, Gorlin RJ. Familial occurrence of mesiodens. *Oral Surg Oral Med Oral Pathol* 1969;27:360–361.
20. Brook AH. A unifying aetiological explanation for anomalies of human tooth number and size. *Arch Oral Biol* 1984;29:373–378.
21. Pindborg JJ. *Pathology of the Dental Hard Tissues*. Copenhagen: Munksgaard, 1970.
22. Shetty R, Sandler PJ. Keeping your eye on the ball. *Dent Update* 2004;31:398–402.
23. Turkkahraman H, Yölmaz HH, Üetin E. A non-syndrome case with bilateral supernumerary canines: report of a rare case. *Dentomaxillofac Radiol* 2005;34:319–321.
24. Aydin U, Yılmaz HH, Yildirim D. Incidence of canine impaction and transmigration in a patient population. *Dentomaxillofac Radiol* 2004;33:164–169.
25. Aydin U, Yılmaz HH. Transmigration of impacted canines. *Dentomaxillofac Radiol* 2003;32:198–200.