

Malignant Peripheral Nerve Sheath Tumour on Gingiva: a Case Report

Yun WANG¹, He LIU¹

A rare case of a malignant peripheral nerve sheath tumour occurring on gingiva in a 9-year-old Chinese girl is presented.

Key words: malignant peripheral nerve sheath tumour, gingiva, children

Malignant peripheral nerve sheath tumour (MPNST) is an uncommon malignant spindle-cell tumour of soft tissues, with a reported incidence of 1/1,000,000 people. The most common phenotype of MPNST is an enlarging mass, with or without other symptoms, such as pain or paraesthesia¹.

MPNST is reported to have a poor prognosis, with a high incidence of local recurrence and distant metastasis. The most common sites of MPNST in children are upper and lower extremities, head and neck, and trunk². Here, a rare case of MPNST is reported which occurred on the maxillary gingiva in a child.

Case Report

A 9-year-old girl complaining of asymptomatic gingival swelling visited the Department of Pediatric Dentistry, Peking University School and Hospital of Stomatology, Beijing. The swelling had been noted unintentionally a day before the hospital visit. There was nothing special

in her medical history. Family history indicated that her elder brother died of a brain tumour at around 1 year old.

Clinical examination revealed a 50 mm × 20 mm × 30 mm mass attached to the buccal and palatal gingiva of the upper left premolar region (Fig 1). The mass over-curtained the mesial part of the first molar and the erupting first premolar except the buccal cusp. The lesion appeared pink, was firm on palpation and bled on blunt probing. The surface was covered with an intact mucosa. Radiological examination showed no bone destruction in the maxillary alveolar ridge (Fig 2).

Under local anesthesia, an excision biopsy of the mass was performed. A hematoxylin and eosin stained (HE-stained) section of the biopsy revealed that the tumour consisted of proliferated anaplastic spindle cells. Karyokineses were frequently observed (>5/10 HPF). Necrotic changes could be found in the surface layer (Fig 3a).

Immunohistochemical staining was performed. The markers used were S-100 protein, smooth muscle actin (SMA), myogenic differentiation 1 (MyoD1), cytokeratin AE1–AE3 (AE1/AE3), and peripheral myelin protein 22 (PMP22). The results were as follows (Figs 3b to 3f): the spindle cell component was positive for S-100 and PMP22, but negative for AE1/AE3, SMA, and MyoD1. These findings were consistent with the diagnosis of MPNST.

A month later, the patient was admitted into the Department of Maxillofacial Surgery and a partial maxillectomy was performed. It has been 8 months since the operation and no recurrence has occurred.

¹ Department of Pediatric Dentistry, Peking University School and Hospital of Stomatology, Beijing, P.R. China

Corresponding author: Dr He LIU, Department of Pediatric Dentistry, Peking University School and Hospital of Stomatology, #22 Zhong-guancun Nandajie, Haidian District, Beijing 100081, P.R. China. Tel: 86-10-62179977 ext 2361; Fax: 86-10-62173402; E-mail: heliu69@yahoo.com.cn

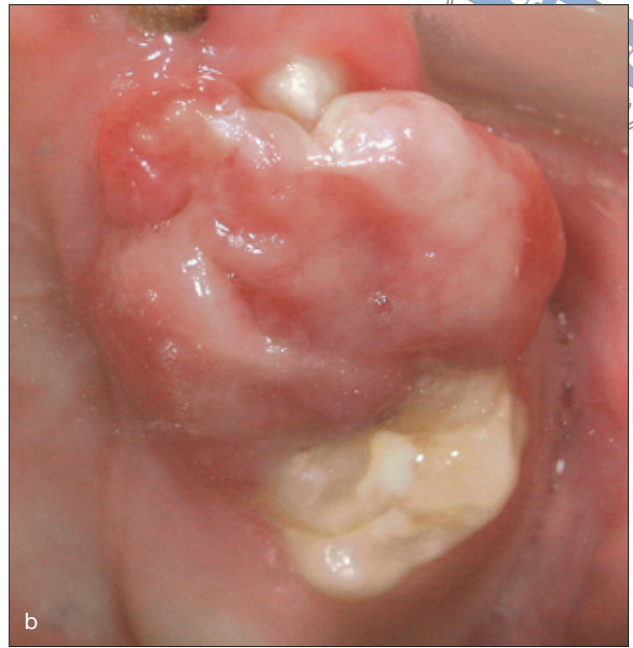
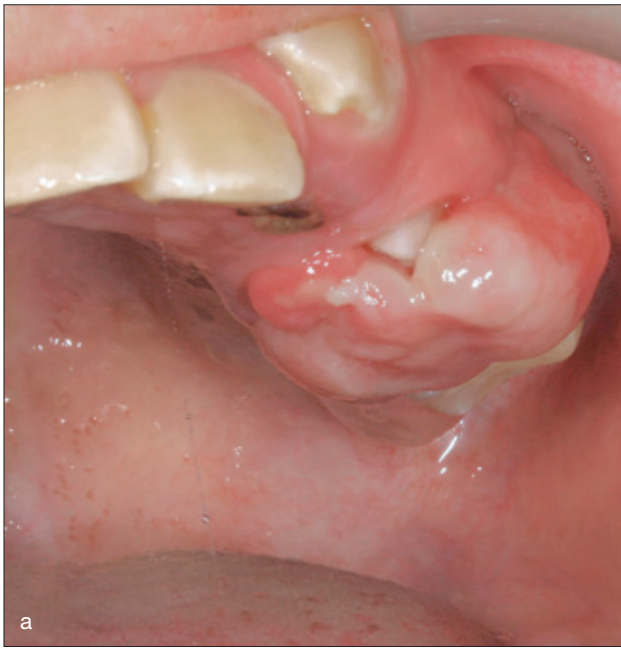

Fig 1 Intraoral image of a 9-year-old girl. A mass attached to the buccal and palatal gingiva of the upper left premolar region (a) and overcrowned part of the first molar and first premolar (b).

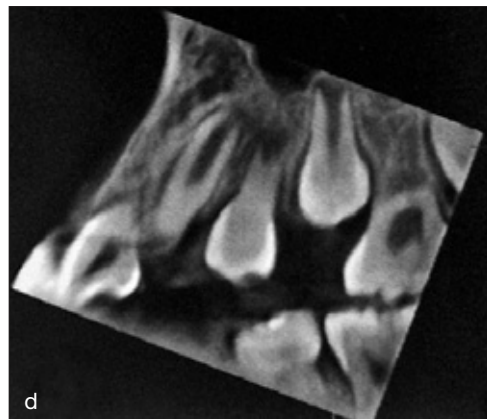
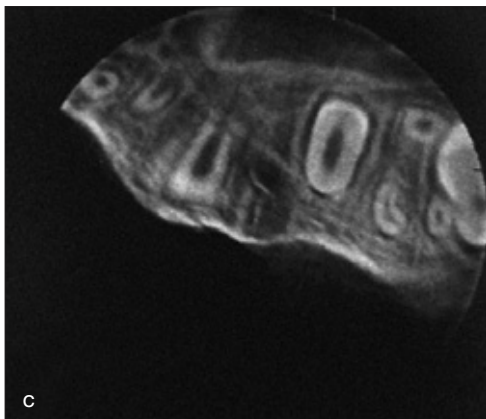
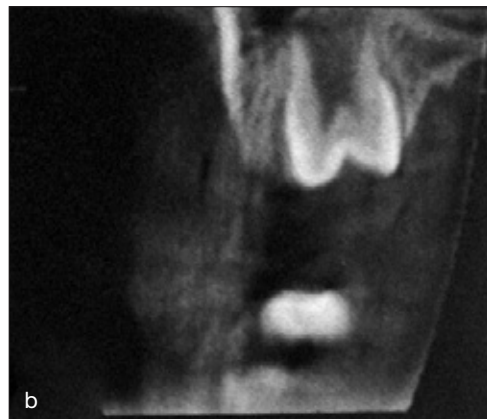
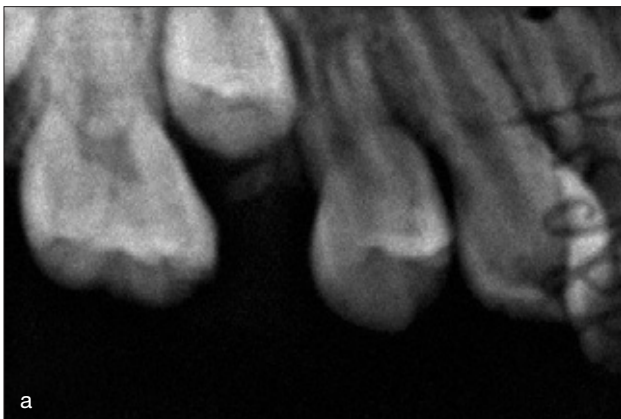


Fig 2 Radiographic examinations showed no destruction of bone in the maxilla: (a) periapical radiograph; (b to d) cone-beam computerised tomography.

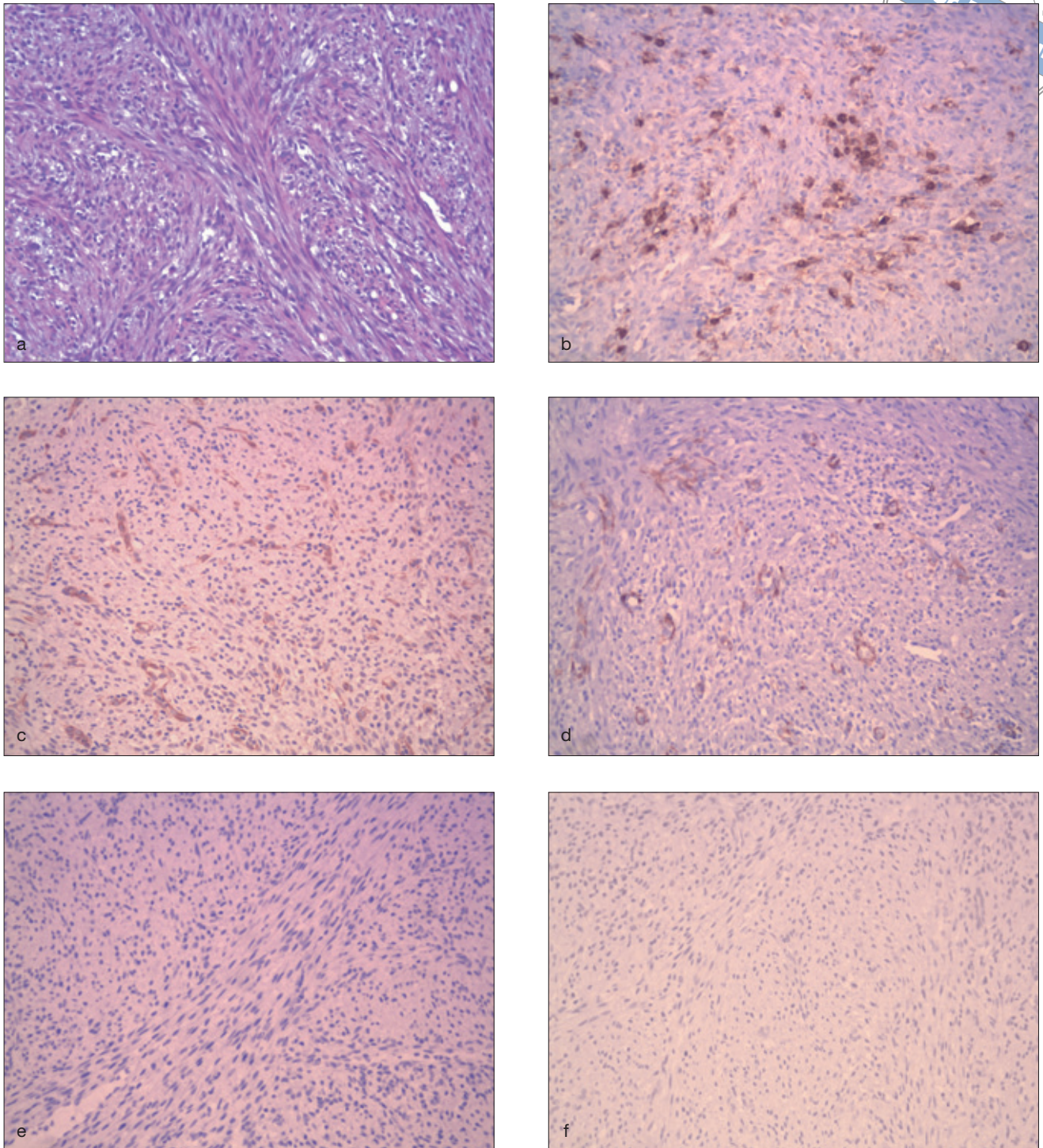


Fig 3 Pathological examinations (20x). (a) HE-stained section showed intersecting fascicles of spindle-shaped cells; (b) S-100 protein immunoreactivity is focally positive; (c) PMP22 immunoreactivity is focally positive; (d) SMA immunoreactivity is negative in tumour cells, but positive in vascular walls; (e) MyoD1 immunoreactivity is negative; (f) AE1/AE3 immunoreactivity is negative.

**Table 1** Application and results of immunohistochemical markers

	Application	Result
S-100 protein	Marker of neuroglia High positive incidence in MPNSTs (strongly or focally)	Focally positive
PMP22	Marker of myelinating Schwann cells	Focally positive
SMA	Marker of smooth muscle tissues	Negative
AE1/AE3	Marker of epithelial cell differentiation	Negative
MyoD1	Marker of muscle cell differentiation	Negative

Discussion

MPNST is clinically difficult to recognise due to the lack of specific manifestations. In this case, a number of diseases were initially considered: epulis, eruptive gingivitis and drug-induced gingival hyperplasia.

Biopsy was performed to attain a definitive diagnosis in this case. Histologically, MPNST is composed of spindle cells, which is similar to other spindle cell tumours. However, the diagnosis can be supported by immunohistochemical staining. The immunohistochemical markers used and the results of staining are summarised in Table 1. The results were consistent with the characteristics of MPNST, thus excluding carcinoma or sarcoma from other tissues.

MPNSTs are associated with poor survival and have a high incidence of local recurrence and distant metastasis. The extent of tumour resection and the achievement of clear surgical margins are the major factors influencing survival. That is why partial maxillectomy was performed in the present case. Disease-free survival and overall survival rates were reported to be approximately 30% and 64% respectively at 5 years for MPNST. The local recurrence rates of MPNST vary from 40% to 65%, while metastatic rates vary from 40% to 68%. Metastases most commonly occur in the lung and liver³. A chest radiograph was taken in the present case; no pulmonary metastasis was seen.

MPNSTs are uncommon in children. Only about 10% of patients with MPNST are younger than 20 years old⁴. In this case, the patient was 9 years old. The age of the patient is a risk factor for survival. Most studies agree that subjects older than 30 years survive longer without recurrence than younger patients³.

Tumour location has been found to be a strong prognostic factor, with those in the thoracic cavity and retroperitoneum having worse outcomes. The most common sites of MPNST in children are upper and lower extremities, head and neck, and trunk. As there have been few reports of MPNST occurring on gingiva⁵, the prognosis of this patient is uncertain.

Gingival hyperplasia due to the stimulation of an erupting tooth is quite common in paediatric dentistry. This case report gives us a warning that asymptomatic gingival hyperplasia should be evaluated carefully to avoid misdiagnosis.

References

1. Grobmyer SR, Reith JD, Shahlaee A, Bush CH, Hochwald SN. Malignant peripheral nerve sheath tumor: molecular pathogenesis and current management considerations. *J Surg Oncol* 2008;97:340–349.
2. Meis JM, Enzinger FM, Martz KL, Neal JA. Malignant peripheral nerve sheath tumors in children. *Am J Surg Pathol* 1992;16:694–707.
3. Rawal A, Yin Q, Roebuck M, Sinopidis C, Kaloqrianitis S, Helliwell TR, Frostick S. Atypical and malignant peripheral nerve-sheath tumors of the brachial plexus: report of three cases and review of the literature. *Microsurgery* 2006;26:80–86.
4. Carli M, Ferrari A, Mattke A, Zanetti I, Casanova M, Bisogno G et al. Pediatric malignant peripheral nerve sheath tumor: The Italian and German Soft Tissue Sarcoma Cooperative Group. *J Clin Oncol* 2005;23:8422–8430.
5. Chao JC, Ho HC, Huang CC, Tzeng JE. Malignant schwannoma of the mandible: a case report. *Auris Nasus Larynx* 2007;34:287–291.