

## Endodontic Treatment of a Five-rooted Maxillary Second Molar: a Case Report

Shu Yu SUN<sup>1</sup>, Jin Cai ZHANG<sup>1</sup>, Zhi Yong ZHANG<sup>1</sup>

*The aim of this case report is to describe a rare case of a five-rooted maxillary second molar that had two separated buccal roots and three separated palatal roots, each containing one independent root canal. The case report demonstrates that anatomical variations in the maxillary second molar should be taken into consideration during endodontic treatment, coupled with application of advanced techniques such as endodontic microscopy and cone-beam computed tomography to increase the ability of clinicians to treat difficult cases.*

**Key words:** anatomical variations, cone-beam computed tomography, maxillary second molar, root canal anatomy, root canal therapy

A successful outcome of non-surgical endodontic therapy in maxillary molars is dependant on the ability of the operator to locate and fill all root canals present in the teeth, since aberrations in root canal anatomy commonly occur. For the maxillary second molar there are six variants that frequently occur, and their frequencies of occurrence are as follows:

- three separate roots and three separate canals (56.9%)
- three separate roots and four canals (two in the mesiobuccal root) (22.7%)
- three roots and canals whose mesiobuccal and distobuccal canals combine to form a common buccal with a separate palatal (9%)
- two separate roots with a single canal in each (6.9%)
- one main root and canal (3.1%)
- four separate roots and four separate canals including two palatal (1.4%)<sup>1</sup>.

However, there are also case reports that have described more anatomical variations, such as three palatal canals, two mesiobuccal and one distobuccal canal<sup>2</sup>, three separate buccal roots (two separate mesiobuccal roots and a distobuccal root)<sup>3-5</sup>, two distinct palatal roots or

with two palatal root canals<sup>6-8</sup>. Such root canal configurations have not been reported in the Chinese population. Although additional roots or canals are rare, knowledge of their occurrence and variations, particularly concerning the location of canal orifices and examining the pulpal floor to treat all canals, is very important for the successful endodontic therapy of the maxillary second molars.

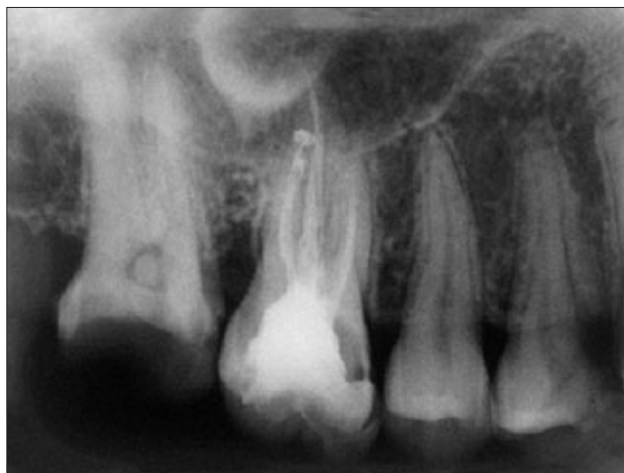The present case report describes a case of successful root canal therapy on a second maxillary molar in a 20-year-old Chinese female patient with five separate roots: three mesial roots and two distal roots arrayed in a buccal-palatal direction respectively. A similar case has not been mentioned in the literature.

### Case report

A 20-year-old Chinese female patient presented with the chief complaint of a toothache in her right maxilla, she complained of pain to cold and hot water for about 1 week. Due to deep decay in the occlusal surface of tooth 17 and positive reactions to heat and cold sensitivity tests, a diagnosis of irreversible pulpitis in tooth 17 was established. Tooth 16 was filled and it was not tender to either percussion and palpation, or to cold test, so it was concluded that it was not the involved tooth. The initial radiograph disclosed the presence of two mesial roots, two distal roots with a normal peri-apex and an indistinct image of the palatal roots (Fig 1). The patient's medical history was non-contributory.

<sup>1</sup> Department of Endodontics, Guangdong Provincial Stomatological Hospital, Southern Medical University, Guangzhou, P.R. China.

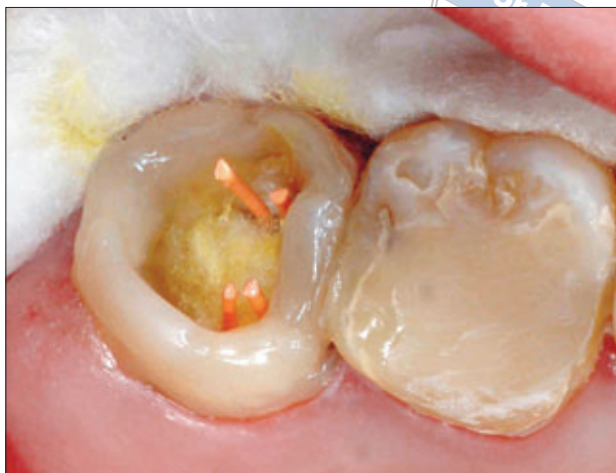**Corresponding author:** Dr Jin Cai ZHANG, Guangdong Provincial Stomatological Hospital, Jiangnan Boulevard S366, Guangzhou 510280, P.R. China. Tel: 86-20-84241308; Fax: 86-20-84433177; Email: jincaizhang-1@hotmail.com



**Fig 1** Preoperative radiograph of the maxillary right molars, the maxillary second molar seemed to have two mesial roots and two distal roots.

Under anaesthesia, the decayed structure in the tooth was removed. The remaining tooth structure was not enough for the clamp retention, so a small amount of light-curing composite resin was placed on the axial surfaces to set the rubber dam clamp (Fig 2). Then the tooth was isolated with rubber dam and access to the pulp chamber was established. The pulp tissue was removed and the chamber was irrigated with a 2.5% sodium hypochlorite (NaOCl) solution. Four root canal orifices were found in the floor, two located buccally and two palatally. After the working length of each canal was estimated by means of an electronic apex locator (ProPex™, Dentsply Maillefer, Ballaigues, Switzerland) and then confirmed by the radiograph, the canals were cleaned and shaped with ProTaper® rotary instruments (Dentsply Maillefer) under copious irrigation (Fig 3). Calcium hydroxide (Ca(OH)<sub>2</sub>) paste was placed into the canals, and the tooth was sealed with temporary filling material (Cavit™ G, 3M ESPE, Neuss, Germany) to prevent coronal leakage.

Ten days after the initial visit, the patient returned for completion of the endodontic treatment. The tooth was asymptomatic, and the four canals were irrigated ultrasonically with 2.5% NaOCl. Before sealing the four canals, a fissure located between the mesiobuccal and mesiopalatal canals was found under an operating microscope (OPMI® PROergo, Carl Zeiss, Germany) (Fig 4). A small pre-curved file (size 0.06 K file, Dentsply Maillefer) was inserted in that region and the instrument was advanced until the working length was achieved, so an extra root canal may occur. An electronic locator was used to verify that it was not a perforation of the chamber floor. The mesiolingual canal that was missed in the previous treatment was found and treated (Fig 5); after

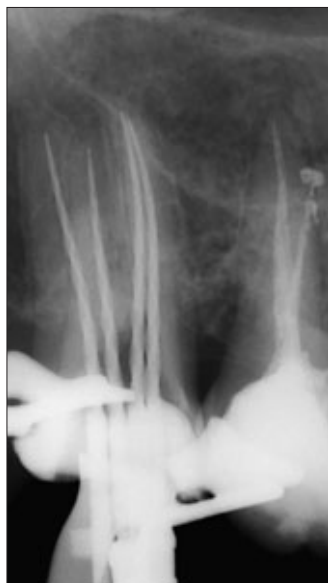

**Fig 2** Composite served as scaffold for setting the rubber dam clamp.

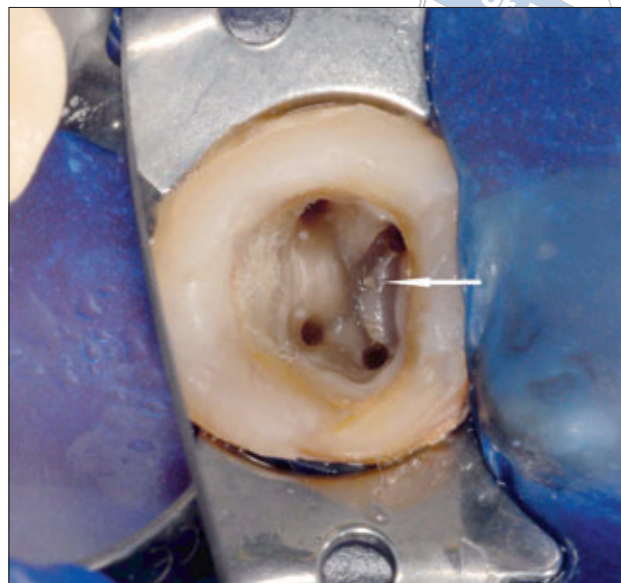
irrigating the canals ultrasonically, the five canals were obturated with gutta-percha and AH Plus® sealer (Dentsply DeTrey, Konstanz, Germany), the amalgam post and core were then immediately placed in the tooth, and the tooth was filled. With the patient's approval, three-dimensional computerised tomography (3DX multi-image micro CT, J. Morita, Osaka, Japan) was conducted to examine the presence of missed roots or untreated canals. The image information showed that the tooth had five separate roots: three mesial roots and two distal roots, two located buccally and three located palatally (Figs 6 and 7). The post-operative radiograph revealed three separate mesial canals and two distal canals (Fig 8). The patient was subsequently referred for further coronal restoration and 10 months later the tooth was clinically asymptomatic and radiographically sound (Fig 9).

## Discussion

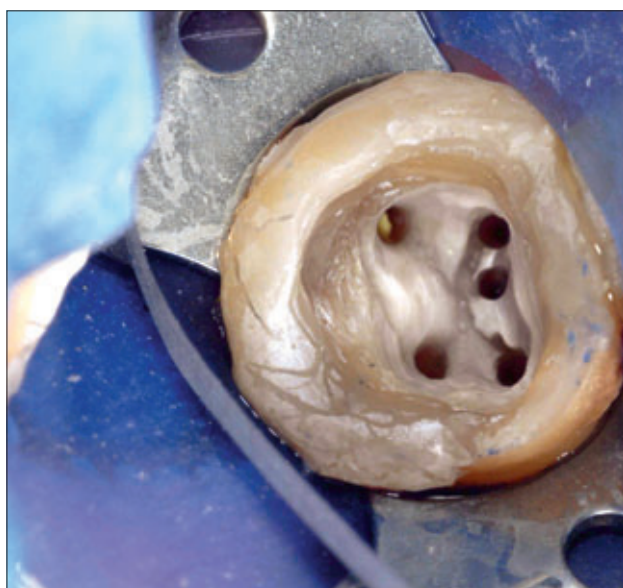
It is well known that the existence of undetected extra roots or root canals is the major reason for treatment failure<sup>9</sup>. The study of the incidence and configuration of roots and canals has been mainly focused on the mesio-buccal root of maxillary first and second molars. There have been few reports about the number of roots in maxillary second molars, and most endodontic texts describe the human maxillary second molar with three roots and three or four root canals. The possibility of three palatal roots and canals in maxillary second molars is quite small, so this article serves to remind clinicians that even though it is not common, an extra root containing an independent root canal may occur. During endodontic treatment procedures, this possibility must be taken into account in the clinical and radiographic evaluation.



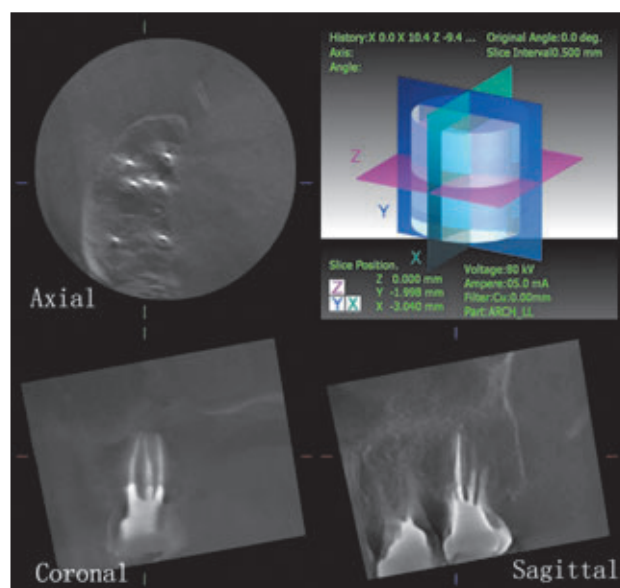
**Fig 3** Master apical files image after cleaning and shaping the four canals, the extra canal was not noted on the radiograph.



**Fig 4** Clinical view of four separate canal orifices of the chamber floor under operating microscope ( $\times 4$ ), note a suspected orifice located buccally to the mesiolingual orifice (arrow).



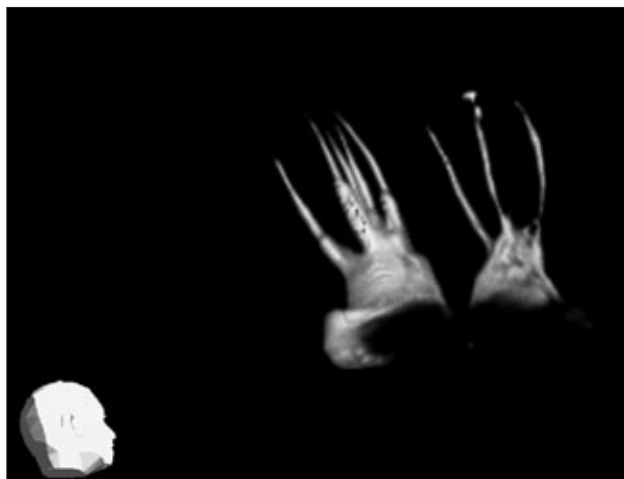
**Fig 5** After preparation of all the canals, three mesial canal orifices and two distal orifices were shown.



**Fig 6** CBCT demonstrates axial, sagittal and coronal two-dimensional slices of the filled mesial roots and canals.

In the present case, the initial radiograph suggested only four roots, two mesial and two distal roots. Indistinct images of palatal roots are presented in preoperative x-ray images, so the clinician must consider the possibility of two or more palatal roots. A broad coronal access will allow the correct localisation of root canals, and a careful inspection of the pulp chamber floor by probing the fissure between the mesiobuccal and mesio-palatal canal is important. The extra root canal was sus-

pected only after the other four canals were treated and microscopy was used to identify the missed orifice, so it is important to probe the pulp floor carefully before sealing the canals to avoid missing canals. The use of the endodontic microscope and the electronic apex locator were helpful for the detection of the missed canal, which seems to agree with Carvalho and Zuolo on the use of the endodontic microscope during the cleaning, shaping and obturation of root canal therapy<sup>10</sup>. Wolcott et al also



**Fig 7** Three-dimensional reconstruction of the roots of tooth 17 and 16 (VoRImage) by using I-Dixel-3DX software (Version 1.68, Morita, Japan).

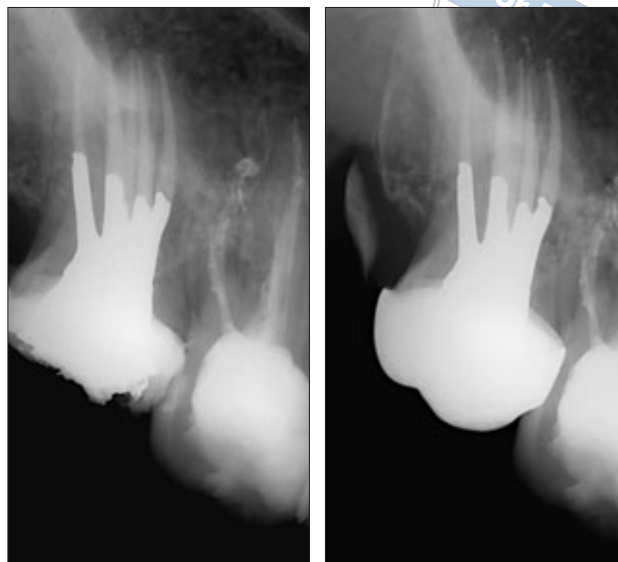
suggested that the use of magnification was essential to ensure the long-term success of endodontic therapy in maxillary molars<sup>11</sup>.

Root canal variations predispose clinicians to inadequate root canal preparation and should be recognised before or during treatment.

The newly developed cone-beam computed tomography (CBCT) technique provides additional clinically relevant undistorted three-dimensional information not attainable by either intra-oral radiography or panoramic radiography. CBCT eliminates the superimposition of surrounding structures and has great potential to become a valuable diagnosis and treatment planning tool in the endodontic practice. In the present case, the diagnosis of the root and its position was made with the use of CBCT, which provides the ability to view images in the proximal and axial planes and makes the identification of root canals virtually guaranteed. CBCT also has application in areas of interest for endodontic therapy such as diagnosis of endodontic pathosis and canal morphology, assessment of pathosis of non-endodontic origin, evaluation of root fractures and trauma, analysis of external and internal root resorption, and pre-surgical planning<sup>12-14</sup>. Thus, the information derived from CBCT is invaluable and leads to better clinical outcomes.

## Conclusion

The present case indicates that it is possible for maxillary second molars to have five roots and five canals, and that root canal systems of the maxillary second molar can have wide variation and complexity.



**Fig 8** Post-operative radiograph showing obturation of the five canals and amalgam posts placed. **Fig 9** Ten month follow-up radiograph showing normal periapical images.

## References

1. Peikoff MD, Christie WH, Fogel HM. The maxillary second molar: variations in the number of roots and canals. *Int Endod J* 1996;29:365-369.
2. Pasternak Júnior B, Teixeira CS, Silva RG, Vansan LP, Sousa Neto MD. Treatment of a second maxillary molar with six canals. *Aust Endod J* 2007;33:42-45.
3. Jafarzadeh H, Javidi M, Zarei M. Endodontic retreatment of a maxillary second molar with three separate buccal roots. *Aust Endod J* 2006; 32:129-132.
4. de Almeida-Gomes F, Maniglia-Ferreira C, dos Santos RA. Two palatal root canals in a maxillary second molar. *Aust Endod J* 2007;33:82-83.
5. Ulusoy OI, Görgül G. Endodontic treatment of a maxillary second molar with 2 palatal roots: a case report. *Oral Surg Oral Med Oral Pathol Oral Radiol Endod* 2007;104:e95-e97.
6. Fahid A, Taintor JF. Maxillary second molar with three buccal roots. *J Endod* 1988;14:181-183.
7. Zmener O, Peirano A. Endodontic therapy in a maxillary second molar with three buccal roots. *J Endod* 1998;24:376-377.
8. Alani AH. Endodontic treatment of bilaterally occurring 4-rooted maxillary second molars: case report. *J Can Dent Assoc* 2003;69:733-735.
9. Ruddle C. Microendodontic analysis of failure: identifying missed canals. *Dent Today* 1997;16:52,54,56-57.
10. de Carvalho MC, Zuolo ML. Orifice locating with a microscope. *J Endod* 2000;26:532-534.
11. Wolcott J, Ishley D, Kennedy W, Johnson S, Minnich S. Clinical investigation of second mesiobuccal canals in endodontically treated and retreated maxillary molars. *J Endod* 2002;28:477-479.
12. Lofthag-Hansen S, Huuonen S, Gröndahl K, Gröndahl HG. Limited cone-beam CT and intraoral radiography for the diagnosis of periapical pathology. *Oral Surg Oral Med Oral Pathol Oral Radiol Endod* 2007;103:114-119.
13. Nakata K, Naitoh M, Izumi M, Inamoto K, Ariji E, Nakamura H. Effectiveness of dental computed tomography in diagnostic imaging of periradicular lesion of each root of a multirooted tooth: a case report. *J Endod* 2006;32:583-587.
14. Cotton TP, Geisler TM, Holden DT, Schwartz SA, Schindler WG. Endodontic applications of cone-beam volumetric tomography. *J Endod* 2007;33:1121-1132.