

# A Rare Case of Two Accessory Maxillae with Bilateral Tessier 7 Clefts

Shuang YIN<sup>1</sup>, Ruo Han MA<sup>1</sup>, Jin LI<sup>2</sup>, Lian MA<sup>2</sup>, Shu Ming LIU<sup>2</sup>, Gang LI<sup>1</sup>

*A 10-year-old Chinese girl with two accessory maxillae and bilateral Tessier no. 7 clefts is presented. Radiographic examination showed two accessory maxillae, each containing 5 or 6 supernumerary permanent teeth. The two accessory maxillae extended from the inside of the zygomatic arch to the maxillary tuberosity symmetrically. Duplication of the maxilla is always associated with Amniotic Band Syndrome (ABS), but this case may be a distinct syndrome representing an under-recognised phenotype with bilateral maxillae duplication and Tessier no. 7 clefts.*

**Key words:** *accessory maxilla, maxillary duplication, bilateral Tessier 7 cleft*  
*Chin J Dent Res 2017;20(1):53–58; doi: 10.3290/j.cjdr.a37742*

**B**ilateral duplication of the maxilla associated with facial clefts is very rare, and presents some of the most challenging diagnostic problems<sup>1-5</sup>. Although most of the cases of maxillary duplication are associated with Amniotic Band Syndrome (ABS), some special cases may show as an unbeknown distinct syndrome.

In this report we present a girl with two accessory maxillae and bilateral Tessier 7 clefts.

## Case report

A 10-year-old Chinese girl with the chief complaint of speaking with unclear enunciation presented to Peking University School and Hospital of Stomatology. The patient was born with a recessive cleft palate and bilat-

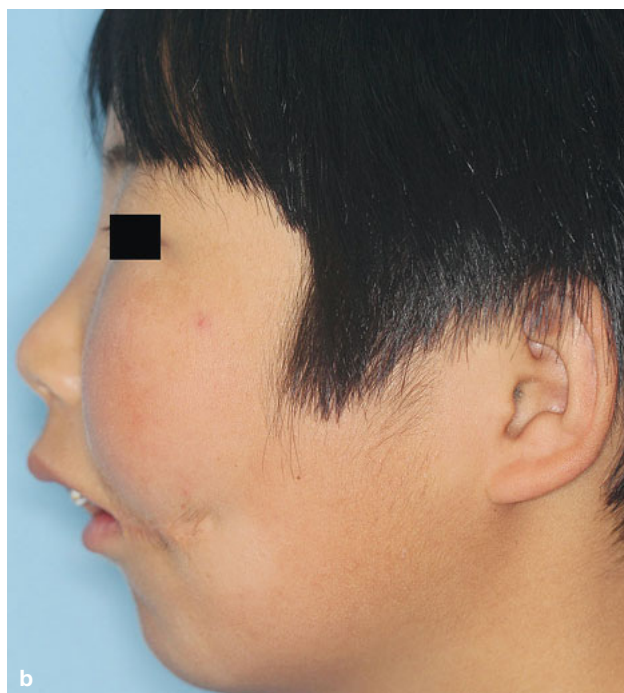
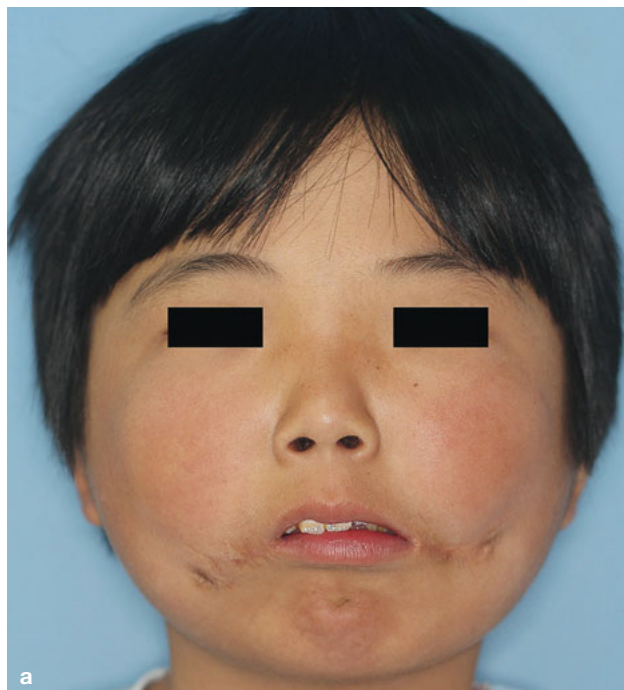eral facial horizontal cleft and was thereby diagnosed as bilateral Tessier 7 cleft together with recessive cleft palate. At 8 months old the bilateral facial horizontal cleft was repaired, but there was no operation on her cleft palate. At the age of 1 her enunciation appeared unclear. She had no mental problems and any other diagnosed medical conditions or family history of similar deformities, while her mother had developed a cold in the third month of her pregnancy and had taken medicine.

Clinical examination showed excessive exposure of the upper anterior teeth, the asymmetric angulus oris and scars at the bilateral commissure (Fig 1). In profile, the patient exhibited severe prominent maxilla and relative retrogenia, as well as micrognathia (Fig 1). Intraoral examination showed that she was in the mixed dentition stage, with poor oral hygiene. It was notable that there were three maxillae in her mouth, with one basic normal maxilla in the middle and two accessory maxillae with double teeth on each side. As the teeth in the accessory maxillae made contact with the mandibular posterior teeth before the normal teeth, there was anterior open bite. Meanwhile, she had a high-arched palate with basic normal soft palate (Fig 2). When she said the “i” note, the soft palate’s elevation movement was poor (Fig 3). Furthermore, she had hypernasality, nasal emission and compensatory articulation in her pronunciation. There were no other anomalies in her general check-up.

1 Department of Oral and Maxillofacial Radiology, Peking University School and Hospital of Stomatology, National Engineering Laboratory for Digital and Material Technology of Stomatology, Beijing Key Laboratory of Digital Stomatology, Beijing, P.R. China.

2 Department of Oral and Maxillofacial Surgery, Peking University School and Hospital of Stomatology, National Engineering Laboratory for Digital and Material Technology of Stomatology, Beijing Key Laboratory of Digital Stomatology, Beijing, P.R. China.

**Corresponding author:** Dr Gang LI, Department of Oral and Maxillofacial Radiology, Peking University School and Hospital of Stomatology, #22 Zhongguancun South Street, Hai Dian District, Beijing 100081, P.R. China. Tel: 86-10-82195328; Fax: 86-10-82195328. Email: kqgang@bjmu.edu.cn



**Fig 1** (a) Frontal and (b) profile view of the patient. The frontal view showed excessive exposure of the upper anterior teeth, the asymmetric angulus oris and scars at the bilateral commissure. The profile view showed severe prominent maxilla, relative retrogenia and micrognathia.

Panoramic radiograph showed two dysplastic bony prominences locating posterior to the maxillary tuberosity bilaterally, which are called accessory maxillae. The denture is in mixed dentition, and one of the incisors in the mandible is missing. Meanwhile, in the two accessory maxillae, there are 5 or 6 supernumerary permanent teeth at different stages of development (Fig 4). Three-dimensional reconstructed computed tomography (CT) showed that the two dysplastic bony prominences extended from the inside of the zygomatic arch to the maxillary tuberosity. There was a gap between the maxillary tuberosity and the accessory maxilla at each side. No sign of other bone pathology was observed (Fig 5).

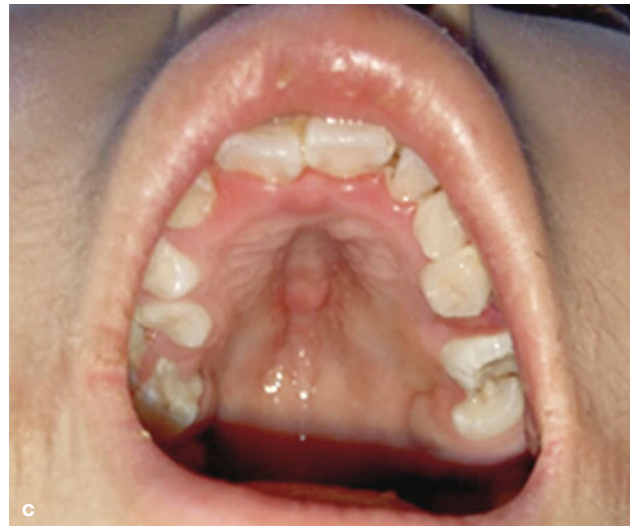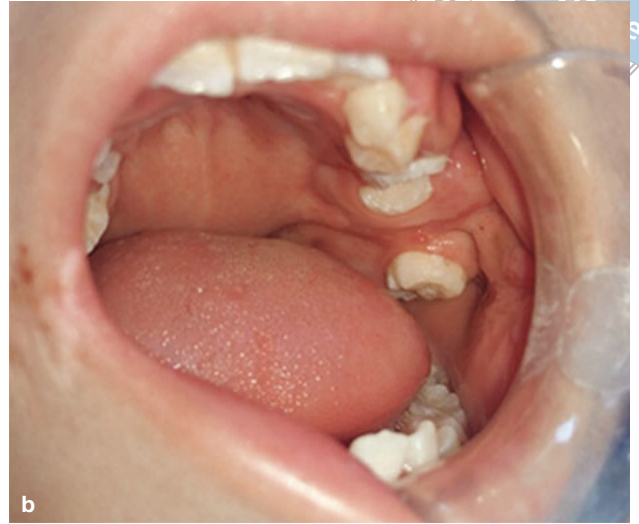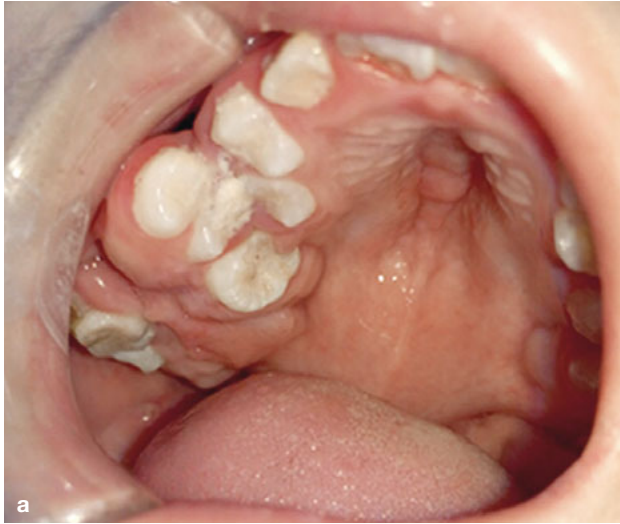The possible diagnosis was 1) maxillary duplication along with the Tessier's 7 Cleft and 2) dubious ABS. An operation was done to remove all the supernumerary teeth and part of the bone in the two accessory maxillae (Fig 6).

## Discussion

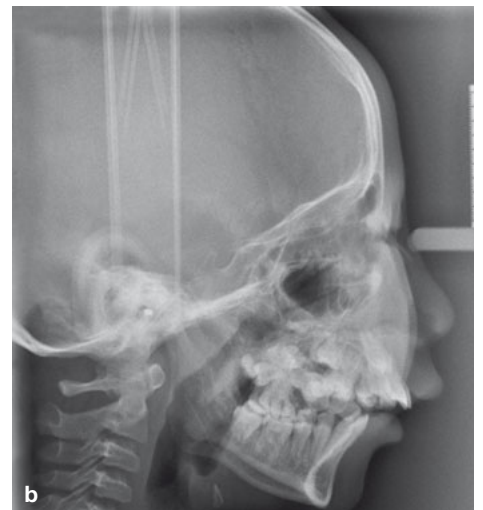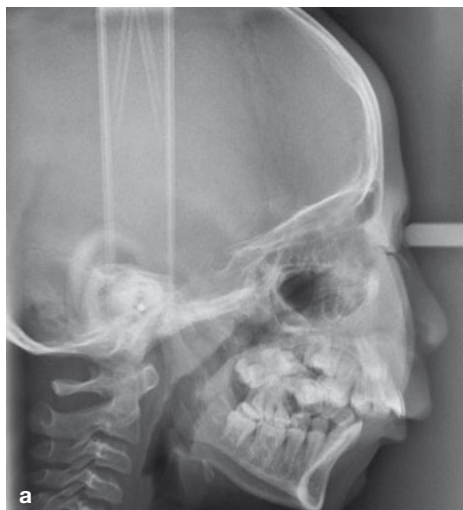Maxillary duplication is a very rare phenomenon, and a review of the literature disclosed only a few cases<sup>1-13</sup>. It is even more rare that bilateral duplication of the maxilla is associated with facial clefts<sup>1-5</sup>.

This patient showed a set of craniofacial anomalies. The following important features were observed: Firstly, dysplastic bony prominences arising from the inferior border of each zygoma and she had a gap to the tuberosity on each side. Secondly, the morphology of the middle maxilla was normal and there was no loss of any teeth or tooth buds. Thirdly, the morphology of the permanent teeth in both sides of the accessory maxilla was normal. Otherwise, no any other developmental anomaly was observed.

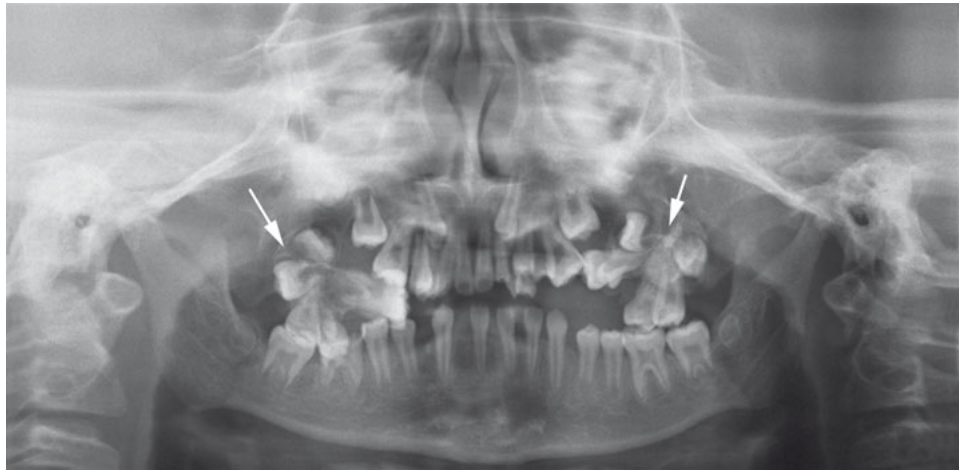
The diagnosis of maxillary duplication is always associated with ABS, which is a sporadic condition and occurs in approximately 1 in 15,000 births<sup>14</sup>. Multiple anomalies are presented in 77% of cases<sup>15</sup>. ABS is an uncommon congenital disorder without any genetic or hereditary disposition. Many theories concerning the pathogenesis of ABS have been proposed, but none is definite. It has been widely accepted that anomalies are caused by the rupture of amnion. The foetus subsequently becomes adherent to, intertwined in, and tethered by fibrous mesodermic bands<sup>16</sup>. These variations may appear at different stages during pregnancy, so there are various anomaly appearances and no two cases are completely alike. The most common congenital anomalies are syndactyly, clubfoot, and/or present with severe craniofacial and visceral deformities<sup>17</sup>.



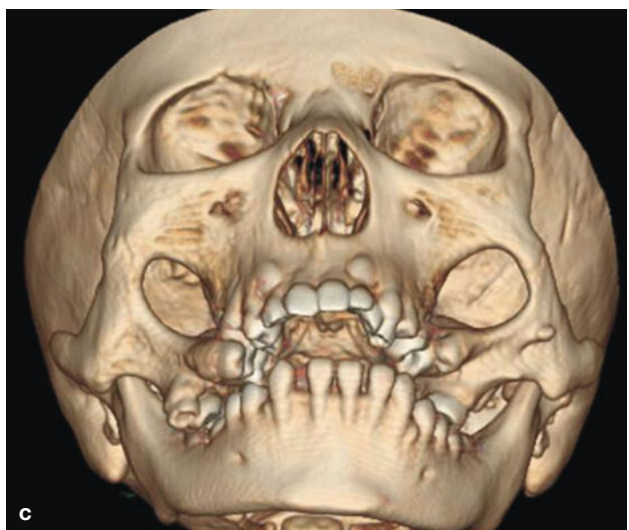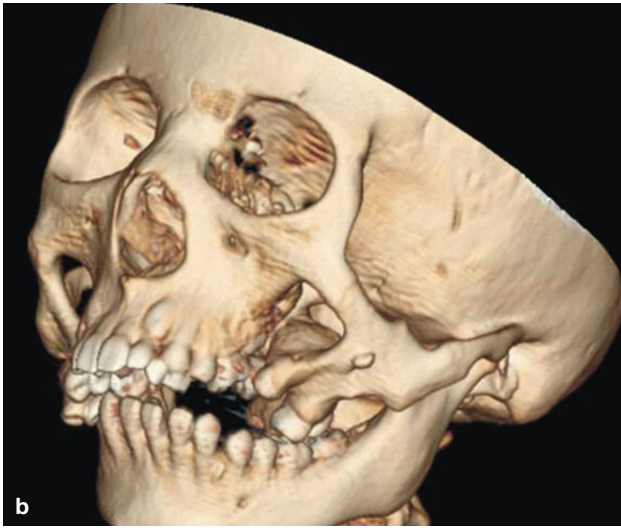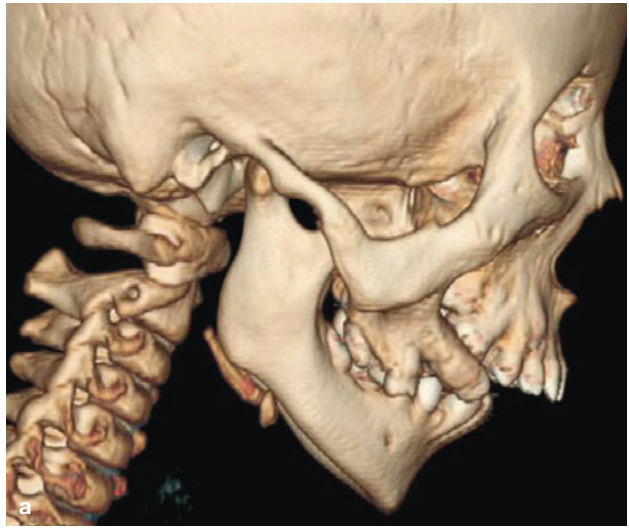**Fig 2** Oral view of the patient. (a) The right part of dental arch. (b) The left part of dental arch. (c) High-arched palate.



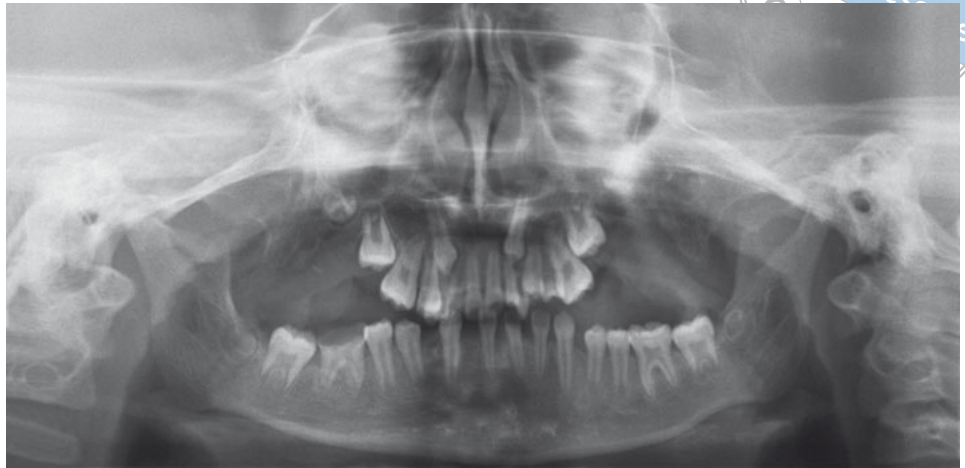**Fig 3** (a) Lateral projection of the cranium. (b) Lateral projection of the cranium when she said the “i” note. The soft palate’s elevation movement was poor.



**Fig 4** Panoramic radiograph of the patient. There were two dysplastic bony prominences locating posterior to the maxillary tuberosity bilaterally.



**Fig 5** 3D image of the patient. Note the dysplastic bony prominences extending from the inside of the zygomatic arch to the maxillary tuberosity.



**Fig 6** Panoramic radiograph after the surgery. The supernumerary teeth and part of the bone in the two accessory maxillae were removed.

Swallowing of amniotic bands may also produce bizarre orofacial clefts, distortions and disruptions of craniofacial structures<sup>18</sup>. The craniofacial lesions are frequently asymmetrical and do not conform to the anatomy of the normal facial clefts. They can include cleft lip, cleft palate, microphthalmia, and abnormal skull calcification, as well as asymmetric anencephaly, encephalocele, and decapitation<sup>19</sup>.

For a postpartum diagnosis of ABS, the patient should have no history of virus or toxoplasma infection during pregnancy, no medication or intrauterine surgery history during pregnancy, and the chromosome of the foetus is normal. There should be no familial history of foetus malformation. The autopsy or clinical examination of the newborn should confirm the main characteristics of ultrasound diagnosis, and amniotic membrane can be seen attached to different parts of a baby<sup>20</sup>. Also, the craniofacial lesions are rarely symmetrical.

In this case, however, there are two accessory maxillae behind the normal maxilla symmetrically. This phenomenon rules out the diagnosis of ABS. Meanwhile, the prenatal ultrasound examination did not reveal any abnormalities, and her mother took some medicine at the third month of pregnancy, both of which oppose the diagnosis of ABS.

Duplications of the maxilla are frequently accompanied by the cleft lip and palate, multiple uvulae, or other craniofacial anomalies<sup>9,21,22</sup>. Tessier 7 cleft is the most common. Although Cheung et al presented a case which was not associated with any other anomalies, the authors still suggested that bilateral accessory maxilla along with other anomalies, such as facial cleft, may be a distinct syndrome<sup>12</sup>.

Maxilla and mandible develop from the first branchial arch. It is well known that radiation, viruses and parasitic infections, metabolic imbalance and some drugs or chemicals are the exogenous factors of the development of cranial and maxillofacial deformities. This may be one of the causes for the present case since her mother had taken some medicine in her third month of pregnancy.

### Conflicts of interest

The authors reported no conflicts of interest related to this study.

### Author contribution

Dr Shuang YIN designed and prepared the manuscript; Dr Ruo Han MA, Dr Jin LI, Dr Lian MA and Dr Shu Ming LIU collected data and the patient information; Dr Gang LI directed and revised the manuscript.

(Received Sep 29, 2016; accepted Oct 31, 2016)

### References

1. Tharanon W, Ellis E 3rd, Sinn DP. A case of maxillary and zygomatic duplication. *J Oral Maxillofac Surg* 1998;56:770–774.
2. Borzabadi-Farahani A, Yen SL, Yamashita DD, Sanchez-Lara PA. Bilateral maxillary duplication: case report and literature review. *Oral Surg Oral Med Oral Pathol Oral Radiol* 2012;113:e29–32.
3. Cheung LK, Samman N, Tideman H. Bilateral transverse facial clefts and accessory maxillae--variant or separate entity? *J Craniomaxillofac Surg* 1993;21:163–167.
4. Chauhan DS, Guruprasad Y. Bilateral Tessier's 7 Cleft with Maxillary Duplication. *J Maxillofac Oral Surg* 2015;14:108–112.



5. Borzabadi-Farahani A, Yen SL, Francis C, Lara-Sanchez PA, Ham-moudeh J. A rare case of accessory maxilla and bilateral Tessier no. 7 clefts, a 10-year follow-up. *J Craniomaxillofac Surg*. 2013;41:527–531.
6. Stoneman DW. Congenital facial fistula with formation of accessory bone and teeth. Report of a case. *Oral Surg Oral Med Oral Pathol* 1978;45:150–154.
7. Ryu SY, Oh HK, Kim GJ, Yun YS. Accessory jaw bone: report of a case. *J Oral Maxillofac Surg* 1993;51:1146–1149.
8. Cameron AC, McKellar GM, Widmer RP. A case of neurocristopathy that manifests facial clefting and maxillary duplication. *Oral Surg Oral Med Oral Pathol* 1993;75:338–342.
9. Jian XC, Chen XQ, Hunan C. Neurocristopathy that manifests right facial cleft and right maxillary duplication. *Oral Surg Oral Med Oral Pathol Oral Radiol Endod* 1995;79:546–550.
10. DeGurse K, Chung H, Pharoah M. Facial dimple with accessory bone and teeth. *Dentomaxillofac Radiol* 1995;24:135–138.
11. Sjamsudin J, David D, Singh GD. An Indonesian child with orofacial duplication and neurocristopathy anomalies: case report. *J Craniomaxillofac Surg* 2001;29:195–197.
12. Kainulainen VT, Sándor GK, Stoneman DW. Management of a patient with an accessory maxilla and congenital facial fistula. *J Can Dent Assoc* 2005;71:161–163.
13. Morita K, Iwasa T, Imaizumi F, Negishi A, Omura K. A case of maxillary duplication with a soft palate reconstruction using a forearm flap. *Int J Oral Maxillofac Surg* 2008;37:862–865.
14. Seeds JW, Cefalo RC, Herbert WN. Amniotic band syndrome. *Am J Obstet Gynecol* 1982;144:243–248.
15. Baker CJ, Rudolph AJ. Congenital ring constrictions and intrauterine amputations. *Am J Dis Child* 1971;121:393–400.
16. Benacerraf BR. *Ultrasound of fetal syndromes*. Philadelphia: Churchill Livingstone, 1998:239–243.
17. Levy HL, Lobbregt D, Platt LD, Benacerraf BR. Fetal ultrasonography in maternal PKU. *Prenat Diagn* 1996;16:599–604.
18. Swinburne LM. Spontaneous intrauterine decapitation. *Arch Dis Child* 1967;42:636–641.
19. Muraskas JK, McDonnell JF, Chudik RJ, Salyer KE, Glynn L. Amniotic band syndrome with significant orofacial clefts and disruptions and distortions of craniofacial structures. *J Pediatr Surg* 2003;38:635–638.
20. Li L, Huang GF, Huang Z, Lu QS. Amniotic band syndrome deformity related factors, diagnosis, and treatment results. [In Chinese] *Zhong Guo You Sheng Yu Yi Chuan Za Zhi (Chinese Journal of Birth Health & Heredity)* 2013;21:82–83. 243.
21. Fearon JA, Mulliken JB. Midfacial duplication: a rare malformation sequence. *Plast Reconstr Surg* 1987;79:260–264.
22. Soneji B. Duplication of the mandibular primary dentition in orofacial-digital syndrome type IV. *Cleft Palate Craniofac J* 2010;47:259–263.